

Recent Advances in Basic and Clinical Studies of Glomerular Basement Membrane (GBM)

Shinichi NISHI and Masaaki ARAKAWA

Department of Internal Medicine II, Niigata University School of Medicine, Asahimachi 1, Niigata 951, Japan

Received January 29, 1993

Summary. Recent studies have revealed highly differentiated structures and functions of glomerular basement membrane (GBM). The most specific feature of the GBM is a three-layer structure, i.e. a lamina densa and two laminae rarae. The GBM consists of various components, such as type IV collagen, laminin and proteoglycans, in forming its three-dimensional network structure. This structure is thought to result from a self-assembling of each component and binding each other. The subclasses of the components have been differentiated and their distributions have been proved to be heterogeneous with the GBM. These structural characteristics are supposed to be related to the function of the GBM as a sieving membrane and as a base for cellular attachment.

The mechanism of pathological damage to the structure and function of the GBM has been elucidated in various renal diseases with advances in the basic studies on the GBM. Matrix metalloproteinase (MMP) is considered to be important in GBM injuries of IgA nephropathy. Glycosylation of GBM components is suggested to be one of the causes of thickening of the GBM. A genetic mutation in $\alpha 5(\text{IV})$ chain of type IV collagen has been confirmed in Alport's syndrome.

I. Introduction

Basement membranes possess multiple functions as boundaries between the cells and matrix. Cellular differentiation, proliferation and migration are promoted or guided along them. Molecular substances are selectively filtered through the basement membranes. The properties of basement membranes vary depending on differences among the tissues.¹⁻³⁾ Among basement membranes, the glomerular basement membrane (GBM) is characterized by two features. The first of these is a unique trilamellar structure consisting of a lamina densa and two laminae rarae, being sandwiched between the epithelial and endothelial

cells. Most basement membranes adhere to either the epithelial or endothelial cells and consist of only two layers, a lamina densa and a lamina rara. The second characteristic of the GBM is its specialized ability to generate urine as a highly selective filtrating barrier. In order to keep this selectivity the GBM employs two types of properties as functional barriers, i.e. a charge barrier and a size barrier.

In the latter part of this paper, we summarize recent advances in investigations on the pathological changes of the GBM in four kinds of renal diseases.

II. Basic Studies of GBM

1) Biochemical components of GBM

A number of papers on the biochemical components of the GBM have been published in the past few years. Collagen type IV,^{4,5)} laminin,^{6,7)} proteoglycans,^{8,9)} fibronectin,^{7,10)} nidogen/entactin,¹¹⁾ and amyloid P¹²⁾ have been proved as its components using either immunohistochemical or biochemical methods or both. Recently molecular subclasses of those components, such as collagen type IV, laminin and proteoglycans, have been found. Their heterogeneous distribution in the GBM or in the renal glomerulus have also been reported. Although the biological significances of this heterogeneous distribution have not been proved yet, it is suspected to be related with the highly developed functions of the GBM.

Type IV collagen

Type IV collagen (MW 550kD) is a major component of basement membranes, comprising approximately 50% or more of the total protein volume. In most basement membranes, type IV collagen is a ubiquitous component composed of three polypeptides of

Table 1. Heterogeneous distribution of α chains of type IV collagen in the kidney

	$\alpha 1$	$\alpha 2$	$\alpha 3$	$\alpha 4$	$\alpha 5$
GBM	(+)	(+)	(+)	(+)	(+)
Mesangium	(+)	(+)	(-)	(-)	(-)
Bowman's capsule	(+)	(+)	(+)	(+)	(+)
Tubular BM	(+)	(+)	(+)	(+)	(+)
Vascular BM	(+)	(+)	(-)	(-)	(-)

GBM: glomerular basement membrane
 BM: basement membrane

two different α chains, [$\alpha 1(IV)$]₂ and $\alpha 2(IV)$ assembling into a triple helix.¹³⁾ Recently other α chains, $\alpha 3(IV)$, $\alpha 4(IV)$ and $\alpha 5(IV)$, have also been found in the GBM.¹⁴⁻¹⁶⁾ These α chains are distributed heterogeneously in the GBM: $\alpha 1(IV)$ and $\alpha 2(IV)$ are mainly located on the subendothelial side of the GBM; and $\alpha 3(IV)$ and $\alpha 4(IV)$ chiefly in the lamina densa of the central portion of the GBM. Although the former, classical types, are abundantly recognized in the mesangial matrix, the latter, novel ones are not present there. Among the five subclasses, the expression of $\alpha 5(IV)$ is restricted only to the GBM.¹⁶⁾

A heterogeneous distribution of the substances mentioned above also appears in other renal basement membranes as summarized in Table 1.

Laminin

Laminin (MW 900,000) is a common component of systemic basement membranes. Immunohistochemically, it is recognized both in the lamina densa and rarae

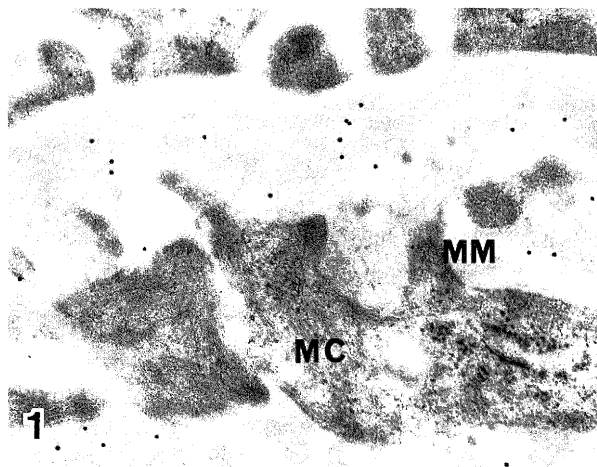


Fig. 1. The localization of laminin by immunogold labeling method. Laminin is recognized both in rat GBM and the mesangial matrix. MC: mesangial cell, MM: mesangial matrix $\times 20,000$

(Fig. 1).¹⁷⁾ The established molecule consisting of three chains, A, B1 and B2 chains, shows a cross-like shape which has one long arm and three short arms. In the developing mesenchym, only B chains are expressed in an earlier stage of development. The A chains appear at a later stage when the epithelial cells accomplish polarization on basement membranes.¹⁸⁾ A heterogeneous distribution of these subunit chains has been reported in the renal glomerulus, too. A monoclonal antibody binding to the long arm of laminin A and B chains showed immunoreactivity to both GBM and mesangial matrix. Another monoclonal antibody binding to the short arms of the B chain revealed immunoreactivity only to the mesangial matrix.¹⁹⁾ The A and B chains of laminin have distinct abilities to bind cells or the matrix components. As the A chain has been known to be important for the attachment of epithelial cells,¹⁸⁾ its heterogeneous distribution is suggested to reflect an important functional polarity of the GBM.

Proteoglycans

Proteoglycan is a large molecule consisting of a core protein and many repeating disaccharide chains, known as glycosaminoglycans (GAG) chains.²⁰⁾ There are various kinds of molecules depending on the sorts of GAGs. In the GBM, heparan sulfate proteoglycan (HSPG) is the most predominant substance among these. Additionally, small amounts of chondroitin sulfate proteoglycan (CSPG), small molecule chondroitin sulfate-dermatan sulfate proteoglycans and hyaluronic acid have also been found.^{21,22)} Basement membranes have two types of HSPG molecules: a low density proteoglycan (LDPG) (MW 650kD) and a high density proteoglycan (HDPG) (MW 130kD).³⁾ LDPG has a large core protein with three long heparan sulfate chains, and HDPG has a small core protein with four heparan sulfate chains. The GBM reveals a heterogeneous distribution of HSPG. Antibodies against HSPG purified from EHS tumors are known to be bound equally to both lamina densa and rara of the GBM. Antibodies reacting specifically to a core protein of renal HSPG, on the other hand, are bound to only the lamina rara of the GBM.²³⁾ Antibodies against a core protein of HSPG derived from PYS-2 cells are bound mainly to the lamina rara and foot process soles. With heparitinase treatment reactivities of the lamina rara disappeared, while those of the foot process soles remained.²⁴⁾ Proteoglycans have various biological roles such as those as ligands of cell binding, as strong sources of negative charges and as the skeletons of matrix structures. Their functional availabilities vary depending on the sorts of proteoglycans or

GAGs. The heterogeneous distribution of proteoglycans are believed to be associated with the functional differentiation of the GBM, though our knowledge concerning this point is still limited.

Entactin

Entactin is a sulfated glycoprotein (MW 150 kD) which was first purified from extracellular matrix secreted by cultured endodermal carcinoma cells. Nidogen is another glycoprotein purified from mouse EHS sarcoma. The cDNA sequences of these two molecules have been cloned and have been identified with each other.^{25,26} Immunohistochemically, entactin/nidogen is observed in the GBM and mesangium. An intensive reactivity is recognized in the outer aspect of the GBM by the immunohistochemical method.²⁷

Other components

Fibronectin and amyloid P have been known to be contained as constitutional components of the GBM. These two substances are found in both plasma and tissues. It is controversial whether plasma molecules or intrinsic tissue molecules are detected in the GBM. In general, fibronectin works for the mechanism of cell attachment, and amyloid P has a calcium binding function and an affinity to HSPG.^{1,2}

2) Biosynthesis and turnover of GBM

Transmission electron microscopy shows lamina densa existing between two layers of the laminae rara (Fig. 3). This unique feature reflects the specific development of the GBM. In the early stage of glomerulogenesis the formation of the GBM is thought to begin by the fusion of two basement membranes produced by visceral epithelial cells (podocytes) and capillary endothelial cells.^{28,29} Recent studies have also clarified the mechanism of further elongation of the GBM. Laminin newly synthesized by podocytes is first pooled under the pockets of foot processes. Subsequently, the pooled laminin is transported into the already existing GBM by splicing.^{30,31} The intracellular organs involved in molecular synthesis, such as the endoplasmic reticulum and Golgi apparatus, are well developed in the podocytes. In contrast, these organs in capillary endothelial cells are poorly developed. Thus, the major providing source of the GBM components seems to be podocytes.

Concerning the biochemical turnover of the GBM, a few data have been reported. The half life of collagen in rat GBM was estimated to be more than 100 days.³² In the study of the GBM labeling with anti-laminin antibodies, these antibodies remained in the

GBM at least for several months.³³

3) Three-dimensional structure

The molecules of the various components of the GBM are capable of self assembly and exhibit binding interactions among each other. A molecule of type IV collagen consists of three α chains to form a triple helix structure with a length of 400 nm. There are two non-collagenous domains (NC domains) at both ends: the NC1 domain in the C terminus, and the NC2 in the N terminus. The NC2 domain and a part of the N terminus of the triple helix (approximately 40 nm) are distinguished as a 7S domain with cross linking ability. Four molecules are assembled via stable interactions of the 7S domains. The NC1 domains also possess a binding ability, so that head-to-head formation is constructed by two molecules. The result of this self-assembling is a polygonal network is accomplished, which is believed to form a basic backbone structure of the GBM.³ It is likely that other components bind this backbone structure complexly. These interactions of the GBM components result in a three dimensional network structure.

Several kinds of histological techniques have been used for visualization of concrete network structures. In conventional transmission electron microscopy, a few kinds of microfibrils have been demonstrated in the GBM.¹⁰ A GBM treated with proteolytic processes has shown a three-dimensional network structure consisting of 3-8 nm microfibrils. In this method, larger microfibrils of 7-8 nm were observed on the subepithelial side, with smaller ones of 3-4 nm favoring the subendothelial side of the GBM.³⁴ Recently a quick-freezing and deep-etching method has obtained the high-resolitional appearance of the three-dimensional network structure of the GBM.^{35,36} The lamina densa of the GBM shows small pores of 16 ± 7 nm, in radii composed of microfibrils of 6-10 nm thickness. In spite of certain varying results presumably arising from differences in histological methodologies, they all have confirmed the occurrence of a three-dimensional network structure in the GBM.

4) Function of GBM

Charge barrier

It is well known that the GBM is a barrier bearing highly negative charges. The sources of the negative charges are sulfate and carboxyl groups contained in the GBM. The sulfate bases are contained in GAG chains of HSPG or CSPG. The carboxyl bases are seen not only in the GAG chains but also in type IV

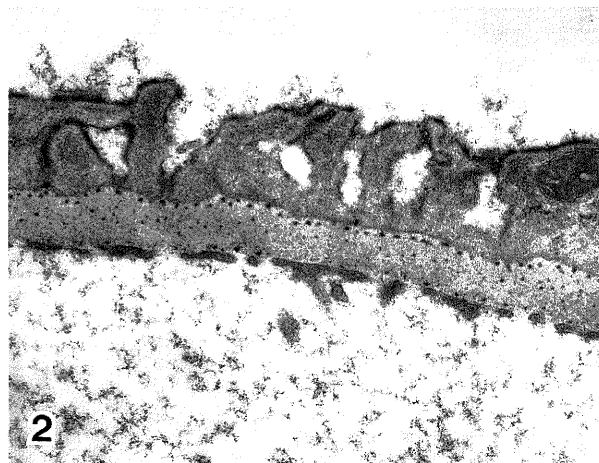


Fig. 2. The detection of negatively charged sites by a cationic probe, polyethyleneimine. Positive reactions are chiefly observed in lamina rara externa of rat GBM. $\times 15,000$

collagen and other non-collagenous components. Among them, the component most significantly contributing to the negative charge is believed to be HSPG, because heparitinase treatment has most effectively reduced the anionic charges.²¹⁾ Various cationic probes, such as alcian blue, colloidal iron, polyethyleneimine, ruthenium red and cationic ferritin, have been used as markers for detecting the anionic sites in the GBM (Fig. 2). The most striking reactions have been observed in the lamina rara externa.³⁷⁾ These probes are usually applied during perfusion or immersion before tissue embedding. In contrast, cationic colloidal gold is used in a post-embedding method to detect anionic sites.³⁸⁾ The reactions of cationic colloidal gold were reduced by hyaluronidase, but not by heparitinase. Hyaluronic acid contains only carboxyl and no sulfate groups. A polycation, hexadimethrine (HDM), is also known to specifically react to the anionic sites of carboxyl groups. This binding reaction to the GBM has been shown to be reduced by sialidase, hyaluronidase and chondroitinase but not by heparitinase.³⁹⁾ These data indicate that controversial problems remain in identifying the component contributing most as an anionic source of the GBM.

Size barrier

The GBM acts as a sieve for molecules in the plasma. The fractional clearances, i.e. the ratio of various size dextrans clearance per inulin clearance, are convenient indices to evaluate the function of the size barrier. It ranges from 0 when test dextran molecules are impermeable to 1 when they encounter no mea-

surable restriction to filtration.³⁷⁾ In the dextran of 1.8 nm radius, the fractional clearance shows 1.0, and in the dextran of 44 nm radius, it indicates 0. These data were obtained by using neutral dextrans. When cationic or anionic dextrans are used, the fractional clearances shift to show increasing or decreasing tendencies. Damage to the size barrier also causes proteinuria. By a quick-freezing and deep-etching method, the disruption of the three-dimensional network structure was really recognized around the deposits of the GBM in the model of serum sickness nephritis.⁴⁰⁾

5) Cell attachment

Podocytes and capillary endothelial cells need to attach tightly to the GBM to avoid being disrupted by exposure to the pressure or the flow of filtrated urine or capillary blood (Fig. 3). In general, some types of cell surface glycoproteins are known to have a cytoadhesive function. The soles under the foot processes of podocytes possess specifically developed glycoproteins, compared with the soles of parietal epithelial and capillary endothelial cells.^{41,42)} They likely serve for tight attachment to the GBM against the hydropressure of filtered urine.

The components of the GBM work as ligands for binding between the cells and matrix. The cytoadhesive receptor molecules belonging to the integrin superfamily play important roles in this binding. Various kinds of integrin subfamilies, such as $\alpha 3\alpha 1$ (very late antigen-3) and $\alpha v\alpha 3$ (vitronectin receptor), are recognized on the surface of visceral epithelial cells and endothelial cells in the glomerulus.^{43,44)} One

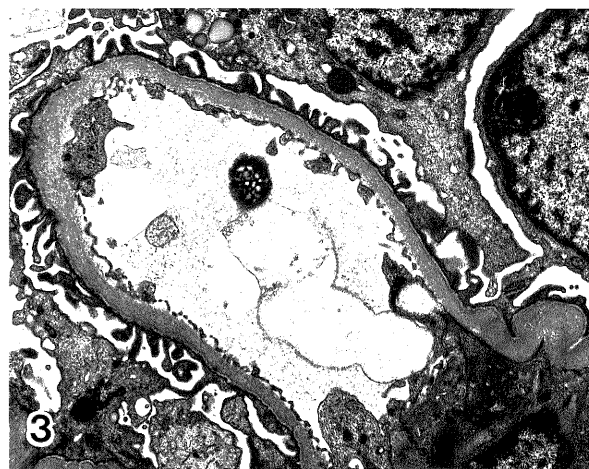


Fig. 3. Normal human GBM. Visceral epithelial cells and capillary endothelial cells tightly attach to the GBM. $\times 3,200$

interesting finding reported recently was that Anti-Fx1A antibody, which binds to glycoproteins on visceral epithelial cells and produces Heymann nephritis, recognizes a beta 1-integrin on cultured glomerular epithelial cells and inhibits adhesion and growth.⁴⁵⁾ It seems possible that α 1-integrin may be one of the antigens involved in membranous nephropathy.

III. Pathological changes in GBM

1) IgA nephropathy

Both primary and secondary IgA glomerulonephritis or nephropathy (IgAGN) associated with Henoch-Shönlein purpura (HSPGN) frequently show abnormalities in the GBM, such as simple thinning or injuries manifested as splitting, lamellation or lytic degeneration. Diffuse simple thinning of GBM, seen in 18% of IgAN,⁴⁶⁾ may be an accidental complication of thin basement membrane disease (TBMD). However, TBMD known as a hereditary disease was found in less than 10% or 15% of the whole renal biopsy series⁴⁷⁾ and familial cases of IgAGN are very rare. Therefore, the high frequency of diffuse thinning is derived from the pathogenesis of IgAGN itself.

The frequency of GBM injuries is also markedly variable, ranging from 13%⁴⁸⁾ to 70%⁴⁶⁾ of IgA nephropathy patients. The correlation between GBM injury and clinical or histological findings has been studied by many researchers. It has been suggested that the occurrence of GBM injuries is positively correlated with hematuria^{49,52)} and proteinuria,^{50,51)} while there are some reports showing controversial results.^{54,55)} There are also contradictory studies concerning the relationship between GBM injuries and histological changes, such as crescent formation and capillary adhesion.^{52,53,55)} Our study indicates that GBM injuries should be separated into two groups, one with paramesangial GBM injuries and the other with capillary loop GBM injuries, in order to resolve this controversial problem. We found a significant relationship between the paramesangial GBM injuries and the incidence of crescent formation and capillary adhesion, but not between capillary GBM injuries and the incidence of these changes.⁵⁵⁾ In previous studies, capillary loop GBM injuries have been only focused as GBM injuries. In order to obtain definitive results, careful attention should be given to the location of GBM injuries.

The pathogenesis of GBM injuries is still uncertain. Electron microscopy has shown neutrophils frequently adhering to the portion with GBM injuries.⁵⁴⁾

Lysosomal enzymes of neutrophils are candidates for one of the pathogenic factors, because they can degrade the components of the GBM.⁵⁶⁾ Activities of these enzymes have been detected in the urine of patients with glomerulonephritis. As another pathogenic factor matrix metalloproteinase (MMP) is suspected to be involved. MMP has been found to degrade the GBM *in vitro* experiments.^{57,58)} The secretion of MMP has been also recognized in cultured mesangial cells.⁵⁹⁾

2) Diabetes mellitus

Thickening is the most predominant change of the GBM in Diabetes Mellitus (DM) (Fig. 4). There are two hypotheses concerning the causes of this change. One advocates the role of advanced glycosylation end-products (AGE).^{60,61)} AGEs prolong the half life times of glycosylated proteins. The late turnover of the GBM is induced by the storage of glycosylated components of the GBM. Supporting this hypothesis, it has been reported that aminoguanidine, an inhibiting agent of glycosylation, prevented the thickening of the GBM.⁶²⁾ The other hypothesis emphasizes an excess production of GBM components, especially type IV collagen.⁶³⁾ In histochemical studies, the amount of type IV collagen was increased in thickened GBM,^{64,65)} whereas other components, such as HSPG and laminin, revealed a tendency to decrease.^{65,66)} These disproportional changes in GBM components may cause a thickening of the GBM. According to a detailed study on type IV collagen, the immunofluorescent reactivities to the novel type chains such as α 3(IV), α 4(IV) and α 5(IV), became more intense along the capillary GBM of diabetic glomeruli. In

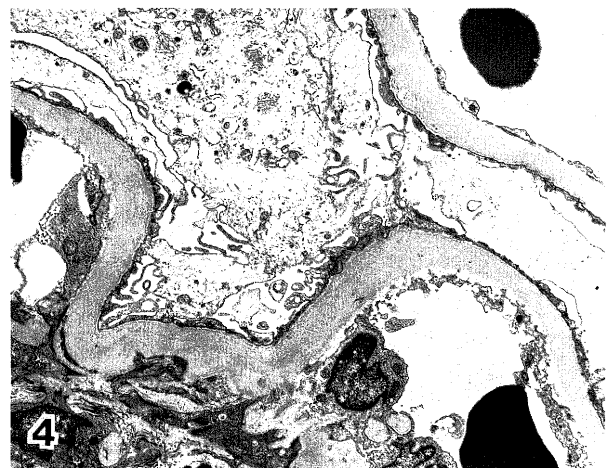


Fig. 4. Thickening of the GBM in diabetic glomerulosclerosis. $\times 3,200$

contrast, those reactivities against classical type collagen, such as $\alpha 1(\text{IV})$ and $\alpha 2(\text{IV})$, became faint along the GBM but more prominent in the expanded mesangial matrix.⁶⁷⁾ The exact reason for this heterogeneous change is not clear. The novel types are distributed more predominantly on the epithelial side, whereas the classical types are on the endothelial side of GBM as mentioned before. Therefore, it can be suspected that thickening of the GBM may be related to the hypersecretion of type IV collagen from the visceral epithelial cells.

As an additional change in the diabetic GBM, scattered thinning of the GBM has also been observed in the diabetic glomeruli by the morphometric analysis of whole glomerular areas.⁶⁸⁾ Why thinned GBMs appear together with thickened GBMs has not yet been answered.

3) Alport's syndrome

Alport's syndrome is a hereditary nephritis with urinary abnormalities that progresses to renal failure. The complication of bilateral sensorineural hearing loss has been believed to be a necessary finding in classical Alport's syndrome. However, several clinical subtypes without sensorineural hearing loss have now been identified. The genetic transmission forms are variable. Approximately 80% of all cases are compatible with X-linked dominant inheritance, and the rest are autosomally dominant or recessive inheritance. The characteristic pathological findings are thinning and irregular thickening with splitting or lamellation, the so called basket weave formation, of the GBM⁶⁹⁾ (Fig. 5). Irregular GBM thickening is more significantly related with the clinical severity,

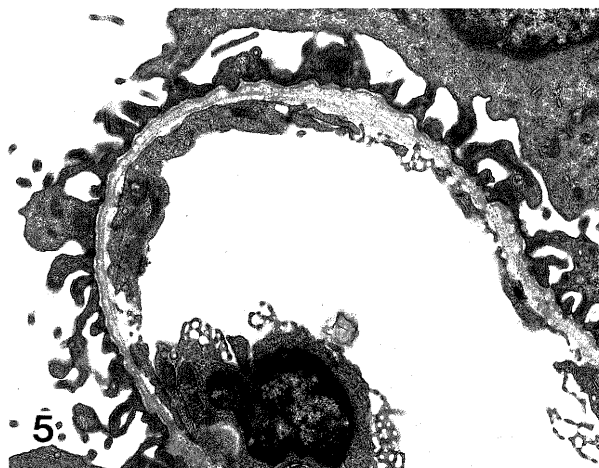


Fig. 5. Irregular and multi-lamellated GBM in Alport's syndrome. $\times 3,200$

compared with thinning of the GBM.⁷⁰⁾

It is known that anti-GBM alloantibodies appear in Alport's patients transplanted from normal donors, and cause the loss of the grafts. These alloantibodies have been identified with the antibodies reacting with the 26kDa NC1 domain of type IV collagen.⁷¹⁾ Recently the gene of $\alpha 5(\text{IV})$ has been ascertained to be located on X chromosome at locus Xq22(COL4A5).¹⁶⁾ NC1 of $\alpha 5(\text{IV})$ is equivalent to the NC1 domain of 26kDa. A genetic disorder has been found in COL4A5 in X linked Alport's syndrome cases.⁷²⁾ From these results, X linked Alport's syndrome is assumed to be derived from a genetic mutation in $\alpha 5(\text{IV})$.

4) TBMD

Thin basement membrane disease (TBMD) is a hereditary glomerular disease, although the mode of hereditary transmission is unclear and sporadic cases are often observed. Clinically, chance hematuria without proteinuria is a predominant sign. Compared with Alport's syndrome, most cases show no impairment in renal function, though a few cases have been reported to have progressed to renal failure. Minor glomerular abnormalities are noticed in light microscopy, and negative or non specific staining is the histological feature in immunofluorescence. Diffuse thinning of the GBM can be recognized in electron microscopy⁶⁹⁾ (Fig. 6). The definition of "thin basement membrane" differs among researchers. Usually the term indicates a membrane measuring less than 250 nm, but some authors consider a standard of less than 200 nm.⁷³⁾ The pathogenesis of the GBM thinning remains unresolved. A defect of Good-Pasture antigen (NC1 domain of $\alpha 3(\text{IV})$) has not been found in

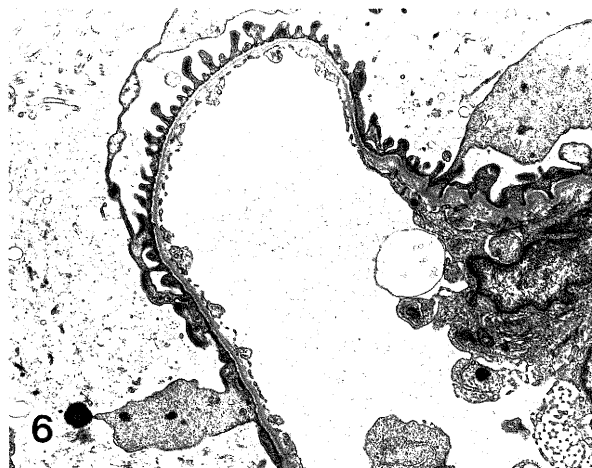


Fig. 6. Thinning of the GBM in thin basement membrane disease (TBMD). $\times 3,200$

a histochemical study,⁶⁹⁾ nor have genetic abnormalities been found in the genes of $\alpha 1(\text{IV})$ or $\alpha 2(\text{IV})$.⁴⁷⁾ Further studies on $\alpha 4(\text{IV})$ and $\alpha 5(\text{IV})$ chains are necessary to clarify the pathogenesis of TBMD.

REFERENCES

- 1) Martinez-Hernandez A, Amenta PS: The basement membrane in pathology. *Lab Invest* **48**: 656-677, 1983.
- 2) Abrahamson DR: Recent studies on the structure and pathology of basement membranes. *J Pathol* **149**: 257-248, 1986.
- 3) Timpl R, Aumailley M: Biochemistry of basement membranes. In: *Advances in nephrology*. Vol. 18, Year Book Medical Publishers, Inc. Chicago-London-Boca Raton, 1989, p 59-76.
- 4) Courtoy PJ, Timpl R, Farquhar MG: Comparative distribution of laminin, type IV collagen and fibronectin in rat glomerulus. *J Histochem Cytochem* **30**: 874-886, 1982.
- 5) Roll FJ, Madri JA, Albert J, Furthmayr H: Codistribution of collagen types IV and AB2 in basement membranes and mesangium of the kidney. An immunoferritin study of ultrathin sections. *J Cell Biol* **85**: 597-616, 1980.
- 6) Abrahamson DR, Caulfield JP: Distribution of laminin with rat and mouse renal, splenic, intestinal and hepatic membranes identified after the intravenous injection of heterogeneous antilaminin IgG. *Lab Invest* **52**: 169-181, 1985.
- 7) Madri JA, Roll FJ, Furthmayr H, Foidart JM: Ultrastructural localization of fibronectin and laminin in the basement membranes of the murine kidney. *J Cell Biol* **86**: 682-687, 1980.
- 8) Stow JL, Sawada H, Farquhar MG: Basement membrane heparan sulfate proteoglycans are concentrated in the laminae rarae and in podocytes of the rat renal glomerulus. *Proc Natl Acad Sci USA* **82**: 3296-3300, 1985.
- 9) Miettinen A, Stow JL, Metone SA, Farquhar MG: Antibodies to basement membrane heparan sulfate proteoglycans bind to the lamina rara of the glomerular basement membrane (GBM) and induce subepithelial GBM thickening. *J Exp Med* **163**: 1064-1084, 1986.
- 10) Laurie GW, Leblond CP, Inoue S, Martin GR, Chung AE: Structure of the basement membrane and immunolocalization of five basement membrane components of the lamina densa and its extensions in both glomeruli and tubules of the rat kidney. *Am J Anat* **169**: 463-481, 1984.
- 11) Martinez-Hernandez A, Chung AE: The ultrastructural localization of two basement membrane components, entactin and laminin in rat tissues. *J Histochem Cytochem* **32**: 289-298, 1984.
- 12) Dick RF, Lockwood CM, Kershq M, McHugh N, Duance VC, Baltz ML, Pepys MB: Amyloid P-component is a constituent of normal human glomeruli. *J Exp Med* **152**: 1162-1174, 1980.
- 13) Crouch E, Sage H, Bornstein P: Structural basis for apparent heterogeneity of collagens in human basement membranes: Type IV procollagen contains two distinct chains. *Proc Natl Acad Sci USA* **77**: 745-749, 1980.
- 14) Butkowski RJ, Wieslander J, Kleppel M, Michael AF, Fish AJ: Basement membrane collagen in the kidney: Regional localization of novel chains related to collagen IV. *Kidney Int* **35**: 1195-1202, 1989.
- 15) Desjardins M, Gros R, Wieslander J, Gubler MC, Bendayan M: Heterogeneous distribution of monomeric elements from the globular domain (NC1) of type IV collagen in renal basement membranes as revealed by high resolution quantitative immunocytochemistry. *Lab Invest* **63**: 637-646, 1990.
- 16) Hostikka SL, Eddy RL, Byers MG, Höyhty M, Shows TB: Identification of a distinct type IV collagen α chain with restricted kidney distribution and assignment of its gene to the locus of X chromosome linked Alport syndrome. *Proc Natl Acad Sci USA* **87**: 1606-1610, 1990.
- 17) Schittny JC, Timpl R, Engel J: High resolution immunoelectron microscopic localization of functional domains of laminin, nidogen, and heparan sulfate proteoglycan in epithelial basement membrane of mouse cornea reveals different topological orientations. *J Cell Biol* **107**: 1559-1610, 1988.
- 18) Ekblom P: Developmentally regulated conversion of mesenchyme to epithelium. *FASEB J* **3**: 2141-2150, 1989.
- 19) Abrahamson DR, Irwin MH, John PL S, Perry EW, Accavitti MA, Heck LW, Couchman JR: Selective immunoreactivities of kidney basement membranes to monoclonal antibodies against laminin: Localization of the end of the long arm and the short arms to discrete microdomains. *J Cell Biol* **109**: 3477-3491, 1989.
- 20) Kanwar YS, Linker YS, Farquhar MG: Increased permeability of the glomerular basement membrane to ferritin after removal of glycosaminoglycans (heparan sulfate) by enzyme digestion. *J Cell Biol* **86**: 688-693, 1980.
- 21) Voss B, Glössl J, Cully Z, Kresse H: Immunocytochemical investigation on the distribution of small chondroitin sulfate-dermatan sulfate proteoglycan in the human. *J Histochem Cytochem* **24**: 1013-1019, 1986.
- 22) Rada JA, Carlson EC: Electron microscopic histochemical and immunochemical analyses of heparan sulfate proteoglycan distribution in renal glomerular basement membranes. *Histol Histopathol* **6**: 149-160, 1991.
- 23) Yoshida F, Matsuo S, Hiramatsu T, Okura T, Yuzawa Y, Watanabe Y, Sakamoto N, Matsuo S:

- Glomerular injury induced by antibodies against heparan sulfate proteoglycan (HSPG) derived from PYS 2 cells. *Nippon Jinzo Gakkai Shi* **31**: 135-143, 1989. (abstract in English)
- 25) Mank K, Deutzmann R, Aumailley M, Timpl R, Raimondi L, Yamada Y, Pan T-C, Conway D, Chu M-L: Amino acid sequence of mouse nidogen, a multidomain basement membrane protein with binding activity of laminin, collagen IV and cells. *EMBO J* **8**: 65-72, 1989.
 - 26) Durkin ME, Chakravarti S, Bartos BB, Liu S-H, Freidman RL, Chung AE: Amino acid sequence and domain structure of entactin. Homology with epidermal growth factor precursor and low density lipoprotein receptor. *J Cell Biol* **107**: 2749-2756, 1988.
 - 27) Katz A, Fish AJ, Kleppel MM, Hagen SG, Michael AF, Butkowski RJ: Renal entactin (nidogen): isolation, characterization and tissue distribution. *Kidney Int* **40**: 643-652, 1991.
 - 28) Thorning D, Vracko R: Renal glomerular basal lamina scaffold. Embryological development, anatomy, and role in cellular reconstruction of rat glomeruli injured by freezing and thawing. *Lab Invest* **37**: 105-109, 1977.
 - 29) Sariola H, Timpl R, von der Mark K, Mayne R, Fitch JM, Linsenmayer TF, Ekblom P: Dual origin of glomerular basement membrane. *Dev Biol* **101**: 86-96, 1984.
 - 30) Abrahamson DR, Perry EW: Evidence for splicing new basement membrane into old during glomerular development in newborn rat kidneys. *J Cell Biol* **103**: 2489-2498, 1986.
 - 31) Abrahamson DR: Structure and development of the glomerular capillary wall and basement membrane. *Am J Physiol* **253**: 783-794, 1987.
 - 32) Price RG, Spiro RD: Studies on the metabolism of the renal glomerular basement membrane. *J Biol Chem* **252**: 8597-8602, 1977.
 - 33) Abrahamson DR, Caulfield JP: Proteinuria and structural alterations in rat glomerular basement membranes induced by intravenously injected anti-laminin immunoglobulin G. *J Exp Med* **156**: 128-145, 1982.
 - 34) Carlson EC, Audette JL: Intrinsic fibrillar components of human glomerular basement membranes: a TEM analysis following proteolytic dissection. *J Submicrosc Cytol Pathol* **21**: 83-92, 1989.
 - 35) Hora K: Ultrastructural study of normal rat glomeruli by the quick-freezing and deep-etching method. *Nippon Jinzo Gakkai Shi* **33**: 839-848, 1991. (abstract in English)
 - 36) Takami H, Naramoto A, Shigematsu H, Ohno S: Ultrastructure of glomerular basement membrane by quick-freeze and deep-etch methods. *Kidney Int* **39**: 659-664, 1991.
 - 37) Kanwar YS: Biology of disease. Biophysiology of glomerular filtration and proteinuria. *Lab Invest* **51**: 7-21, 1984.
 - 38) Goode NP, Shires M, Crellin DM, Davison-AM: Detection of glomerular anionic sites in post-embedded ultra-thin sections using cationic colloidal gold. *J Histochem Cytochem* **39**: 965-972, 1991.
 - 39) Bertolatus JA, Hunsicker LG: Polycation binding to glomerular basement membrane. Effect of biochemical modification. *Lab Invest* **56**: 170-179, 1987.
 - 40) Naramoto A, Ohno S, Nakazawa K, Takami H, Itoh N, Shigematsu H: Three-dimensional ultrastructure of glomerular injury in serum sickness nephritis using the quick-freezing and deep-etching method. *Virchows Arch A Pathol Anat Histopathol* **418**: 185-192, 1991.
 - 41) Nishi S, Ozawa H, Arakawa M: A cytochemical study of glycocalyx and the membrane cholesterol of rat glomerular podocytes. *Arch Histol Cytol* **53**: 371-379, 1990.
 - 42) Kunz A, Brown D, Orci L: Appearance of helix pomatia lectin-binding sites on podocyte plasma membrane during glomerular differentiation. *Lab Invest* **51**: 317-324, 1984.
 - 43) Korhonen M, Ylanne J, Laitinen L, Virtanen I: Distribution of beta 1 and beta 3 integrins in human fetal and adult kidney. *Lab Invest* **62**: 616-625, 1990.
 - 44) Cosio FG: Cell-matrix adhesion receptors: relevance to glomerular pathology. *Am J Kidney Dis* **20**: 294-305, 1992.
 - 45) Adler S, Chen X: Anti-Fx1A antibody recognizes a beta 1-integrin on glomerular epithelial cells and inhibits adhesion and growth. *Am J Physiol* **262**: 770-776, 1992.
 - 46) Arakawa M, Suzuki S, Maruyama Y, Ogino S, Kobayashi, Nishi S, Satoh H, Ueno M, Saito T, In H, Takayama R: Renal pathology of adult patients with IgA nephropathy. Nishimura, Smith-Gordon, Niigata-London, 1988, p 105-135.
 - 47) Savige J: Hereditary abnormalities of renal basement membranes. *Pathology* **23**: 350-355, 1991.
 - 48) Navas-Palacios JJ, Gutierrez-Millet V, Usera-Saraga G, Garzon-Martin A: IgA nephropathy. An ultrastructural study. *Ultrastruct Pathol* **2**: 151-161, 1981.
 - 49) Taguchi T, von Bassewitz DB, Grundmann E: Ultrastructural changes of glomerular basement membrane in IgA nephritis: Relationship to hematuria. *Ultrastruct Pathol* **12**: 17-26, 1988.
 - 50) Morita M, Sakaguchi H: Quantitative study of glomerular basement membrane changes in IgA nephropathy. *J Pathol* **154**: 9-18, 1988.
 - 51) Ng WL, Chan KW, Yeung CK, Kwan S: Peripheral glomerular capillary wall lesions in IgA nephropathy and their implications. *Pathology* **16**: 324-330, 1984.
 - 52) Lee HS, Choi Y, Lee JS, Yu BH, Koh HI: Ultrastructural changes in IgA nephropathy in relation to histologic and clinical data. *Kidney Int* **35**: 880-886, 1989.
 - 53) Nomura Y, Ohya N, Shimda M: A histopathological study on the prognosis of childhood IgA nephro-

- pathy and glomerular basement membrane lesions. *Pediatr Nephrol* **3**: 2442-247, 1989.
- 54) Yoshikawa N, Yoshiara S, Yoshia K, Matsuo T: Lysis of the glomerular basement membrane in children with IgA nephropathy and Henoch-Shönlein nephritis. *J Pathol* **150**: 119-126, 1986.
- 55) Nishi S, Ueno M, Satou H, Karasawa R, Inn H, Kazama J, Saitou T, Saito N, Kishimoto H, Suzuki S, Arakawa M: Clinico-pathological study of GBM injury and rupture of Japanese IgA nephropathy. Nishimura, Smith-Gordon, Niigata-London 1993. (in press)
- 56) Vissers MCM, Wiggins R, Fantone JC: Comparative ability of human monocyte and neutrophils to degrade glomerular basement membrane *in vitro*. *Lab Invest* **60**: 831-838, 1989.
- 57) Nguyen HH, Baricos WH, Shah-SV: Degradation of glomerular basement membrane by a neutral metalloproteinase(s) present in glomeruli isolated from normal rat kidney. *Virchows Arch A Pathol Anat Histopathol* **418**: 185-192, 1991.
- 58) Shah SV, Baricos WH, Basci A: Degradation of human glomerular basement membrane by stimulated neutrophils. Activation of a metalloproteinase(s) by reactive oxygen metabolites. *J Clin Invest* **79**: 25-31, 1987.
- 59) Martin J, Davies M, Thomas G, Lovett DH: Human mesangial cells secrete a GBM-degrading neutral proteinase and a specific inhibitor. *Kidney Int* **36**: 790-801, 1989.
- 60) Choen MP, Uradanivia E, Wu VY: Nonenzymatic glycosylation of basement membranes. *Renal Physiol* **4**: 90-95, 1981.
- 61) Choen MP, Uradanivia, Surma M, Wu V-Y: Increased glycosylation of glomerular basement membrane in diabetes. *Biochem Biophys Res Commun* **95**: 765-769, 1980.
- 62) Ellis EN, Good BH: Prevention of glomerular basement membrane thickening by aminoguanidine in experimental diabetes mellitus. *Metabolism*. **40**: 1016-1019, 1991.
- 63) Reddi AS: Glomerular basement membrane collagen synthesis rates in normal and diabetic rats. *Res Commun Chem Pathol Pharmacol* **59**: 283-286, 1988.
- 64) Woodrow D, Moss J, Shore I, Spiro RG: Diabetic glomerulosclerosis—immunogold ultrastructural studies on the glomerular distribution of type IV collagen and heparan sulfate proteoglycan. *J Pathol* **167**: 49-58, 1992.
- 65) Makino H, Ikeda S, Haramoto T, Ota Z: Heparan sulfate proteoglycans are lost in patients with diabetic nephropathy. *Nephron* **61**: 415-421, 1992.
- 66) Shimomura H, Spiro RG: Studies of macromolecular components of human glomerular basement membrane and alterations in diabetes. Decreased levels of heparan sulfate proteoglycan and laminin. *Diabetes* **36**: 374-381, 1987.
- 67) Kim Y, Kleppel MM, Butkowski R, Mauer SM, Wieslander J, Michael AF: Differential expression of basement membrane collagen chains in diabetic nephropathy. *Am J Pathol* **138**: 413-420, 1991.
- 68) Hayashi H, Karasawa R, Inn H, Saitou T, Ueno M, Nishi S, Suzuki Y, Ogino S, Maruyama Y, Kouda Y, Arakawa M: An electron microscopic study of glomeruli in Japanese patients with non-insulin dependent diabetes mellitus. *Kidney Int* **41**: 749-757, 1992.
- 69) Nöwel LH, Gubler MC, Bobrie G, Savage COS, Lockwood CM, Grünfeld JP: Inherited defects of renal basement membranes. Advances in nephrology. Vol. 18. Year Book Medical Publishers, Inc. Chicago-London-Boca Raton, 1989, p 77-94.
- 70) Basta-Jovanovic G, Venkatasreshan VS, Churg J: Correlation of glomerular basement membrane alterations with clinical data in progressive hereditary nephritis (Alport's syndrome). *Am J Kidney Dis* **16**: 51-56, 1990.
- 71) Kashtan C, Fish AJ, Kleppel M, Yoshioka K, Michael AF: Nephritogenic antigen determinants in epidermal and renal basement membranes of kindreds with Alport-type familial nephritis. *J Clin Invest* **78**: 1035-1044, 1986.
- 72) Barker DF, Hostikka SL, Zhou J, Chow LT, Oliphant AR, Gerken SC, Atkin CL, Tryggvason K: Identification of mutations in the COL4A5 collagen gene in Alport syndrome. *Science* **248**: 1224-1227, 1990.
- 73) Ueno M: Thin basement membrane disease in patients with asymptomatic hematuria and/or proteinuria: a clinicopathological study. *Nippon Jinzo Gakkai Shi*. **33**: 339-347, 1991. (abstract in English)