

# Extensive Epithelioid Cell Granulomatous Reactions to Esophageal and Gastric Carcinomas: Immunohistochemical Investigations of Four Cases

Tadashi NISHIMAKI, Noriko ISHIHARA\*, Hidenobu WATANABE\*, Otsuo TANAKA, Tsutomu SUZUKI, Kikuo AIZAWA, Katsuyoshi HATAKEYAMA and Terukazu MUTO

The First Department of Surgery and \*First Department of Pathology, Niigata University School of Medicine, Asahimachi 1, Niigata 951, Japan

*Received July 6, 1993*

**Summary.** Four cases of extensive epithelioid cell granulomatous reaction occurring in two gastric and two esophageal cancer patients are presented. Non-caseating epithelioid cell granulomas (NCEG) developed not only in the regional lymph nodes but within and widely around the primary tumor in all cases. NCEG also involved the spleen in one patient with early gastric cancer. The epithelioid cells directly infiltrated inside the tumor and obliterated cancer cells in one patient with esophageal cancer, the findings demonstrating histologic evidence that those cells have the ability to kill cancer cells. Three patients manifested the same immune alterations as those in sarcoidosis. Thus, NCEG associated with cancer are considered a morphological manifestation of the host immune response to cancer, most likely developing in the lymphoid organs. The extensive manifestation of such changes may develop under the altered immune conditions.

## INTRODUCTION

It is well known that non-caseating epithelioid cell granulomas (NCEG) morphologically identical to those found in sarcoidosis may occasionally develop within or adjacent to the primary tumor and in the regional lymph nodes draining the primary lesion in patients with malignant neoplasms.<sup>1,2)</sup> These changes, distinguished from generalized sarcoidosis by the absence of multisystemic organ involvement, have been reported in various terms including sarcoid-like granulomas, sarcoid-like lesions, or sarcoid-like reactions.<sup>2)</sup> These NCEG have been considered as one

of the host immune responses to malignant neoplasms.<sup>3)</sup> Although a large number of cases of such reactions have been reported in the literature, the topographical relationships of the granulomatous changes with the spread of cancer tissue and their histologic varieties have been insufficiently characterized. Furthermore, it remains uncertain whether these reactions are related to the same immunological abnormalities as those manifested in sarcoidosis.

We have experienced 4 cases of esophageal and gastric cancers associated with extensive epithelioid cell granulomatous reactions developing not only in the regional lymph nodes but also within and widely around the primary tumor. All of them showed immunological alterations of varying degree. Moreover, one of these cases exhibited unusual epithelioid cell reactions against the cancer tissue.

The purpose of the present report is, therefore, to present these 4 cases of extensive epithelioid cell granulomatous reactions against esophageal and gastric cancers; to characterize the histological, immunohistochemical, and topographical features of such granulomas; and to consider the pathogenesis of these reactions against a review of the literature.

## CASE REPORTS

### Case 1

E. S., a 40-year-old woman, underwent a total gastrectomy with splenectomy, caudal pancreatectomy, and

radical lymphadenectomy for gastric cancer at one of our affiliated hospitals on August 4, 1983. Routine preoperative examinations were unremarkable although past history revealed a penicillin allergy. Since numerous NCEG identical to those observed in sarcoidosis were revealed in the resection specimens, further examinations were performed to identify concomitant sarcoidosis, including a chest computed tomography (CT), ophthalmological examination, serum angiotensin converting enzyme (ACE) assay, purified protein derivative (PPD) skin test, Kveim test, and quantitative serum immunoglobulin determination. All examinations were within normal limits except for a positive skin test for PPD and a slight elevation of serum Ig M level (Table 1). She was discharged on August 31, 1983, and remained disease-free during the subsequent 41 months after surgery, after which we lost contact.

#### *Macroscopic findings of the specimens*

The resected stomach showed a depressed type early cancer with a size of 2.1 cm at the greater curvature of the upper body of the stomach accompanying a peptic ulcer inside the tumor. Otherwise, the resected stomach appeared normal. The simultaneously resected spleen and pancreas showed no gross abnormalities.

#### *Histologic findings of the specimens*

The depressed lesion of the stomach was a signet-ring cell carcinoma confined to the mucosa. Interestingly, numerous NCEG with occasional giant cells of a Langhans type or foreign body type indistinguishable from those found in sarcoidosis were found to be diffusely distributed all over the stomach (Fig. 1). These NCEG were predominantly present in the

mucosa and submucosa although the NCEG were scattered in all layers of the stomach wall. Most of them were encircled with a hyaline-like substance, which was negative for Congo red stain, and lymphoid aggregates. A few of the NCEG arose in the lymphatic vessels. As shown in Fig. 2, close topographical relationships between the cancerous lesion and the NCEG were not evident, although some of the NCEG were located in the submucosa beneath the cancer. Similar granulomas also developed in the distal esophageal stump, the proximal duodenal stump, the spleen, and all of the regional lymph nodes simultaneously resected. In the spleen, a few NCEG were located at the red pulp. Cancer metastasis was found in some lymph nodes with no topographical connection to the NCEG. Sinus histiocytosis developed in none of the lymph nodes. No organisms were demonstrated by Ziehl-Neelsen or fungal stains.

#### *Immunohistochemical findings*

The sections of the paraffin-embedded tissue blocks of the lesions were submitted to immunohistochemical analysis using the histiocyte markers including lysozyme (Dako, Denmark), non-specific cross-acting antigen (Motida, Tokyo, Japan), and S-100- $\beta$  protein (Jimro, Takasaki, Japan): PAP method<sup>4)</sup> for lysozyme and SAB method<sup>5)</sup> for non-specific cross-acting antigen (NCA) and S-100- $\beta$  protein. As shown in Table 2, the epithelioid cells and giant cells both at the primary site and at the regional lymph node showed a positive reaction only for lysozyme.

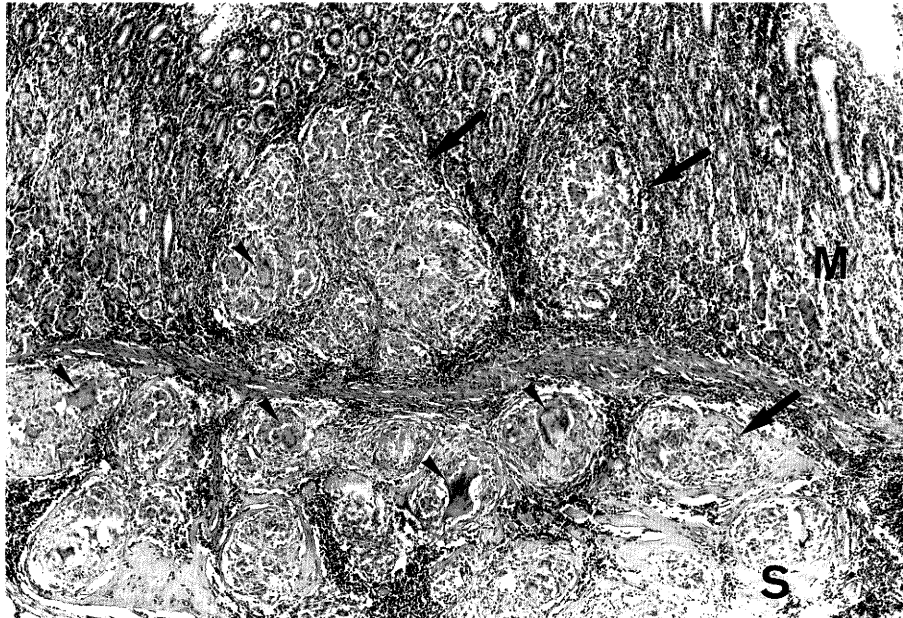
### **Case 2**

K. A., a 65-year-old woman, had a palliative blunt esophagectomy with proximal gastrectomy for distal

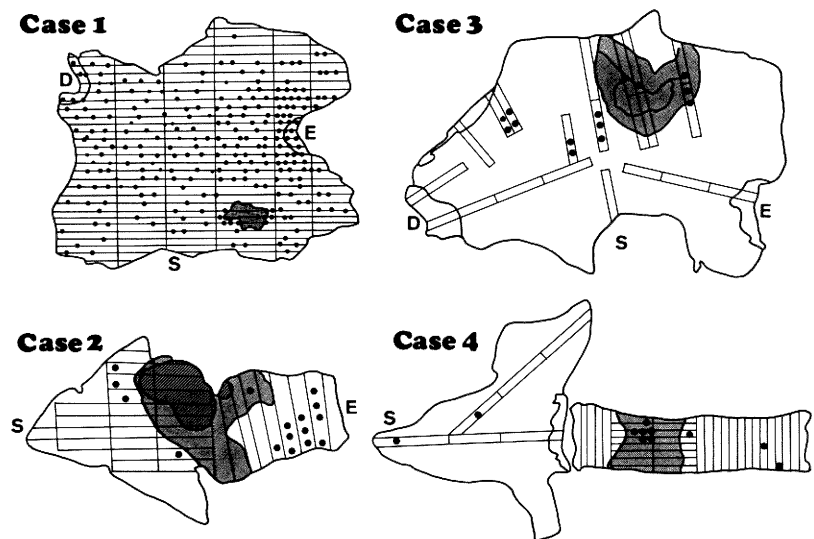
**Table 1.** Immunological parameters on admission.

	PPD skin test	SU-PS skin test	$\gamma$ -globulin (g/dl)	IgG	IgA (mg/dl)	IgM	Other data
Case 1	positive	ND	1.0	1610	320	343*(H)	Kveim test: negative* ACE: WNL*
Case 2	negative	negative	2.1 (H)	2390 (H)	140	142	PBL: 1400/cu.mm. T-cell: 33% (L) B-cell: 61% (H)
Case 3	ND	negative	1.2	1803	401(H)	310(H)	
Case 4	negative	negative	1.1	1540	674(H)	94	PBL: 1104/cu.mm. (L) T-cell: 87% B-cell: 10%

SU-PS: SU-polysaccharide, ACE: angiotensin converting enzyme, PBL: peripheral blood lymphocyte, ND: not done, WNL: within normal limits, H: higher than normal limits, L: lower than normal limits. \*: postoperatively examined. Normal range:  $\gamma$ -globulin (0.8-1.6 g/dl); IgG (889-1968 mg/dl); IgA (93-380 mg/dl); IgM (50-290 mg/dl).



**Fig. 1.** NCEG morphologically identical to those found in sarcoidosis. Note numerous NCEG (arrows) found in the mucosa (M) and submucosa (S) of the stomach in Case 1. Arrow heads indicate giant cells of the Langhans type or foreign body type. Hematoxylin and eosin stain.  $\times 16$



**Fig. 2.** Spatial distribution of NCEG in and around the primary tumor. Dots indicate NCEG; dark areas indicate cancerous lesions; darker area in Case 2 indicates the spread of the epithelioid cells infiltrating the tumor. E, S, and D indicate the esophagus, the stomach, and the duodenum, respectively.

esophageal cancer with extensive lymph node metastases at the Niigata University Hospital on April 21, 1983. Laboratory data on admission revealed some immunological abnormalities: negative skin tests for PPD and SU-polysaccharide (SU-PS);<sup>6)</sup> hypergammaglobulinemia due to an elevation of serum Ig G level; decreased T-cell and increased B-cell populations as shown in Table 1. Other routine laboratory data were within normal limits. A chest CT revealed a circular thickening of the distal esophagus due to the cancer infiltration and enlargements of the paracardial lymph nodes due to cancer metastasis, while the lymph nodes at the bilateral pulmonary hila were unaffected. After discharge on May 18, 1983, ascites and emaciation developed, and she died of cancer cachexia on August 25, 1985.

#### *Macroscopic findings of the specimens*

The resected specimen showed an expansive ulcerative carcinoma of the distal esophagus, measuring 8 cm in diameter. The other parts of the specimen appeared normal.

#### *Histologic findings of the specimens*

The tumor was an adenocarcinoma massively extending down to the adventitia. The tumor histologically consisted of several components of adenocarcinoma with various cytological differentiation including a poorly differentiated medullary, poorly differentiated schirrhous, well differentiated tubular and papillary adenocarcinomas, although the main part of the tumor was a medullary carcinoma with a clear cell appearance.

Besides the cancerous lesion, NCEG were found to be scattered in the neighboring esophageal and gastric mucosa (Fig. 2). These granulomas were com-

posed of sparsely packed epithelioid cells with occasional giant cells of the Langhans type. These were generally smaller in size as compared with those observed in Case 1, resembling those seen in Crohn's disease. Lymphoid cell infiltration was minimal around the granulomas. More interestingly, the epithelioid cells diffusely infiltrated inside the tumor tissue and encircled the tumor nests exclusively at the part of the medullary carcinoma, showing a clear cell appearance (Fig. 3-A). Cancer cells were almost obliterated in some nests by the extensive infiltration of the epithelioid cells. These changes were associated with marked stromal infiltration of lymphoid cells. Such vigorous epithelioid cell reactions were not observed in other histologic components of the tumor.

The medullary carcinoma with a clear cell appearance was revealed to have fine granules when stained by periodic acid-Schiff (PAS) in the cytoplasm of the cancer cells. These granules were no longer stained by PAS after a diastase process, indicating that the intracytoplasmic granules were glycogen.

The same vigorous epithelioid cell reactions developed in the metastatic cancer tissue in some of the regional lymph nodes. Furthermore, these reactions developed not only at the medullary carcinomatous parts but also at the tubular or papillary adenocarcinomatous parts of the metastatic cancer in the lymph nodes. These changes were not found in the lymph nodes free from cancer metastasis. Ziehl-Neelsen and fungal stains were negative.

#### *Immunohistochemical findings*

As shown in Table 2, the epithelioid cells infiltrating inside the tumor tissue both at the primary site and in the lymph nodes were diffusely positive for lysozyme

**Table 2.** Immunohistochemical results of the assessment of histiocyte markers of the epithelioid cells and giant cells composing the granulomatous lesions.

	Primary cancer	Location of NCEG examined	Lysozyme (DAKO)	NCA (MOTIDA)	S-100- $\beta$ (JIMRO)
Case 1	gastric AC	primary site	+	—	—
		lymph node	+	—	—
Case 2	esophageal AC	primary site	+	$\pm$	—
		lymph node	+	$\pm$	—
Case 3	gastric AC	primary site	NA	NA	NA
		lymph node	$\pm$	—	—
Case 4	esophageal SCC	primary site	+	—	—
		lymph node	+	—	—

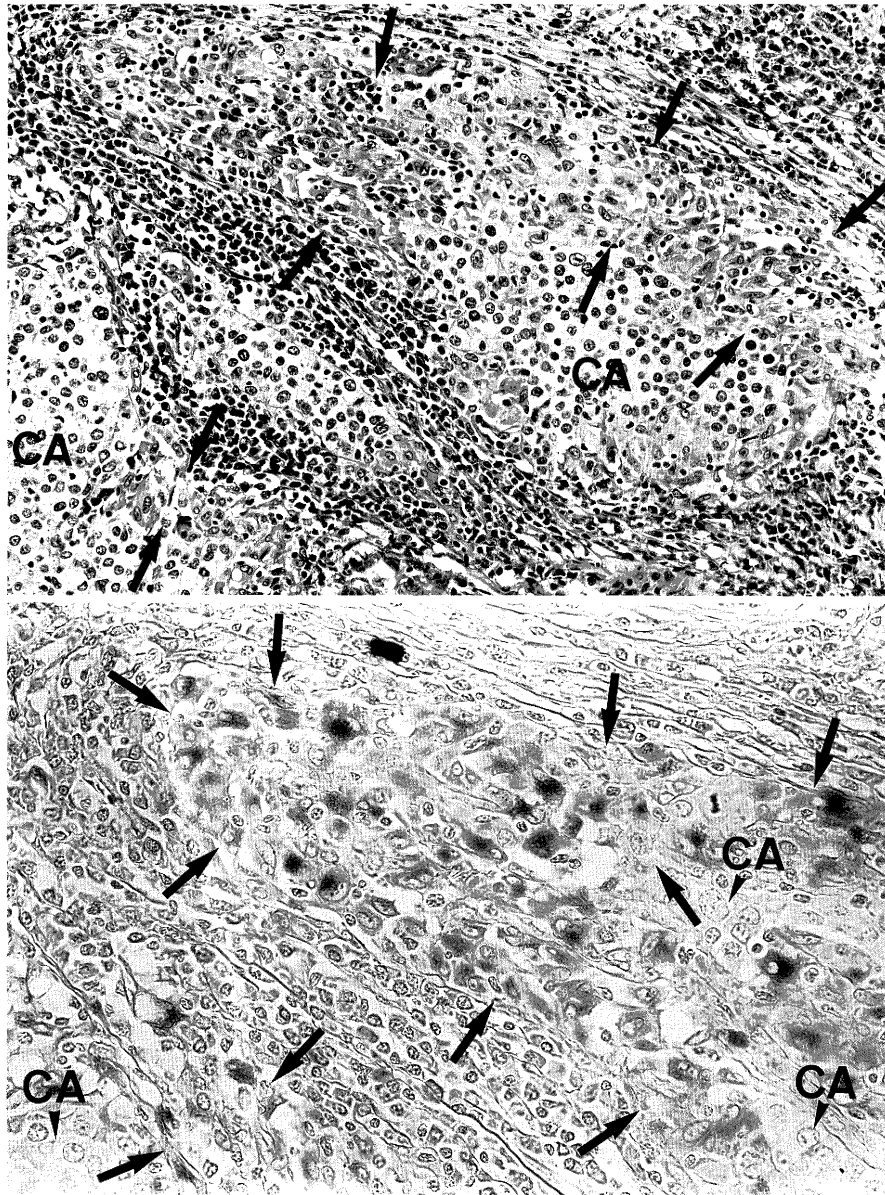
NCA: non-specific cross-acting antigen, AC: adenocarcinoma, SCC: squamous cell carcinoma, NA: not assessed, +: diffusely positive,  $\pm$ : focally positive, —: negative.

and focally positive for NCA (Fig. 3-B). S-100- $\beta$  was negative in these cells. The epithelioid cells and giant cells composing the NCEG around the tumor also represented the same immunophenotypes as those of the epithelioid cells infiltrating the tumor.

### Case 3

C. O., a 40-year-old woman, underwent a total gas-

trectomy with splenectomy, caudal pancreatectomy, partial resection of the transverse colon, and radical lymphadenectomy for advanced gastric cancer at one of our affiliated hospitals on June 6, 1983. Routine laboratory data on admission were within normal limits except for altered immunological parameters (Table 1). She was discharged on July 21, 1983. Two years after the discharge, she developed liver metastases, multiple lung metastases, and lymph node



**Fig. 3.** A. Epithelioid cell infiltration inside the tumor tissue (arrows) observed in Case 2. Cancer cell nests (CA) are encompassed by the epithelioid cells. Hematoxylin and eosin stain.  $\times 50$ . B. Epithelioid cells reacting positively with lysozyme. Arrows and arrow heads indicate the epithelioid cells and cancer cell nests (CA), respectively. PAP method.  $\times 100$

metastases in the supraclavicular region. She died of the disease on August 18, 1985.

#### *Macroscopic findings of the specimens*

The resected stomach showed an infiltrative ulcerative carcinoma 6 cm in diameter at the greater curvature of the gastric body.

#### *Histologic findings of the specimens*

The tumor was a poorly differentiated adenocarcinoma extending down through the stomach wall into the muscularis propria of the transverse colon in a schirrhous fashion. As shown in Fig. 2, NCEG were found to be present in the stomach within or around the cancer. Inside the tumor tissue, the NCEG were mainly located at the periphery of the tumor. Outside the tumor, the NCEG were distributed in the mucosa and the submucosa of the stomach, and were encircled by the lymphoid aggregates. Similar granulomas were found in several lymph nodes, where the granulomas were present in a tighter formation and consisted of more closely packed epithelioid cells and giant cells than those at the primary lesion. No sinus histiocytosis developed in any of the lymph nodes. There were no NCEG in the spleen, the caudal pancreas, or the transverse colon. Ziehl-Neelsen and fungal stains were negative.

#### *Immunohistochemical findings*

The epithelioid cells and giant cells at the lymph node were positive only for lysozyme.

### **Case 4**

T. N., a 63-year-old man, had a total thoracic esophagectomy with proximal gastrectomy and extensive lymphadenectomy for esophageal cancer at the Niigata University Hospital on November 28, 1985. Laboratory data on admission revealed some altered immunological parameters as shown in Table 1. A chest x-ray film and a chest CT revealed no evidence of lymph node enlargements at the mediastinum and pulmonary hila. After discharge on February 22, 1986, he developed multiple lung metastases and lymph node metastases in the upper mediastinum, and died of the disease on April 9, 1989.

#### *Macroscopic findings of the specimens*

The resected specimen represented an infiltrative ulcerative carcinoma at the middle portion of the esophagus, measuring 4 cm in diameter.

#### *Histologic findings of the specimens*

The tumor was a moderately differentiated squamous cell carcinoma extending down to the adventitia. In some parts of the tumor, NCEG with Asteroid bodies were found to surround the cancer tissue with lymphoid aggregates. Similar granulomas were also found in the mucosa and submucosa of the esophagus as well as in the stomach apart from the primary tumor (Fig 2). Almost all of the regional lymph nodes had the same granulomas in a closer distribution. Sinus histiocytosis was not evident. Ziehl-Neelsen and fungal stains were negative.

#### *Immunohistochemical findings*

The epithelioid cells and giant cells reacted positively with lysozyme alone, both at the primary site and the lymph node (Table 2).

## **DISCUSSION**

It has been well established that a number of diseases may cause granulomatous changes in the upper digestive tract besides the granulomatous reactions to malignant tumors: sarcoidosis, Crohn's disease, isolated granulomatous gastritis,<sup>7)</sup> and some infectious diseases such as tuberculosis, syphilis, or fungal infections. It is thus essential to discriminate between these diseases. Although some cases of the coexistence of a gastrointestinal cancer with sarcoidosis or Crohn's disease have been noted,<sup>8,9)</sup> our cases herein reported are certainly differentiated from the concomitant association of either disease because of the absence of clinical evidence compatible with sarcoidosis or Crohn's disease. Isolated granulomatous gastritis is also unlikely because of the lack of remarkable gross changes at the non-cancerous parts of the specimens in our cases. The infectious diseases cannot be considered as causative because of the absence of both clinical and histologic evidence. Accordingly, the granulomatous changes in our cases are properly considered as reactions against cancer.

A wide variety of malignant neoplasms have been reported to have the ability to evoke non-caseating granulomatous reactions, indicating that differences in tumor histology do not influence the development of the granulomatous reactions.<sup>2,10)</sup> Our results also support the aforementioned findings because the granulomatous changes developed both in squamous cell carcinoma and adenocarcinoma with various cytological differentiation in our series.

The topographical relationships between the

NCEG and the cancerous lesion have been poorly documented. The spatial distribution of the NCEG in our cases seems to be unique because the NCEG developed not only in the regional lymph nodes but also in and around the primary tumor. Furthermore, the NCEG extensively spread apart from the tumor, particularly in Case 1. Similar cases of gastric cancer associated with NCEG showing such an extensive distribution have been described by Sato et al.<sup>11)</sup> and Mizoguchi et al.<sup>12)</sup> Interestingly, NCEG also developed in the spleen, which cannot be considered a regional organ in terms of the lymphatic drainage from the stomach in Case 1, challenging the traditional idea that the tumor-associated granulomatous change is a "local" response to the tumor.

Most interestingly, the epithelioid cells diffusely infiltrated the tumor tissue and obliterated cancer cells at some parts of the tumor in Case 2, demonstrating histologic evidence that epithelioid cells can act as effector cells killing cancer cells, as suggested by Adams et al.<sup>13)</sup> A similar response of the epithelioid cells to malignant tumors has been reported in cases of ovarian dysgerminoma,<sup>14)</sup> seminoma,<sup>15)</sup> and nasopharyngeal carcinoma.<sup>16)</sup> The histologic appearance of the tumor associated with such a vigorous reaction in Case 2 resembled those of dysgerminoma or seminoma, and the tumor cells were revealed to have intracytoplasmic glycogen granules like the cases of seminoma reported by Richter et al.<sup>15)</sup> In Case 2, NCEG were scattered around the primary tumor in addition to the extensive infiltration of epithelioid cells within the tumor tissue, suggesting that the NCEG and the vigorous epithelioid cell infiltration may share a common histogenesis. This suggestion is further supported by immunohistochemical evidence that the epithelioid cells and giant cells composing the NCEG and those infiltrating the tumor tissue had the common markers of a histocyte: lysozyme-positive but S-100- $\beta$ -negative. Thus, the epithelioid cell infiltration inside the tumor is considered a histologic variant of the NCEG.

Recently, granulomatous reactions against malignant tumors have been considered as a T-cell mediated immune response to an antigen expression of the carcinoma acting as the local trigger.<sup>13,17,18)</sup> On the other hand, it has been well known that patients with sarcoidosis frequently manifest some immunological abnormalities: a negative skin test for PPD suggesting T-cell anergy, and hypergammaglobulinemia implying B-cell hyperfunction.<sup>19)</sup> Either or both immunological abnormalities developed in all but one of the cases of the present series (Table 1). The malignant tumor-associated granulomatous reactions may

share not only identical histologic features but also common immune alterations with sarcoidosis, particularly in case of the extensive evolution of the epithelioid cell granulomatous changes.

Interestingly, the granulomatous reactions were more markedly manifested in the regional lymph nodes than those in the primary tumor in the present series, suggesting that the granulomatous changes tend to be enhanced at the lymph nodes. Moreover, NCEG associated with malignant tumors have been reported to develop in distant lymph nodes not regarded as regional, the spleen, and the liver.<sup>2,17,21)</sup> Such a wide distribution of NCEG was confirmed in our cases. These organs are regarded as inherent territories of lysozyme-positive and S-100-negative histiocytes.<sup>22)</sup> Thus, the granulomatous reactions against the malignant tumors may be a paraneoplastic change mostly developing in the lymphoid organs of the body, although these reactions may rarely develop within the tumor tissue.

In summary, the epithelioid cell granulomatous changes arising in patients with a malignant tumor are considered one of the morphological manifestations of the host immune response to the cancer tissue, most likely developing in the organs belonging to the reticuloendothelial system of the body. The extensive manifestation of such changes may be related to the same immune alterations as those developing in sarcoidosis.

## REFERENCES

- 1) Gregorie HB, Othersen HB, Moore MP: The significance of sarcoid-like lesions in association with malignant neoplasms. *Am J Surg* 104: 577-586, 1962.
- 2) Brincker H: Sarcoid reactions in malignant tumors. *Cancer Treat Rev* 13: 147-156, 1986.
- 3) Brincker H: Sarcoid reactions and sarcoidosis in Hodgkin's disease and other malignant lymphomata. *Br J Cancer* 26: 120-128, 1972.
- 4) Sternberger LA, Hardy PH, Cuculis JJ, Meyer HG: The unlabeled antibody enzyme method of immunocytochemistry. Preparation and properties of soluble antigen-antibody complex (horseradish peroxidase-antihorseradish peroxidase) and its use in identification of spirochetes. *J Histochem Cytochem* 18: 315-333, 1970.
- 5) Guesdon JL, Ternynck T, Avrameas S: The use of avidin-biotin interaction in immunoenzymatic techniques. *J Histochem Cytochem* 27: 1131-1139, 1979.
- 6) Watanabe Y, Iwa T: Clinical value of immunotherapy for lung cancer by the streptococcal preparation OK 432. *Cancer* 53: 248-253, 1984.

- 7) Fahimi HD, Deren JJ, Gottlieb LS, Zamcheck N: Isolated granulomatous gastritis: its relationship to disseminated sarcoidosis and regional enteritis. *Gastroenterology* **45**: 161-175, 1963.
- 8) Savoca PE, Ballantyne GH, Cahow CE: Gastrointestinal malignancies in Crohn's disease: a 20-year experience. *Dis Colon Rectum* **33**: 7-11, 1990.
- 9) Koppe P, Kuhne-Heid R, Krause U: Sarcoidosis involvement and adenocarcinoma of the stomach. *Dtsch Z Verdau Stoffwechselkr* **45**: 261-268, 1985.
- 10) LLombart A, Escudero M: The incidence and significance of epithelioid and sarcoid-like cellular reaction in the stroma of malignant tumors. A morphological and experimental study. *Europ J Cancer* **6**: 545-551, 1970.
- 11) Sato N, Matsubayashi F: A case of local sarcoid of the stomach coexisting with carcinoma of the stomach. *Stomach and Intestine* **6**: 917-925, 1971. (in Japanese with English abstract)
- 12) Mizoguchi O, Akasaka K, Kojima S, Hanyu H, Kawasaki T, Hoshi K, Murakami T, Taniiai T, Aoki N: A case report of widespread gastric sarcoid coexisting with early gastric cancer. *Stomach and Intestine* **10**: 1325-1330, 1975. (in Japanese with English abstract)
- 13) Adams DO, Hamilton TA: The activated macrophage and granulomatous inflammation. *Curr Top Pathol* **79**: 151-167, 1989.
- 14) Sailer S: Ovarian dysgerminoma. *Am J Cancer* **38**: 473-482, 1940.
- 15) Richter HJ, Leder LD: Lymph node metastases with PAS-positive tumor cells and massive epithelioid granulomatous reaction as diagnostic clue to occult seminoma. *Cancer* **44**: 245-249, 1979.
- 16) Wockel W, Wernert N: Excessive epithelioid cell granulomatous reaction associated with a lympho-epithelial carcinoma (Schmincke-Regaud). *Path Res Pract* **181**: 349-352, 1986.
- 17) Bassler R, Birke F: Histopathology of tumor associated sarcoid-like stromal reaction in breast cancer: an analysis of 5 cases with immunohistochemical investigations. *Virchows Arch [A]* **412**: 231-239, 1988.
- 18) Falk S, Takeshita M, Stutte HJ: Epithelioid granulomatosis with initial and predominant manifestation in the spleen: morphological and immunohistochemical analysis of six cases. *Virchows Arch [A]* **414**: 69-76, 1988.
- 19) Friedman R, Ackerman M, Mallory G, Weng TR, Fireman P: Hypogammaglobulinemia with sarcoid-like granulomas. *Am J Dis Child* **137**: 774-776, 1983.
- 20) Braylan RC, Long JC, Jaffe ES, Greco FA, Orr SL, Beraad CW: Malignant lymphoma obscured by concomitant extensive epithelioid granulomas: Report of three cases with similar clinicopathologic features. *Cancer* **39**: 1146-1155, 1977.
- 21) Liberati AM, Puxeddu A, Allegra A, Bisconttini B, Curzi N, Andreani P, Cristallini E, Grignani F: Generalized sarcoid-type reaction associated with non-Hodg kin's lymphoma. *Haematologica* **71**: 225-228, 1986.
- 22) Watanabe S: *Lymph Node Biopsy*. Bunkoudou, Tokyo. pp 176-181, 1985. (in Japanese)