

Barrett's Esophagus Associated with Mucoepidermoid Carcinoma Arising in the Esophageal Squamous Epithelium

Tadashi NISHIMAKI, Otsuo TANAKA, Tsutomu SUZUKI, Kikuo AIZAWA, Kazuo WATANABE, Satoru NAKAGAWA, Katsuyoshi HATAKEYAMA and Hidenobu WATANABE*

The First Department of Surgery and *The First Department of Pathology, Niigata University School of Medicine, Niigata, Japan

Received July 17 1995; accepted November 6 1995

Summary. A 56-year-old male patient underwent neoadjuvant chemotherapy with cisplatin, 5-fluorouracil, and leucovorin for a constricting esophageal carcinoma with extensive lymph node metastases. A Columnar lower esophageal epithelium measuring 3.3 cm in length was observed to be distinct from the esophageal tumor at endoscopy on the 29th day following the initiation of chemotherapy. The patient underwent palliative esophagectomy following three cycles of neoadjuvant chemotherapy. The resected specimen revealed a concomitant mucoepidermoid carcinoma of the esophagus and Barrett's esophagus (BE) characterized by columnar epithelium with intestinal metaplasia. The clinicopathologic details of this rare association of Barrett's metaplasia with esophageal mucoepidermoid carcinoma are presented, the possible genesis of Barrett's esophagus in relation to the development of mucoepidermoid carcinoma is discussed, and the literature is reviewed.

Key words—Barrett's esophagus, mucoepidermoid carcinoma, chemotherapy, esophageal neoplasms, pathology.

INTRODUCTION

Barrett's esophagus (BE) arises due to esophageal injury by the chronic reflux of gastric and duodenal contents, resulting in replacement of the esophageal squamous epithelium by metaplastic columnar epithelium.¹⁾ Several complications are known to result from BE, including ulceration, hemorrhage, stricture, and malignant transformation of the metaplastic

columnar mucosa.²⁾ Recent studies have revealed that patients with BE have a 30-fold to 350-fold increased risk of developing esophageal carcinoma.³⁾

The most common Barrett's carcinoma is adenocarcinoma, while squamous cell, adenosquamous, and mucoepidermoid carcinoma have rarely been reported to arise in BE.⁴⁻¹⁵⁾ In some of these reported cases,^{7,10,11,13,14)} the tumors had developed in the squamous-lined adjacent esophagus with or without simultaneous Barrett's adenocarcinoma, suggesting the presence of etiologic factors common to squamous cell carcinoma and Barrett's metaplasia.

We recently encountered a patient who had concomitant mucoepidermoid carcinoma of the thoracic esophagus and Barrett's epithelium in the lower esophagus. The present report describes the clinical and pathologic details of this rare association of BE with esophageal mucoepidermoid carcinoma, and discusses the possible genesis of Barrett's metaplasia. The literature is also reviewed.

CASE REPORT

A 56-year-old Japanese man was admitted to the First Department of Surgery of the Niigata University Hospital on December 25, 1992, with a chief complaint of progressive dysphagia which had been occurring for two months. He smoked two packs of cigarettes daily and had heavy alcohol intake for 43 years. There was no past history of gastroesophageal reflux. The physical examination was normal except for a left supraclavicular lymphadenopathy measuring 4 × 4 cm in size. Routine laboratory data were nor-

Correspondence: Tadashi Nishimaki, M.D., The First Department of Surgery, Niigata University School of Medicine, Asahimachi-dori 1-757, Niigata 951, Japan.

mal except for slightly elevated serum lactate dehydrogenase (755 IU/L), alkaline phosphatase (309 IU/L), and gamma-glutamyl transpeptidase (90 IU/L). The carcinoembryonic antigen (CEA) serum level was elevated to 16.0 ng/ml (normal: <6 ng/ml) while other tumor markers such as alpha-fetoprotein (AFP), carbohydrate antigen 19-9 (CA 19-9), and squamous cell carcinoma-related antigen (SCC) were within normal limits. A barium swallow study revealed an irregular stricture of the middle and lower esophagus, measuring 13 cm in length (Fig. 1A). Esophageal endoscopy revealed stenosis at 32 cm from the upper incisors, obstructing passage of the endoscope through the lesion. Endoscopic biopsy showed a poorly differentiated squamous cell carcinoma. Computed tomography (CT) revealed a circular thickening of the middle and lower esophageal wall with multiple enlarged lymph nodes, including the left supraclavicular, right paratracheal, paracardial, perigastric, celiac artery, and abdominal paraaortic nodes.

The patient received three cycles of intravenous multidrug neoadjuvant combination chemotherapy consisting of cisplatin (100 mg/m² on day 1), 5-fluorouracil (700 mg/m² on days 1-5), and leucovorin calcium (20 mg/m² on days 1-5). The chemotherapy was complicated by emesis, mucositis, and a genital ulcer. Esophageal endoscopy performed following the second cycle of chemotherapy (on the 29th day following the initiation of chemotherapy) revealed an improvement of the esophageal stenosis such that the endoscope could be passed into the stomach. The squamocolumnar epithelial junction was clearly identified with topical Lugol solution, and was located at the distal margin of the tumor. The esophagogastric muscular junction was located 2 to 3 cm distal to the epithelial junction. The esophageal mucosa between the squamocolumnar epithelial junction and the esophagogastric muscular junction had a salmon-pink velvet-like appearance, consisting with Barrett's esophagitis. A small hiatal hernia was also observed during endoscopy. A barium swallow study following the third cycle of chemotherapy showed a further improvement of the esophageal stricture (Fig. 1B).

The patient underwent palliative transhiatal esophagectomy on April 8, 1993, with concomitant cervical esophagogastrostomy for reconstruction.

The postoperative course was uncomplicated. Two additional cycles of multidrug combination chemotherapy were administered, resulting in the confirmed resolution of the left supraclavicular lymphadenopathy on physical examination. In addition, there was no evidence of adenopathy in the neck, mediastinum, or abdomen by CT. The patient was discharged on June 17, 1993. The patient survives with no evidence of

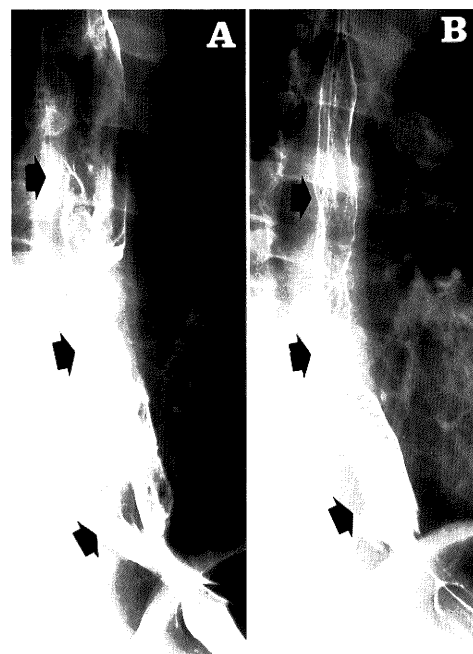


Fig. 1. A. Esophagogram prior to neoadjuvant chemotherapy showing an irregular stricture of the middle and lower esophagus. B. Esophagogram following neoadjuvant chemotherapy. Arrow heads indicate the extent of the tumor.

recurrent disease on routine follow-up.

Pathology

The resected specimen consisted of the esophagus measuring 22 cm in length and the proximal part of the stomach measuring 11 cm in length. A thickening of the esophageal wall measuring 13.0 × 5.2 cm was noted in the mid- and lower esophagus, with most of the tumor covered by normal squamous epithelia. The tumor center was located 7.7 cm proximal to the esophagogastric junction, and the distal end of the tumor was just beneath the squamocolumnar epithelial junction located 3.3 cm proximal to the esophagogastric junction. The squamocolumnar epithelial junction was irregular in shape and was accompanied by numerous tiny squamous or columnar islands in the adjacent esophagus (Fig. 2A, B).

The formalin-fixed specimen was examined by full-step sections. Histologically, the esophageal tumor showed a poorly differentiated squamous cell carcinoma infiltrating down to the adventitia through the muscularis propria (Fig. 3). A mixture of squamous cells and tumor cells with intracellular mucin secretion was found in the tumor tissue, particularly in the lamina propria mucosae and submucosa (Fig.

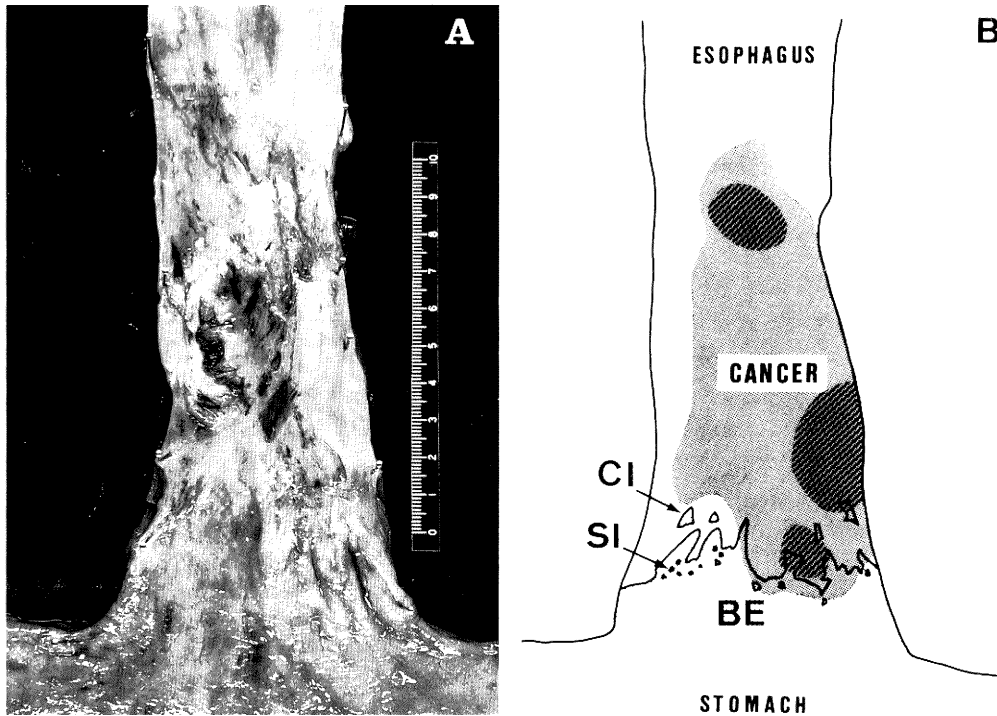


Fig. 2. A. Esophagectomy specimen stretched on a board, showing a tumor mostly covered with normal squamous epithelium in the lower half of the thoracic esophagus. Note the columnar-lined lower esophagus (Barrett's esophagus) distal to the tumor. B. Diagram of the lesions. The darker area represents the histologic extent of the tumor. The cross-hatched area shows the distribution of tumor cells with intracellular mucin secretion. The lighter shaded area represents the esophagus lined by metaplastic columnar epithelium. BE, Barrett's esophagus; CI, columnar islands; SI, squamous islands.

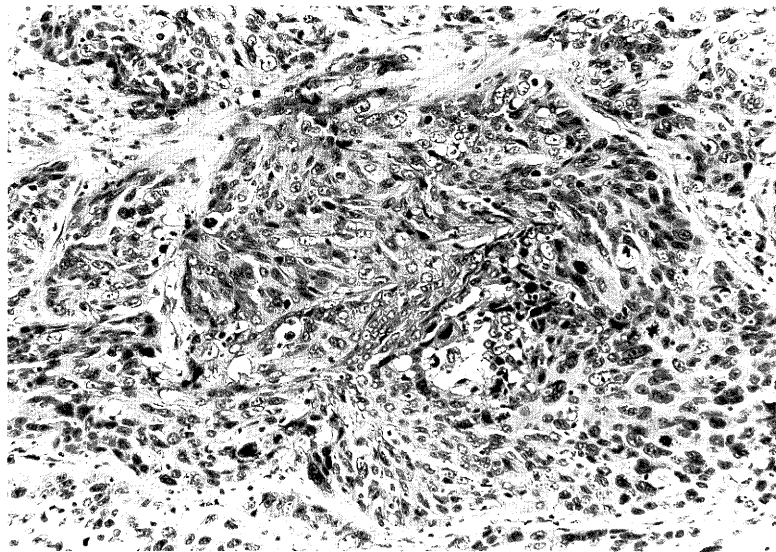


Fig. 3. Tumor specimen showing a poorly differentiated squamous cell carcinoma. Hematoxylin and eosin, $\times 24$

4). Intracellular mucin was detected by both periodic acid-Schiff (PAS) and alcian blue at pH 2.5. Tumor cells with intracellular mucin secretion were also present in the metastatic tumors up to the regional lymph nodes simultaneously resected. Although the tumor was largely covered with normal squamous epithelia, there were several foci of intraepithelial squamous cell carcinoma. The final pathologic diagnosis of the tumor was mucoepidermoid carcinoma of the thoracic esophagus.

The esophageal mucosa between the squamocolumnar epithelial junction and the esophagogastric muscular junction was composed of columnar epithelia with goblet and mucous-secreting cells resembling intestinal absorptive cells (Fig. 5). The esophageal mucosa adjacent to the esophagogastric junction appeared similar to the cardiac mucosa of the stomach. Esophageal glands were diffusely distributed in the submucosa of the columnar-lined lower esophagus. No dysplasia or carcinoma were found in this




Fig. 4. Tumor cells with intracellular mucin secretion (arrows) intermingled with squamous cell carcinoma. Hematoxylin and eosin, $\times 48$

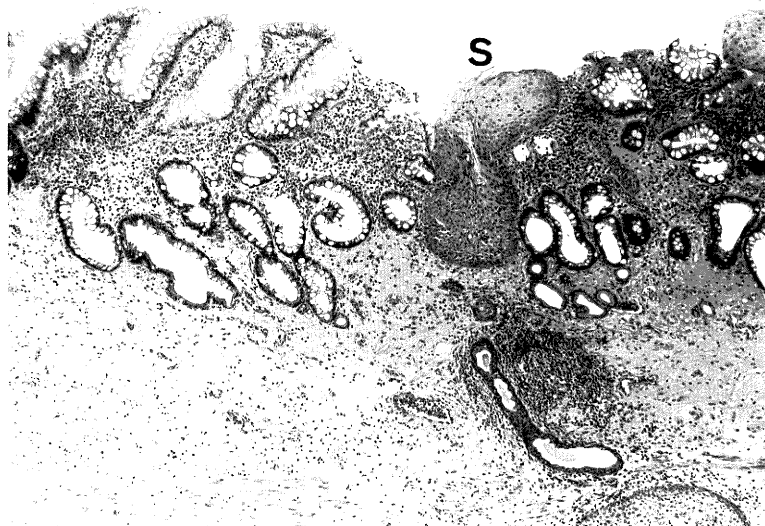


Fig. 5. Barrett's mucosa with intestinal metaplasia. S indicates squamous remnants. Hematoxylin and eosin, $\times 10$

columnar-lined lower esophagus. The gastric mucosa of the resected stomach appeared normal with no evidence of atrophic gastritis.

DISCUSSION

The majority of carcinomas arising in BE are adenocarcinomas. Kikuchi et al. have reported that more than 95% of 532 Barrett's malignancies reported so far have been adenocarcinomas.¹⁵⁾ However, esophageal carcinoma with squamous differentiation has also been reported to be associated with BE. Table 1 summarizes a review of 20 cases of such an association reported in the literature. Clinicopathologic char-

acteristics of esophageal carcinoma with squamous differentiation arising above or within BE seem to be similar to those of adenocarcinoma occurring within the BE. The patients are predominantly adult males, and most have hiatal hernias with or without reflux-related symptoms. In addition, intestinal type columnar epithelium is the most common histologic type of associated Barrett's mucosa. The lower esophageal metaplastic columnar epithelium also has a neoplastic potential in these patients since dysplasia or adenocarcinoma were concurrently present within the BE in some instances (Table 1).

BE has generally been considered to develop primarily as a consequence of long-standing gastroesophageal reflux.¹⁾ However, Dahms et al. have report-

Table 1. Summary of previously reported cases of esophageal carcinoma showing squamous differentiation associated with Barrett's esophagus

Case No.	Age	Sex	History ^{a)} of GERD	Hiatal hernia	Tumor			Barrett's esophagus			Reference No.
					Histology ^{b)}	Depth ^{c)}	Location ^{d)}	Length (cm)	Type of ^{e)} Barrett's mucosa	Concurrent neoplastic changes	
1	61	M	—	+	SCC	?	?	?	Gastric	?	(4)
2	53	M	—	+	SCC	A	CLE	11.5	J	—	(5)
3	51	M	+	+	SCC	SM	CLE	?	?	?	(6)
4	54	F	?	?	SCC	A	SLE	?	?	?	(7)
5	60	M	?	?	SCC	A	SLE	?	?	?	
6	47	M	?	?	SCC	?	CLE	?	?	Adenocarcinoma	(8)
7	50	M	?	?	ASC	A	CLE	?	?	?	
8	59	M	+	+	SCC	M, SM	CLE	14.0	I	—	(9)
9	62	M	—	—	SCC	SM	SLE	?	?	Adenocarcinoma	(10)
10	65	M	—	+	SCC	SM	SLE	8.0	I, J, F	Adenocarcinoma	(11)
11	63	M	+	+	MEC	A	CLE	?	I, J	—	(12)
12	64	M	—	?	SCC	A	SLE	>6	I	Dysplasia	(13)
13	73	M	—	?	SCC	A	SLE	3	I	Dysplasia	
14	80	M	—	?	SCC	MP	SLE	>3	I	—	
15	54	M	—	+	SCC	A	CLE	6.0	I, J	—	(14)
16	56	F	—	+	SCC	A	CLE	9.0	I, J	Dysplasia	
17	43	F	—	+	SCC	MP	CLE	8.0	I, J	Dysplasia	
18	79	M	—	+	SCC	SM	SLE	4.0	I, J, F	—	
19	57	M	+	+	SCC	A	SLE	4.0	I, J	Dysplasia	
20	42	M	—	+	ASC	A	CLE	7.0	I, J, F	Adenocarcinoma	(15)
21	56	M	—	+	MEC	A	SLE	3.3	I, J	—	present case

^{a)} GERD, Gastroesophageal reflux diseases; ^{b)} SCC, Squamous cell carcinoma; ASC, Adenosquamous carcinoma; MEC, Mucoepidermoid carcinoma, ^{c)} M, Mucosa; SM, Submucosa; MP, Muscularis propria; A, Adventitia, ^{d)} CLE, Columnar-lined esophagus; SLE, Squamous-lined esophagus, ^{e)} I, Intestinal type; J, Junctional type; F, Fundic type.

ed three cases of BE occurring following antileukemia chemotherapy, suggesting that BE could also occur as a result of chemotherapy-induced esophageal mucosal injury.¹⁶⁾ Sartori et al. have further demonstrated the development of BE following multidrug combination chemotherapy in a prospective study of patients with breast carcinoma.¹⁷⁾ However, more recent studies have failed to confirm the development of such "iatrogenic" BE.¹⁸⁾

In the patient presented here, BE was noted following the second cycle of neoadjuvant chemotherapy. Cisplatin is well known to be very cytotoxic, and leucovorin can potentiate the gastrointestinal toxicity of 5-fluorouracil.¹⁹⁾ Furthermore, cisplatin often causes severe emesis during chemotherapy. The patient reported here did indeed suffer from severe mucositis and vomiting during chemotherapy. Although the possibility cannot be totally denied that the BE in our patient occurred as a result of direct injury by the chemotherapy to the lower esophageal squamous epithelium in combination with the emetic action of these drugs, it is more likely that the BE had been primarily present before the chemotherapy because the interval between the initiation of chemotherapy and endoscopic detection is considered too short (29 days) for the emergence of mature metaplastic columnar epithelium, considering the time period needed for immature regenerating epithelia of the gastric mucosa to grow to a normal mucosa in cases of peptic ulcer of the stomach.²⁰⁾

Asymptomatic gastroesophageal reflux has frequently been reported to occur in patients with BE.²⁾ Although the patient described here denied a previous history of gastroesophageal reflux disease, his hiatal hernia may have promoted the reflux. In addition, the irregular and complicated appearance of the squamocolumnar epithelial junction, accompanied by numerous squamous or columnar islands, indicates chronic injury to the lower esophageal squamous epithelia. These findings support the idea that the patient may have had pre-existing BE.

The relationship between the development of esophageal mucoepidermoid carcinoma and BE remains unclear. Tobacco and alcohol may be predisposing factors for both this type of esophageal tumor and BE, as with esophageal squamous cell carcinoma²¹⁾ and BE.²²⁾ The patient reported here had a history of heavy smoking and alcohol ingestion. However, the simultaneous occurrence of esophageal mucoepidermoid carcinoma and Barrett's metaplasia is likely due to chance, in view of the rarity of this concurrence in the literature.

Finally, careful endoscopic examination with topical Lugol solution of the esophageal squamous epithe-

lium proximal to BE may be important for the endoscopic follow-up of patients with BE, in order to prevent the overlooking of early neoplastic changes above the BE. In addition, esophageal endoscopy should be carried out in patients following multiple cycles of chemotherapy in order to rule out possible iatrogenic Barrett's metaplasia.

REFERENCES

- 1) Hassall E: Barrett's esophagus: congenital or acquired? *Am J Gastroenterol* **88**: 819-824, 1993.
- 2) Streitz JM Jr, Williamson WA, Ellis FH Jr: Current concepts concerning the nature and treatment of Barrett's esophagus and its complications. *Ann Thorac Surg* **54**: 586-591, 1992.
- 3) Tytgat GNJ, Hameeteman W: The neoplastic potential of columnar-lined (Barrett's) esophagus. *World J Surg* **16**: 308-312, 1992.
- 4) Shine I, Allison PR: Carcinoma of the oesophagus with tylosis (keratosis palmaris et plantaris). *Lancet* **1**: 951-953, 1966.
- 5) Tamura H, Schulman SA: Barrett-type esophagus associated with squamous carcinoma. *Chest* **59**: 330-333, 1971.
- 6) Burke EL, Sturm J, Williamson D: The diagnosis of microscopic carcinoma of the esophagus. *Am J Dig Dis* **23**: 148-151, 1978.
- 7) Bremner CG: Benign strictures of the esophagus. *Curr Probl Surg* **19**: 402-489, 1982.
- 8) Smith RRL, Boitnott JK, Hamilton SR, Rogers EL: The spectrum of carcinoma arising in Barrett's esophagus. A clinicopathologic study of 26 patients. *Am J Surg Pathol* **8**: 563-573, 1984.
- 9) Resano CH, Cabrera N, Cueto G, Basso S, Rubio HH: Double early epidermoid carcinoma of the esophagus in columnar epithelium. *Endoscopy* **17**: 73-75, 1985.
- 10) Sheahan DG, Berman MA: Barrett's mucosa with multiple carcinomas of the esophagus and oral cavity. *J Clin Gastroenterol* **8**: 103-107, 1986.
- 11) Allan NK, Weitzner S, Scott L, Khalil KG: Adenocarcinoma arising in Barrett's esophagus with synchronous squamous cell carcinoma of the esophagus. *South Med J* **79**: 1036-1039, 1986.
- 12) Pascal RP, Clearfield HR: Mucoepidermoid (adenosquamous) carcinoma arising in Barrett's esophagus. *Dig Dis Sci* **32**: 428-432, 1987.
- 13) Rosengard AM, Hamilton SR: Squamous carcinoma of the esophagus in patients with Barrett's esophagus. *Mod Pathol* **2**: 2-7, 1989.
- 14) Paraf F, Flejou JF, Potet F, Molas G, Fekete F: Esophageal squamous carcinoma in five patients with Barrett's esophagus. *Am J Gastroenterol* **87**: 746-750, 1992.
- 15) Kikuchi M, Mizuta M, Uno H, Yokoyama I, Yokoyama Y, Kondo K: A case of double lesions of

- adenosquamous carcinoma and adenocarcinoma arising from Barrett's esophagus. *Gastroenterol Endosc* **35**: 2159-2165, 1993.
- 16) Dahms BB, Greco MA, Strandjord SE, Rothstein FC: Barrett's esophagus in three children after antileukemia chemotherapy. *Cancer* **60**: 2896-2900, 1987.
 - 17) Sartori S, Nielsen I, Indelli M, Trevisani L, Pazzi P, Grandi E: Barrett's esophagus after chemotherapy with cyclophosphamide, methotrexate, and 5-fluorouracil (CMF): an iatrogenic injury? *Ann Intern Med* **114**: 210-211, 1991.
 - 18) Peters FTM, Sleijfer DT, van Imhoff GW, Kleibeuker JH: Is chemotherapy associated with development of Barrett's esophagus? *Dig Dis Sci* **38**: 923-926, 1993.
 - 19) Machover D, Goldschmidt E, Chollet P, Metzger G, Zittoun J, Marquet J, Vandenbulcke J-M, Misset J-L, Schwarzenberg L, Fourtillan JB, Gaget H, Mathe G: Treatment of advanced colorectal and gastric adenocarcinomas with 5-fluorouracil and high-dose folinic acid. *J Clin Oncol* **4**: 685-696, 1986.
 - 20) Nishimaki T, Watanabe H, Muto T: Chronological evaluation of histologic changes in the healing of benign gastric ulcers: morphologic indicators of the age of the ulcer. *Acta Med Biol* **40**: 165-170, 1992.
 - 21) Yu Mc, Garabrant DH, Peters JM, Mack TM: Tobacco, alcohol, diet, occupation, and carcinoma of the esophagus. *Cancer Res* **48**: 3843-3848, 1988.
 - 22) Menke-Pluymers MBE, Hop WC, Dees J, van Blankestein M, Tilanus HW: Risk factors for the development of an adenocarcinoma in columnar-lined (Barrett's) esophagus. *Cancer* **72**: 1155-1158, 1993.