

# An Immunohistological and *in Situ* Hybridization Study of Arsenical Keratosis

Hiroshi FUJIWARA, Toshio TAZAWA, Ayako YAMAMOTO and Masaaki ITO

Department of Dermatology, Niigata University School of Medicine, Niigata, Japan

Received June 23 1995; accepted November 28 1995

**Summary.** Arsenical keratosis (AK) is a common early sign of chronic arsenicism. The association between arsenicism and Bowen's disease is well documented, but a definitive understanding of the relation between AK and Bowen's disease remains elusive. In this study, eight cases of AK were examined immunohistologically with antibodies for cytokeratins, epidermal growth factor receptor, erbB2 protein, c-myc protein, and ki-67. An *in situ* hybridization study for c-myc, v-erb-B, and erbB2 mRNA was also performed. Bowen's disease (16 cases) and normal skin (3 cases) of arsenic ingesters, and Bowen's disease (15 cases) and seborrheic keratosis (15 cases) without arsenic exposure served as controls. AK revealed a similar reaction to Bowen's disease, with characteristic positive cells for ki-67 antigen and c-myc mRNA in the suprabasal layers. These findings demonstrate a close relationship between AK and Bowen's disease.

**Key words**—arsenic, arsenical keratosis, Bowen's disease.

## INTRODUCTION

Exposure to inorganic arsenic is not uncommon; formerly, arsenic was often used for the treatment of dermatological conditions, e.g., syphilis and psoriasis, and in insecticides. Arsenic poisoning in food or well water is occasionally reported. Chronic arsenicism is related to neoplasms in the skin, the gastrointestinal tract, the genito-urinary tract, the respiratory tract, and the soft tissue.<sup>1-6</sup> The skin is the most commonly affected organ. Hyperpigmentation and arsenical keratosis (AK) are frequently observed; basal cell carcinoma, Bowen's disease (squamous cell carcinoma *in situ*), or invasive squamous cell carcinoma can develop multi-

ply.<sup>1,4,7</sup> AK are usually punctate firm papules of less than 10 mm in diameter, observed predominantly on the palms and soles, although they may appear on any part of the body.<sup>7</sup> Bowen's disease or squamous cell carcinoma may evolve from AK. In this communication immunohistological and *in situ* hybridization studies were performed to reveal the characteristics of AK, for the first time to our knowledge, and subsequently compared with other common skin tumors.

## MATERIALS AND METHODS

### Subjects

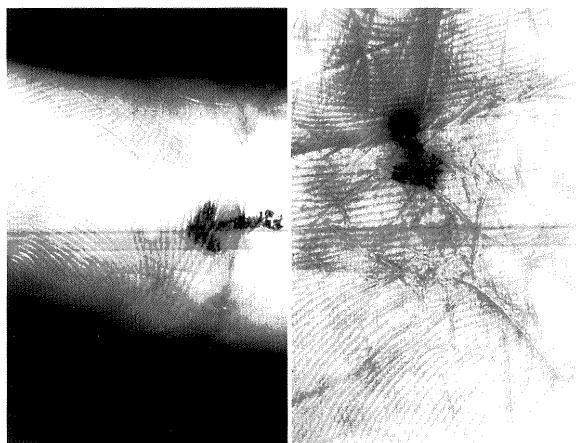
All the patients of chronic arsenicism in this study were officially registered as such in Niigata Prefecture based on their arsenic ingestion history and symptoms. They were residents of the Nakajo district who had ingested arsenically poisoned well water between 1955 and 1960. Among the 669 residents examined, AK (Fig. 1) was found in 50 subjects, and Bowen's disease in 20. Two female patients also developed invasive squamous cell carcinoma of the skin. None of them had a history of malignancy of the internal organs. The lesions were removed from 15 males and 12 females, between 31 and 81 years of age (mean 61.2 years). The non-ingesters were without a history of exposure to arsenic, and did not live anywhere near the Nakajo district.

Skin lesions were surgically removed, and a part of them was subjected to routine histopathology. AK (8 cases), Bowen's disease, (16 cases) and normal skin (3 cases) of arsenic ingesters were obtained. Bowen's disease (15 cases, 43-79 years of age, mean 66.1 years), and seborrheic keratosis, (15 cases, 28-80 years of age, mean 63.3 years), and five normal skin biopsies of non-ingesters served as controls.

Correspondence: Hiroshi Fujiwara, MD, PhD; Department of Dermatology, Niigata University School of Medicine, Asahimachidori 1, Niigata 951, Japan.

## Methods

**Immunohistochemistry:** The remaining samples were snap-frozen in liquid nitrogen, cut in 5 micrometer sections, acetone-fixed, and incubated with the following monoclonal antibodies for 30 min at room temperature. Mo-1, HKN-2, HKN-4, HKN-5,<sup>8,9)</sup> and K-92 (Dako Co., SantaBarbara, CA, USA) are the anti-keratin monoclonal antibodies of characteristic immunoreactivity (Table 1). Anti-epidermal growth factor receptor (EGFR, Oncogene Science, Inc., Manhasset, NY, USA), anti-erbB2 protein (Oncogene Science, Inc.), anti-c-myc protein (Oncogene Science, Inc.), and Ki-67 (Dako) were also used. Fluorescein isothiocyanate-conjugated anti-mouse IgG (Cappel Lab., West Chester, PA, USA) served as a second antibody for the keratin stain. An Alkaline phosphatase anti-alkaline phosphatase (APAAP) method was performed for anti-EGFR, anti-erbB2 protein, anti-c-myc protein, and



**Fig. 1.** Clinical pictures of arsenical keratosis. Arrows indicate typical pitted keratotic lesions on palms.

Ki-67,<sup>10)</sup> and visualized with Fast Blue RR salt.<sup>9)</sup>

**In situ hybridization:** Messenger RNA expression of proliferation-associated proteins was examined with *in situ* hybridization on formalin-fixed, paraffin-embedded sections.<sup>11)</sup> In brief, the sections were deparaffinized, acid-treated, digested with proteinase K, and incubated with a prehybridization solution of 40% formamide/2X SSC. Hybridization with biotinylated probes for v-erbB, erbB2, or c-myc was carried out at 50°C overnight; the slides were washed under stringent conditions, incubated with anti-biotin antibody and stained by the APAAP method.

## RESULTS

Histologies of AK and Bowen's disease in arsenicism patients are shown in Fig. 2. In AK, mild acanthosis of the spinous layers, which focally lacked polarity, was observed, but atypical cells were usually absent. Bowen's disease, either in arsenicism or in non-arsenicism patients, showed characteristic structural and cellular atypism. The normal-appearing skin of arsenic ingesters appeared structurally and cellularly normal.

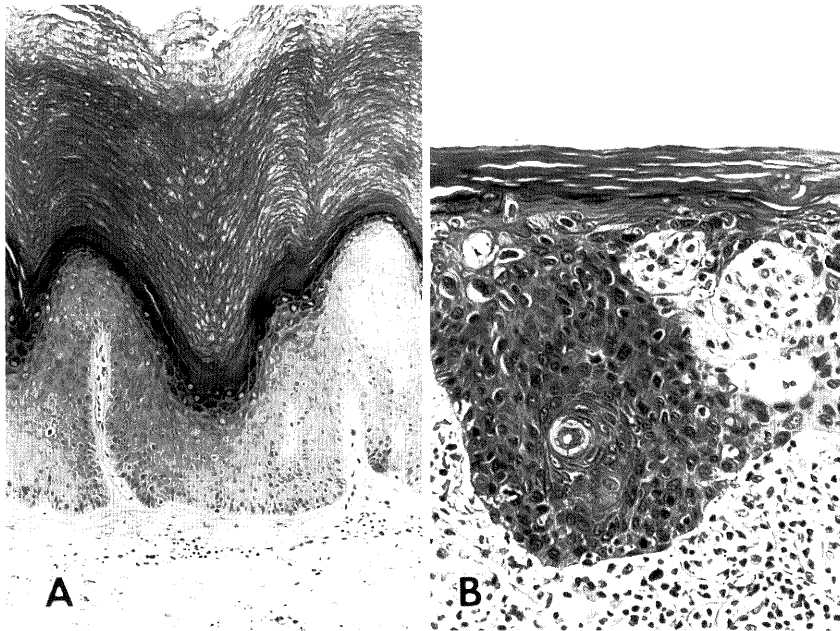
Immunohistologically, keratin staining disclosed the same pattern in AK and Bowen's disease of either arsenic ingesters or non-ingesters. Basal keratin (ck5), although partially interrupted, was stained with Mo-1 in the basal layers, and a suprabasal pattern with HKN-2 and K-92 was maintained. In seborrheic keratosis, the most common keratotic lesion, Mo-1-positive cells were absent in the basal layers (Fig. 3). Immunoreactive EGFR was observed in the basal layer of normal skin and in all the tumor cells of keratotic lesions. Cycling cells stained with ki-67 in suprabasal layers were found in AK and Bowen's

**Table 1.** Specificity of antibodies

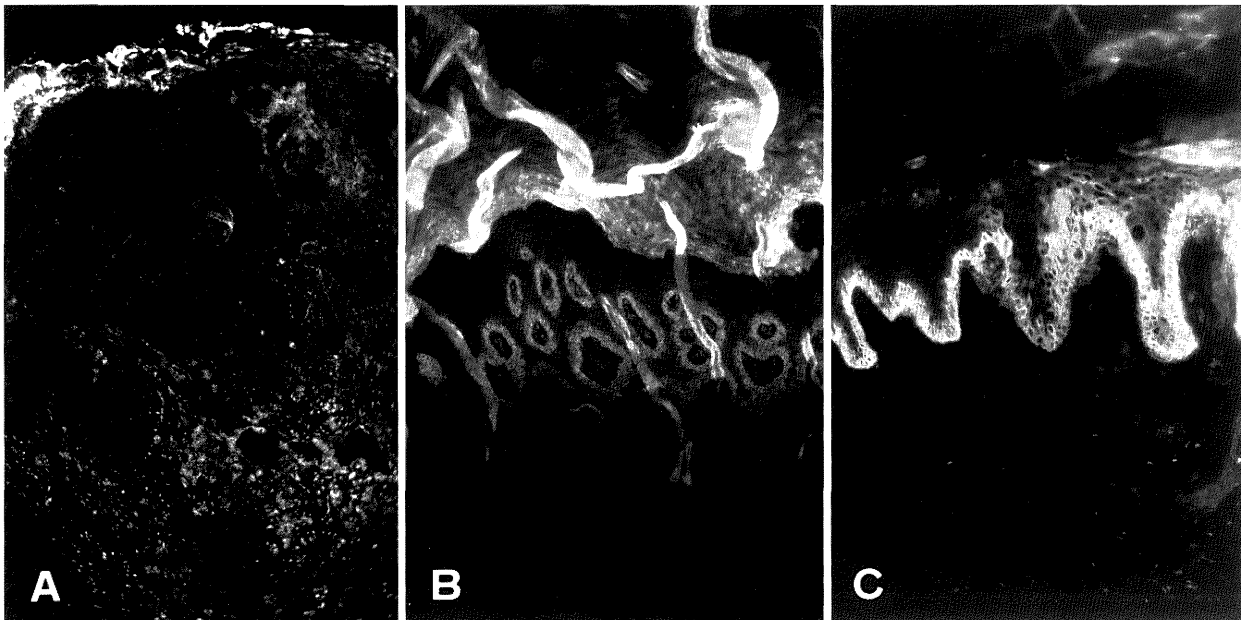
Antibody	Antigen	Reactivity in normal skin
Mo-1	CK5	basal layer
HKN-2	CK10, etc.	suprabasal layers
HKN-4	pan cytokeratin	whole epidermis
HKN-5	keratins, undetermined*	outer root sheath of the hair
K-92	CK10	suprabasal layers
anti-EGFR	EGFR	basal layer
anti-erbB2	erbB2 protein	sweat gland
Ki-67	proliferating cells	basal layer
anti-c-myc	c-myc protein	negative

EGFR, epidermal growth factor receptor;

\*, HKN-5 reacts with keratins of rapidly keratinizing cells in squamous cell carcinoma.



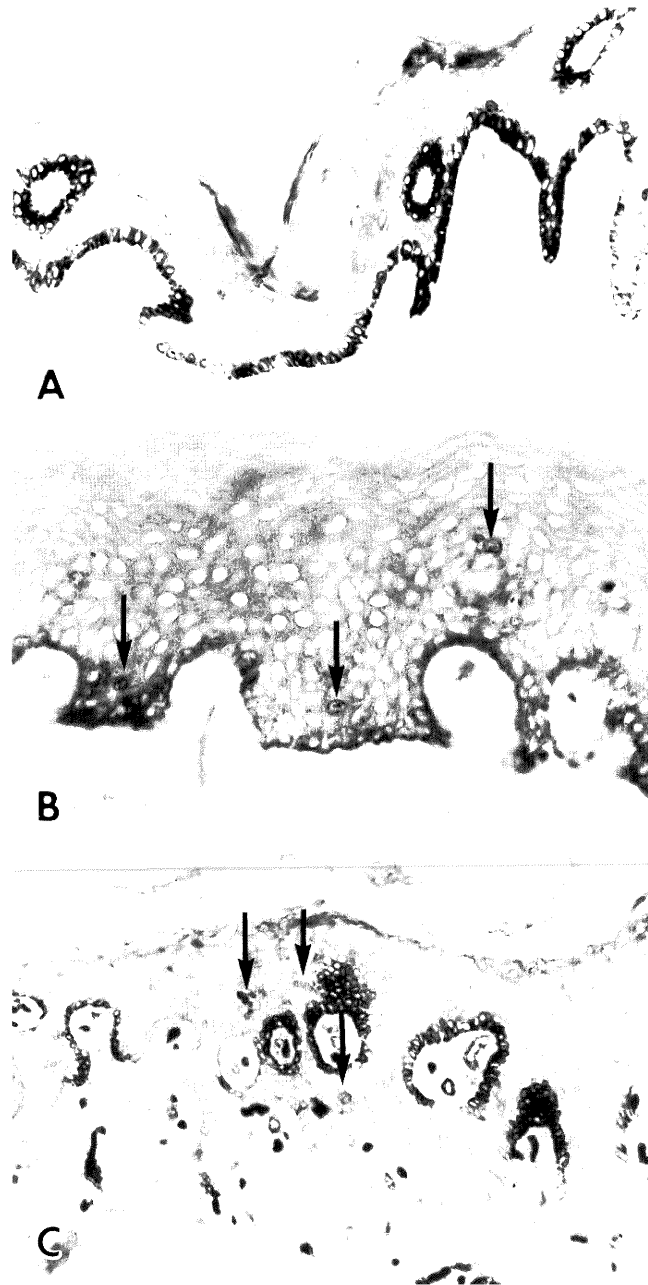
**Fig. 2.** Histology of **A.** Arsenical keratosis, and **B.** Bowen's disease in arsenicosis patient. Hematoxylin-eosin stain; A,  $\times 100$ ; B,  $\times 250$



**Fig. 3.** Keratin stain with Mo-1. **A.** Seborrheic keratosis; the basal layer pattern is absent. **B.** Arsenical keratosis. **C.** Bowen's disease; basal layers are positively stained. FITC stain,  $\times 95$

disease of either arsenic ingesters or non-ingesters (labeling index in suprabasal layers, mean  $\pm 2SD$ /three high power fields,  $34.9 \pm 23.6$ ,  $32.7 \pm 40.1$ ,  $34.3 \pm 31.4$ , respectively, differences for each group were not significant). In normal skin and seborrheic keratosis,

only the basal cells were positively stained with ki-67 (Fig. 4). ErbB2 or c-myc protein positive cells were not observed in any of the specimens. The immunoreactive patterns were the same in each tumor, e.g. Mo-1 was totally negative in any of the seborrheic

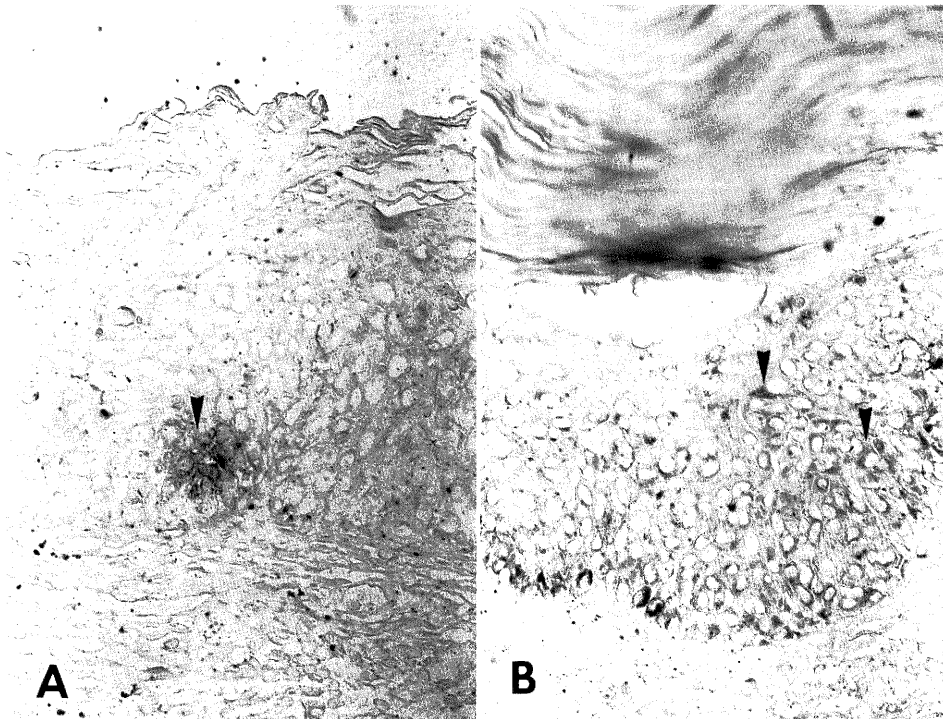


**Fig. 4.** Cycling cells immunoreactive with Ki-67. **A.** Seborrheic keratosis, positively stained cells are restricted in the basal layer. **B.** Arsenical keratosis, **C.** Bowen's disease; positive cells are scattered in the suprabasal layers as well as in the basal layers. (arrows) APAAP stain,  $\times 250$

keratosis samples, and are summarized in Table 2.

*In situ* hybridization disclosed erbB and myc mRNA expression in basal and suprabasal cells in AK and Bowen's disease of either arsenic ingesters or

non-ingesters. These mRNA expressions were limited to the basal cells in seborrheic keratosis. ErbB2 mRNA positive cells were not found in any of the tumors (Fig. 5, Table 3).



**Fig. 5.** *In situ* hybridization for c-myc mRNA. **A.** Arsenical keratosis, **B.** Bowen's disease; positive cells are observed in the suprabasal layers as well as in the basal layers. (arrow heads) APAAP stain,  $\times 200$

**Table 2.** Reactivity of antibodies to tissue samples

Antibody	Normal (A)	Arsenical keratosis	Seborrheic keratosis	Bowen's disease (A)	Bowen's disease (N)
Mo-1	B	B	—	B*	B*
HKN-2	S	S	S	S	S
HKN-4	W	W	W	W	W
HKN-5	—	—	—	—	—
K-92	S	S	S	S	S
anti-EGFR	B	W	W	W	W
anti-erbB2	—	—	—	—	—
Ki-67	B	B, S	B	B, S	B, S
anti-c-myc	—	—	—	—	—

B, basal layer; S, suprabasal layers; W, whole epidermis; —, negative; \*, partially positive; A, arsenicism; N, non-arsenicism.

**Table 3.** Result of *in situ* hybridization

Probe	Normal (A)	Arsenical keratosis	Seborrheic keratosis	Bowen's disease (A)	Bowen's disease (N)
v-erbB	B	B, S	B	B, S	B, S
erbB2	—	—	—	—	—
c-myc	—	B, S	B	B, S	B, S

B, basal layer; S, suprabasal layers; —, negative; A, arsenicism; N, non-arsenicism

## DISCUSSION

Inorganic arsenic is one of the simplest chemical agents to produce multiple neoplasms in human.<sup>4)</sup> Although AK is an early and important indicator of chronic arsenicism, literature on it has been scant and usually based on obscuration of a few cases. One textbook simply described AK as "indistinguishable from Bowen's disease".<sup>12)</sup> A study of a large series in Taiwan reported that most AK were easily differentiated from Bowen's disease, and in AK "only hyperkeratosis and acanthosis, without evidence of nuclear atypicity" was found,<sup>2)</sup> the same observation we had in our series. However, the immunohistochemical characteristics of AK were very similar, if not identical, to those of Bowen's disease. The cytokeratin expression indicated that AK is an intraepidermal epithelioma, like Bowen's disease, developed in suprabasal layers, and not the proliferation of basal cells like seborrheic keratosis. The scattered positive cells for ki-67 antigen, erbB mRNA and c-myc mRNA in the suprabasal layers suggested that tumor cells may proliferate above the basal layer. Therefore AK is an intraepidermal epithelioma with malignant potential, and is probably on the same spectrum of Bowen's disease.

Although the number of cases is still small, the normal skin in the present study in arsenic ingesters disclosed an unremarkable histology, immunohistology, and *in situ* hybridization reactivity. After absorption, arsenic binds to sulfhydryl groups in cells, and interferes with DNA polymerase activity. Therefore, the first damage is observed as scattered mitotic chromosomes in nuclei.<sup>13-15)</sup> It could be possible that alteration has already occurred in normal skin, but is undetectable with immunohistological and *in situ* hybridization techniques because of the low mitotic rate. To detect the earliest change, *in vitro* studies of keratinocyte culture and stimulation with mitogens may be required.

**Acknowledgments.** The authors thank Mr. Imai for his technical assistance and Mr. Nakakura and Ms. Muraki of Nakajo Town Office in the administrative work.

## REFERENCES

- 1) Lever WF, Schaumburg-Lever G: Arsenical keratosis and carcinoma. In: Lever WF, Schaumburg-Lever G (ed) *Histopathology of the skin*. (7th ed) J. B. Lippincott, Philadelphia 1990, p 293-294.
- 2) Yeh S: Skin cancer in chronic arsenicism. *Hum Pathol* **4**: 469-485, 1973.
- 3) Miki Y, Kawatsu T, Matsuda K, Machino H, Kubo K: Cutaneous and pulmonary cancers associated with Bowen's disease. *J Am Acad Dermatol* **6**: 26-31, 1982.
- 4) Sommers SC, McManus RG: Multiple arsenical cancers of skin and internal organs. *Cancer* **6**: 347-359, 1953.
- 5) Prystowsky SD, Elfenbein GJ, Lamberg SI: Nasopharyngeal carcinoma associated with long-term arsenic ingestion. *Arch Dermatol* **114**: 602-603, 1978.
- 6) Zaldivar R, Prunes L, Ghai GL: Arsenic dose in patients with cutaneous carcinomata and hepatic haemangioendothelioma after environmental and occupational exposure. *Arch Toxicol* **47**: 145-154, 1981.
- 7) Schwartz RA, Stoll HL: Epithelial precancerous lesions. In: Fitzpatrick TB, Eisen A, Wolff K, Freedberg IM, Austen KF (ed) *Dermatology in General Medicine*. (3rd ed) McGraw-Hill, New York 1987, p 736-737.
- 8) Fujiwara H: Aberrant keratinization in skin neoplasms. *Acta Med Biol* **39**: 91-99, 1991.
- 9) Ito M, Tazawa T, Ito K, Shimizu N, Katsuumi K, Sato Y: Immunological characteristics and histological distribution of human hair fibrous proteins studied with anti-hair keratin monoclonal antibodies HKN-2, HKN-4, and HKN-6. *J Histochem Cytochem* **34**: 269-275, 1986.
- 10) Gerdes J, Schwab U, Lemke H, Stein H: Production of a mouse monoclonal antibody reactive with a human nuclear antigen associated with cell proliferation. *Int J Cancer* **31**: 1320, 1983.
- 11) Mullink H, Walboomers JMM, Tadema TM, Jansen, DJ, Meijer CJLM: Combined Immuno- and non-radioactive hybridocytochemistry on cells and tissue section: influence of fixation, enzyme pre-treatment, and choice of chromogen on detection of antigen and DNA sequences. *J Histochem Cytochem* **37**: 603-609, 1989.
- 12) Kao GF: Precancerous lesions and carcinoma *in situ*. In: Farmer ER, Hood AF (ed) *Pathology of the skin*, Appleton and Lange, East Norwalk 1990, p 550-567.
- 13) Klein W: Experimentelle Studien über den Nucleinstoffwechsel: Über die fermentative Depolymerisierung der tierischen Nucleinsäure. *Ztschr F Physiol Chem* **218**: 164-172, 1933.
- 14) Limarzi LR: The effect of arsenic (Fowler's solution) on erythropoiesis: A contribution to the megakaryoblast-normoblast problem. *Am J M Sci* **206**: 339-347, 1943.
- 15) Maver ME, Voegtlin C: The chemistry of cell division: The inhibition of tumor and liver nucleases by arsenicals. *Am J Cancer* **29**: 333-340, 1937.