

Morphogenesis of the Subclavian Vein Relative to the Course of the Nerve to the Subclavius Muscle and the Phrenic Nerve

Hiroo MATSUMURA and Katsuji KUMAKI

First Department of Anatomy, Niigata University School of Medicine, Niigata, Japan

Received July 20 1995; accepted November 1 1995

Summary. The nerve to the subclavius muscle usually runs in front of the subclavian vein, as does the accessory phrenic nerve. On the other hand, the phrenic nerve runs behind the subclavian vein. (These three nerves should be recognized as the phrenic nerve "group".)

As a result of detailed observations, four cases out of 246 body sides (123 corpses) dissected at the Niigata University School of Medicine unveiled nerves to the subclavius running behind the subclavian vein. Including these four cases, the relationship between the phrenic nerve "group" and the subclavian vein could be classified into five basic categories. The phenomena were related to the morphogenesis of the subclavian vein. In consideration of the developmental pattern of the human venous system, the subclavian vein indicated five different developmental pathways into which it might develop.

Key words—human gross anatomy, morphogenesis, subclavian vein, nerve to subclavius, phrenic nerve.

INTRODUCTION

The subclavian vein, a large vein in the continuity of the axillar vein which is the confluence of the upper limb veins, joins the internal jugular vein behind the sternoclavicular joint to form the brachiocephalic vein. The subclavian vein is nowadays often punctured for the measurement of central venous pressure or for intravenous high calorie nutrition. Though the vein is considered stable and presents few variations in its course, detailed observations of its relationship with the phrenic nerve and the nerve to the subclavius muscle disclose several variations. Classify-

ing these changes would deepen understanding of the morphogenesis of the vein. The relevance of these anatomical variations consists in their reflecting a particular aspect of morphogenesis; therefore, the frequency of each change is not problematic per se.

MATERIALS AND METHODS

All samples were corpses donated for the student dissection course at the Niigata University School of Medicine. They were first used for pedagogic purposes before being further assessed. The findings of the subclavian vein, the phrenic nerve and the nerve to the subclavius had been obtained during six academic years (1981-1986). Four cases (in which the nerve to the subclavius passed behind the subclavian vein) were detected from among 123 Japanese subjects, i.e. 246 body sides. Detailed findings of the nerve to the subclavius had subsequently been observed from the dissection of 24 sides in 1981, 33 sides in 1984 and 17 sides in 1989 (total 74 sides). There was one interesting side in 1984 which showed the co-existence of the nerve to the subclavius running behind the subclavian vein and with the normal course, as shown in Fig. 2. These 74 sides; therefore, had 75 nerves to the subclavius instead of 74 nerves. Every finding was observed with the naked eye. Important findings were drawn by hand and stereoscopically photographed.

FINDINGS

A. Case presentation

The phrenic nerve is known to present several variations.¹⁻³⁾ From our past observations, while the phrenic nerve usually takes its course between the subclavian artery and vein, it can also pass in front of

Correspondence: Hiroo Matsumura, First Department of Anatomy, Niigata University School of Medicine, Asahimachi 1, Niigata 951, Japan.

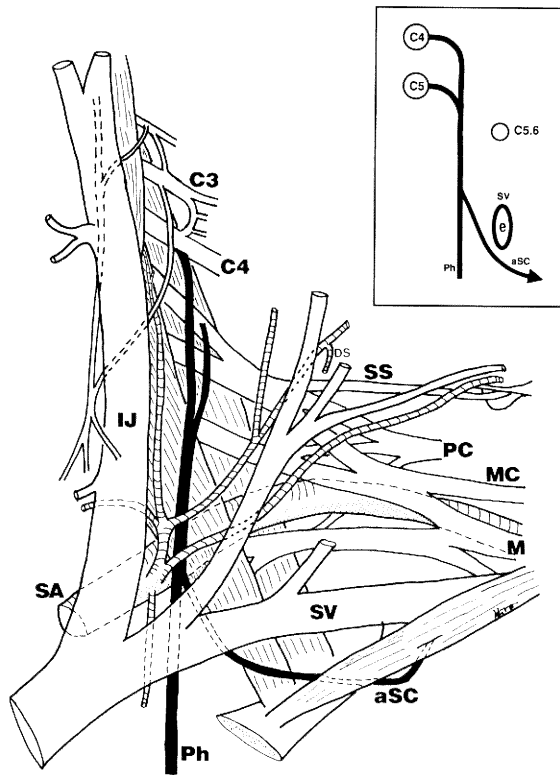


Fig. 1. The accessory nerve to the subclavius (*aSC*) (a new definition) passes clearly behind the subclavian vein, to the left side view of the neck region. Schematic diagram as viewed from the lateral side is illustrated in the square.

Abbreviations used in figures.

aPh, the accessory phrenic nerve; aSC, the accessory nerve to the subclavius (a new definition); C3-C6, the 3th-6th cervical nerves; C5 • 6, the upper trunk of the brachial plexus; DS, the dorsal scapular artery; EJ, the external jugular vein; IJ, the internal jugular vein; LC, the lateral cord of the brachial plexus; M, the median nerve; MC, the musculocutaneous nerve; PC, the posterior cord of the brachial plexus; Ph, the phrenic nerve; SA, the subclavian artery; SC, the nerve to the subclavius; SS, the suprascapular nerve; SV, the subclavian vein.

the subclavian vein according to its origin or furcation. We therefore referred to those phrenic nerves running in front of the subclavian vein as the accessory phrenic nerves, and differentiated them from the normal ones which we referred to as the principal phrenic nerves (Yamada and Mannen.⁴⁾) We also experienced variations of the nerve to the subclavius, which is usually thought of as stable.

1. The nerve to the subclavius passing behind the subclavian vein (Fig. 1)

We encountered two cases in males, aged 68 years (in 1981) and 80 years (in 1984), with the nerve to the subclavius passing behind the subclavian vein. The following observations were from the first case.

As shown in Fig. 1, the fibers of the principal phrenic nerve originated from a bundle arising from the caudal edge of C4 and the one from the ventral side of C5, forming a common trunk. The phrenic nerve descended vertically over the ventral surface of the scalenus anterior. The nerve passed posterior to the inferior belly of the omohyoid and the superficial cervical artery (Ramus superficialis of A. transversa cervicis, Nomina anatomica 6 ed⁹⁾) to reach the posterior to the subclavian vein, then ramified a branch in the region posterolateral to the angle of junction of the left internal jugular and subclavian vein. This branch descended laterally to the phrenic nerve and ventrally to the scalenus anterior, ran behind the subclavian vein, then passed the lower side of the vein to reach the anterior side; after taking a loose course, it entered the dorsal side of the subclavius muscle from the slightly medial area located in the first third from the origin of the first rib. We proposed calling this nerve the accessory nerve to the subclavius muscle. No supernumerary muscle bundles running horizontally to the posterior side of the subclavius, such as the formation of the posterior subclavius muscle, were observed. Neither the accessory phrenic nerve which ran in front of the subclavian vein, nor the nerve to the subclavius showing a normal course, i.e., in front of the subclavian vein, were detected. The ansa cervicalis was located medial to the internal jugular vein. The inferior root of the ansa cervicalis was formed from C2 and C3, displaying features of the medial form. No branches susceptible to joining the phrenic nerve or the nerve to the subclavius departed from the ansa cervicalis. As a result of a teasing examination of this case under a stereomicroscope with specimens immersed in water, the nerve to the subclavius was derived from C5.

2. Co-existence of the nerve to the subclavius running behind the subclavian vein and the nerve to the subclavius with a normal course, passing in front of the subclavian vein (Fig. 2)

We experienced two cases, a 78-year-old male (in 1984) and an 84-year-old female (in 1986). The following observations were from the second case.

The principal phrenic nerve originated from a bundle arising from the caudal edge of C4 and the one from the ventral side of C5, forming a common trunk. The

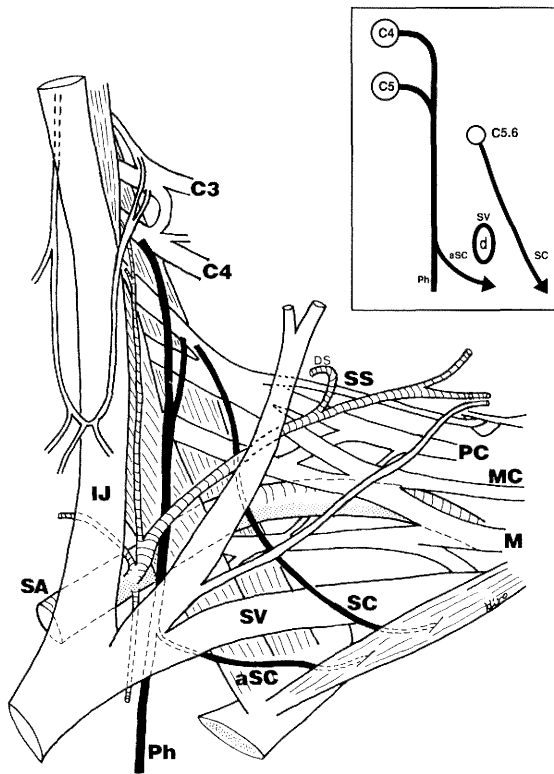


Fig. 2. Co existence of the accessory nerve to the subclavius (*aSC*) running behind the subclavian vein and the nerve to the subclavius (*SC*) with a normal course, passing in front of the subclavian vein. Right side view of the neck region. (One should note that this is reversed for the same direction of the other figures.) Schematic diagram as viewed from the lateral side is illustrated in the square.

Table 1. Components of the nerve to the subclavius

Segment	C 4-5	C 5	C 5-6	C 6	C 6-7
Number	3	39	31	1	1
%	4.0	52.0	41.3	1.3	1.3

phrenic nerve descended vertically over the ventral surface of the scalenus anterior. The nerve passed posterior to the inferior belly of the omohyoid and the superficial cervical artery (Ramus superficialis of A. transversa cervicis, Nomina anatomica 6 ed⁵⁾) to reach the posterior to the subclavian vein, then ramified a branch (accessory nerve to the subclavius) in the region posterolateral to the angle of junction of the right internal jugular and subclavian vein. This branch descended laterally to the phrenic nerve and ventrally to the scalenus anterior, ran behind the subclavian vein, then passed the lower side of the vein to reach the anterior side, and entered the dorsal side of the subclavius muscle from the slightly medial area located in the first third from the origin of the first rib. Moreover, a branch (nerve to the subclavius) deriving from the most ventral side of C5 (more proximal to where C5 and C6 join to form the superior trunk of the brachial plexus) descended obliquely in front of the brachial plexus and subclavian vein to enter the subclavius muscle in the portion slightly lateral to the center of the muscle. No accessory phrenic nerves, forming a common trunk with this branch, were observable. The ansa cervicalis was united on the anterior surface of the internal jugular vein by the inferior root formed by C2 and C3, thus displaying a lateral form. No branches susceptible to joining the phrenic nerve or the nerve to the subclavius departed from the ansa cervicalis. No supra-numerary muscle bundles such as the formation of the posterior subclavius muscle were observed.

B. Classified total (Table 1 and 2)

Tables 1 and 2 show the relationships between the nerve to the subclavius and the other nerves as observed from the dissection of 74 sides. As shown in Table 1, the nerves to the subclavius were mainly derived from C5 (39 sides) or C5 and C6 (31 sides), displaying a normal or “standard” pattern. In a few cases, the origins of the nerves were distributed from C4 to C7.

The relationships with the phrenic and the accessory phrenic nerve are summarized in Table 2.

Table 2. The relationship between the nerve to the subclavius and the phrenic nerve

	Common stem with the accessory phrenic nerve	Communicates with the phrenic nerve	Independent	
			Accessory phrenic nerve (+)	(-)
Number of nerves to subclavius	26	11	6	32
%	34.7	14.7	8	42.7

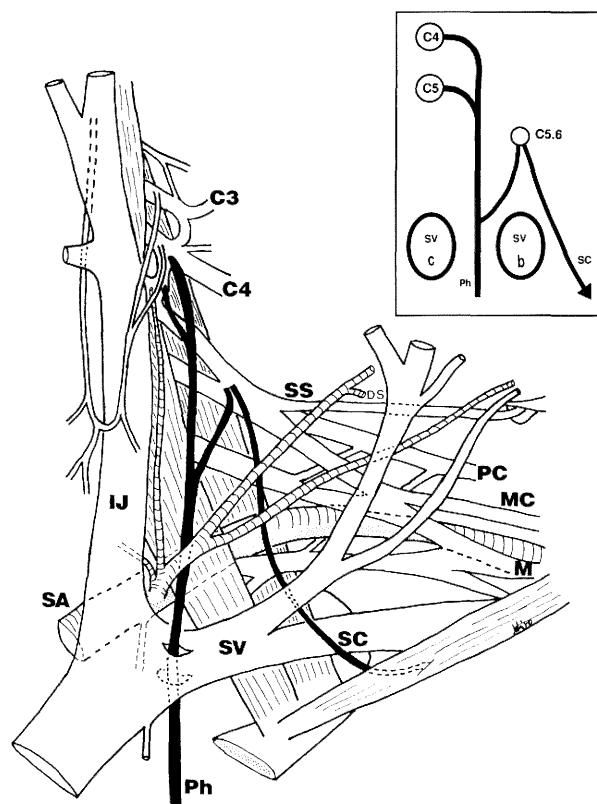


Fig. 3. A phrenic nerve pierces through the subclavian vein, to the left side view of the neck region. Schematic diagram as viewed from the lateral side is illustrated in the square.

Thirty-eight nerves to the subclavius out of the 74 displayed a separate trunk, whereas 37 showed a common trunk. The frequency of the occurrence of either case could be assumed as equal. The nerve to the subclavius passing in front of the subclavian vein formed a common trunk with the accessory phrenic nerve in the majority of cases (26 cases). Eleven nerves to the subclavius formed a common trunk with the phrenic nerve, but these cases included four cases where only the nerve to the subclavius passing behind the subclavian vein was observed. In the exception to these four cases, the nerve to the subclavius ran in front of the subclavian vein.

Accessory phrenic nerves were observed in 32 sides (42.7%) out of 74 sides. In addition, a phrenic nerve (Fig. 3) and an accessory phrenic nerve piercing through the subclavian vein were observed.

DISCUSSION

1. The course of the nerve to the subclavius

The majority of the reference literature^{6,7)} states that the nerve to the subclavius is:

- 1) Formed by C5 and 6-derived components and emerges from the upper trunk of the brachial plexus;
- 2) usually descends obliquely in front of the brachial plexus and the scalenus anterior;
- 3) runs in front of the subclavian vein and 4) often communicates or forms a common trunk with the accessory phrenic nerve, as shown in Fig. 4a.

However, a few reference publications state the course otherwise. In the corresponding chapter of *Nippon Human Anatomy*,⁸⁾ it reads: "... (the nerve) runs between the subclavian artery and the subclavian vein and reaches the subclavius muscle". This implies that the nerve passes behind the subclavian vein. In the illustrated textbook by Spalteholz-Spanner,⁹⁾ the nerve is described as passing "either in front of or behind the subclavian vein". Also, Kurihara³⁾ showed an illustration in his communication on the course of the phrenic nerve and the so-called accessory phrenic nerve in the cervical region (a case similar to the one we reported above) as non-standard, or a variation case. Therefore, and as we described, the nerve to the subclavius, with the exception of a few cases (4/246), usually descends in front of the subclavian vein, or as described in the majority of the reference literature.

Also, in cases where the accessory phrenic nerve phenomena is observed, the available literature supports our findings in that the nerve to the subclavius often communicates with the accessory phrenic nerve. However, also noteworthy is that the accessory phrenic nerve is only reported at a 42.7% frequency.

The stratum of the nerve to the subclavius belongs to the most anterior components of the brachial plexus such as the phrenic and the accessory phrenic nerve. Also the lateral and medial pectoral nerves belong to the same stratum. Moreover Kodama et al.¹⁰⁾ indicated that the suprascapular nerve belongs to the anterior component of the brachial plexus.

2. Morphogenesis of the subclavian vein

The phrenic nerve usually passes between the subclavian artery and vein. However, cases presenting multiple phrenic nerves or other variations¹⁻³⁾ have also been reported (Kumaki¹¹⁾). On the other hand, the nerve to the subclavius was reported to run not only behind the subclavian vein, but also sometimes in front of it. It often makes a common trunk with the

accessory phrenic nerve (26 cases) and with the phrenic nerve (11 cases out of 74 cases). Moreover, the stratum belong to the same one. These three nerves, therefore, should be recognized as the phrenic nerve "group". Thus, there would be five different relationships between the phrenic nerve "group" and

the vein.

a) The phrenic nerve passes behind the subclavian vein, and the nerve to the subclavius passes in front of the vein (Fig. 4a).

b) The phrenic nerve passes behind the subclavian vein, and the accessory phrenic nerve and the nerve

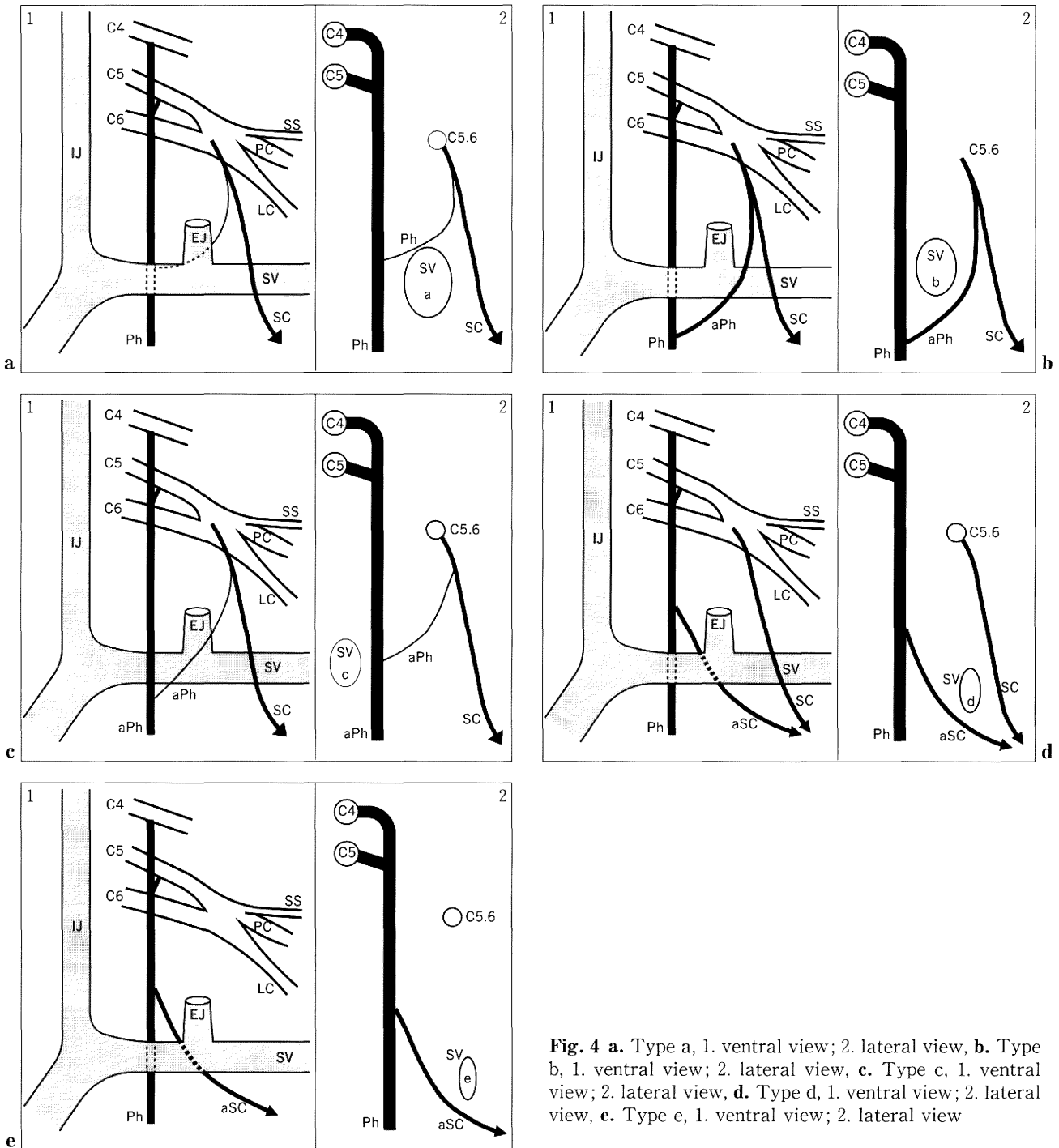


Fig. 4 a. Type a, 1. ventral view; 2. lateral view, **b.** Type b, 1. ventral view; 2. lateral view, **c.** Type c, 1. ventral view; 2. lateral view, **d.** Type d, 1. ventral view; 2. lateral view, **e.** Type e, 1. ventral view; 2. lateral view

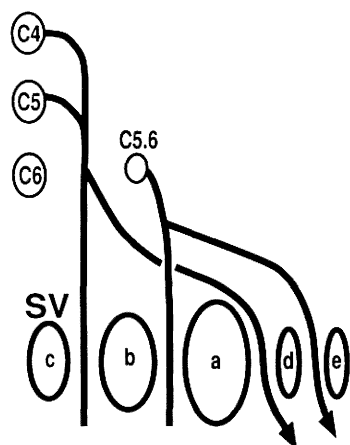


Fig. 5. Diagram of the five pathways of the subclavian vein.

Table 3. Number of the type of the subclavian vein

Type	a	b	c	d	e	Others	
						a+c	a+b
Number	39	27	3	1	2	1	1
%	52.7	36.5	4.1	1.4	2.7	1.4	1.4

to the subclavius pass in front of the vein (Fig. 4b).

c) There is no normal or standard phrenic nerve configuration, but both the accessory phrenic nerve and the nerve to the subclavius pass in front of the vein (Fig. 4c).

d) The nerve to the subclavius, running behind the vein, and the "standard" nerve to the subclavius which passes in front of the vein, are both present (Fig. 4d).

e) Not only the phrenic nerve but also the nerve to the subclavius passes behind the subclavian vein as reported here with (Fig. 4e).

The relationship between the phrenic nerve "group" and the subclavian vein would be closely connected with the morphogenesis of the subclavian vein. In the morphogenesis of the human venous system, a intricate plexus is first formed, then part of the intrinsically necessary portion of the plexus to the developing vascular system develops as the post-natal vascular system. In the case of the subclavian vein, there are five possible relationships so far suspected (Fig. 4a-e); therefore, the five vascular pathways which will form the subclavian vein should be present in the fetal stage of human development. Fig. 5 summarizes the five pathways of the sub-

clavian vein and the nerve to the subclavius, the phrenic nerve and the accessory phrenic nerve. The diameter of each subclavian vein is in proportion to the results of our observations of 74 sides. (Table 3 and Fig. 5) One of these five categories, or, in other words, one of these five configurations would have subsisted and grown through the morphogenesis of the vascular trunk. Other possible explanations would be that the phrenic nerve piercing the subclavian vein (Fig. 3) originates from the portion shown in Fig. 4b and 4c, while the accessory phrenic nerve piercing the same vein would be derived from the portion shown in Fig. 4a and 4b.

Acknowledgments. The authors wish to express our thanks to Mr. K. Ishimoto and Mr. K. Hokari (1st Department of Anatomy, Niigata University) for their care in keeping and managing the corpses.

REFERENCES

- 1) Kikuchi T: A contribution to the morphology of the ansa cervicalis and the phrenic nerve. *Acta Anat Nippon* **45**: 242-281, 1970.
- 2) Yano K: Zur Anatomie und Histologie des N. phrenicus und sogenannten Nebenphrenicus, nebst Bemerkungen über ihre Verbindung mit Sympathicus. *Fol Anat Jpn* **6**: 247-290, 1928.
- 3) Kurihara H: Anatomical study on the course of the phrenic nerve and the so-called accessory phrenic nerve in the cervical region. *Nagasaki Med J* **21**: 985-1000, 1943. (in Japanese)
- 4) Yamada M, Man'nen H: Anatomy for dissectors. Nankodo, Tokyo, 1985. (in Japanese)
- 5) Nomina Anatomica (6th ed) Churchill Livingstone, Edinburgh-London-Melbourne-New York, 1989.
- 6) Williams PL, Warwick R, Dyson M, Bannister L (eds) Gray's Anatomy. (37th ed) Churchill Livingstone, Edinburgh-London-Melbourne-New York, 1989.
- 7) Romanes GJ (eds): Cunningham's Textbook of Anatomy. (12th ed) Oxford University Press, Oxford-New York-Toronto, 1981.
- 8) Kaneko U: Nippon Human Anatomy. (vol. 3) Nanzando, Tokyo 1982. (in Japanese)
- 9) Spalteholz W, Spanner R: Handatlas der anatomie des menschen. (vol. 2) Scheltema & Holkema N.V., Amsterdam, 1961.
- 10) Kodama K, Kawai K, Okamoto K, Yamada M: The suprascapular nerves as re-interpreted by its communication with the phrenic nerve. *Acta Anat* **144**: 107-113. 1992.
- 11) Kumaki K: Anatomical report on human dissection. Department of anatomy, medical school, Kanazawa University, 1980. (in Japanese)