Acta Medica et Biologica
Vol. 44, No. 4, 199-207, 1996

Initial Experiences of Implantable Cardioverter-Defibrillator Treatment in Patients with Ventricular Tachyarrhythmias

Masaomi CHINUSHI, Yoshifusa AIZAWA, Akira ABE, Masami SHIBA, Takashi WASHIZUKA, Makoto TAMURA, Yutaka IGARASHI, Yoriko KUSANO, Shinichi NIWANO, Akira SHIBATA, Hiroshi WATANABE* and **Shoji EGUCHI***

First Department of Internal Medicine and *Second Department of Surgery, Niigata University School of Medicine, Niigata, Japan

Received June 24 1996; accepted September 18 1996

Summary. **Implantable cardioverter-defibrillators (ICD) were implanted in 11 patients with drug refractory ventricular tachyarrhythmias. Both ventricular fibrillation (VF) and sustained ventricular tachycardia (VT) were documented in 4 of the 11 patients, and VF or VT was observed in the other 4 and 3 patients, respectively. The mean left ventricular ejection fraction of the 11 patients was 40±22%; underlying heart diseases were observed in 9 patients, old myocardial infarction in 4 patients, and dilated cardiomyopathy in 5 patients.**

Transvenous ICD was implanted in 10 patients (91%), but because of a high defibrillation threshold, two epicardial patch electrodes were necessary in the remaining one patient. During the operative procedure, no complications were observed except for an episode of vasospastic angina in one patient with normal coronary arteries. In 3 patients with severe left ventricular dysfunction, VT with clinical QRS morphology was frequently observed within a few days after surgery, and additional antiarrhythmic drug therapy and changes in the detection mode of VF were required. Subclavian crash syndrome was noticed 26 months after ICD implantation in one patient. During the follow-up periods of 6 to 54 months (the mean being 28.7±20.6 months), VT and/or VF recurred in 6 of the 11 patients, and these tachycardias were terminated by appropriate ICD treatment. One patient died due to refractory heart failure 7 months after ICD implantation.

Transvenous implantation was easier and judged to be the first choice procedure for ICD implantation. ICD is a feasible therapy for drug refractory ventricular tachyarrhythmias, but special management is required to control VT/VF by antiarrhythmic drug or to detect complications.

Correspondence: Yoshifusa Aizawa, M.D. First Department of Ineternal Medicine, Niigata University School of Medicine, 1-754 Asahimachi, Niigata 951, Japan.

Key words—ICD, ventricular tachyarrhythmias.

INTRODUCTION

Since 1980, implantable cardioverter defibrillators (ICD) have been used clinically as a treatment for life threatening ventricular tachyarrhythmias.[1-3] In the recent model, the ICD implantation does not require thoracotomy, and antitachycardia pacing is incorporated. Excellent results of ICD treatment have been reported from the United States and Western Europe.[1-3] However, in onr country, only a limited number of patients have been treated with the ICD. In this paper, we analyze the experiences of initial ICD therapy.

SUBJECTS AND METHODS

From November 1992 to October 1995, ICD models (Medtronic PCD or Jewel Plus, Minnesota, U.S.A.) were implanted in 11 patients. All patients fulfilled the criteria as follows: 1) ventricular fibrillation (VF) or sustained ventricular tachycardia (VT) was clinically documented; 2) antiarrhythmic drugs (including amiodarone and dl-sotalol) failed to prevent spontaneous and/or the induction of ventricular tachyarrhythmia; 3) catheter ablation failed to prevent ventricular tachyarrhythmias; and 4) a surgical operation was considered inappropriate due to multiple sites of VT origin and/or left ventricular dysfunction.

Of the 11 patients, 8 were male and 3 were female, and ages ranged from 13 to 73 years (mean±SD; 55±

17) (Table 1). Both VF and VT were documented clinically in 4 of the 11 patients, and VF or VT was observed in 4 and 3 patients, respectively. In 7 patients with VT, 2-8 distinct QRS morphologies were recorded on a standard 12-lead electrocardiogram. Underlying heart diseases were demonstrated in 9 of 11 the patients, i.e., dilated cardiomyopathy in 5 and previous myocardial infarction in 4 patients. The remaining 2 patients with VF did not have any organic heart disease. Ejection fraction by left ventriculography (n=9) or by two-dimensional echocardiogram (n=2) was from 17 to 76% (the mean being 40±22%) (Table 1). Three patients with low ejection fraction belonged to NYHA III, and the other patients were in NYHA II.

Electrophysiologic study

Before ICD implantation, an electrophysiologic study was performed on all patients in a non-sedated and post absorptive state. Informed consent was obtained after explanation of the purpose, the procedure, the results and the possible complications.

Three 6F quadripolar electrode catheters with interelectrode distances of 0.5 cm were positioned within the heart to stimulate the heart and to record the intracardiac electrogram. The band-pass filter was set at 50 and 500 Hz for the intracardiac electrogram. Electrical stimulation was delivered at twice the late diastolic threshold with a pulse width of 2 msec using a cardiac stimulator (Fukuda Denshi Co, Cardiac Stimulator BC02). Our standard protocol of VT induction consisted of 1 to 3 extrastimuli and rapid pacings up to a cycle length of 286 msec from two sites in the right ventricle.[4,5] If this protocol could not induce VT, isoproterenol was infused to increase the sinus rate by 20%, and stimulation using the same protocol was repeated at the two sites in the right ventricle and at one site in the left ventricle. The endpoint was either the induction of sustained ventricular arrhythmia or the completion of the protocol.

The site of VT origin was determined as the earliest activation site during VT. If an abnormal local electrogram, such as mid-diastolic potential or continuous activity, was recorded during VT, rapid pacing was performed and the central common slow pathway of the reentry circuit was determined by the criteria of Fontaine et al.[6] Pace-mapping during sinus rhythm[7] was also used to facilitate the mapping of the site of VT origin.

Operative procedure

ICD implantation was performed under general anesthesia. In the case of the PCD model, the leads were

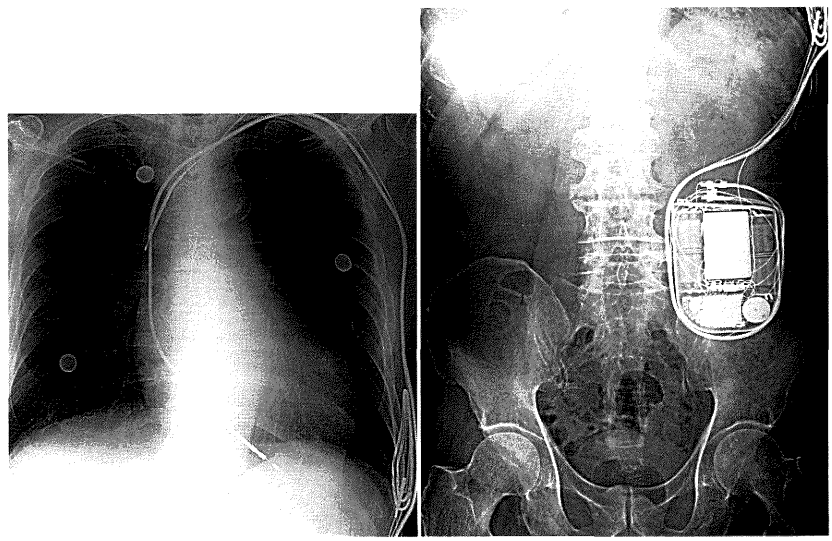

Fig. 1. PCD implantation (Third generation model). **A.** A tripolar endocardial screw-in lead is positioned at the apex of the right ventricle, and another unipolar defibrillation lead is placed in the superior vena cava, **B.** A patch electrode is also implanted in the left side subcutaneously. A shock current is then delivered sequentially between the tripolar and unipolar electrodes and between the tripolar electrode and the patch electrode. A generator weigh 197 g has been placed in the abdomen.

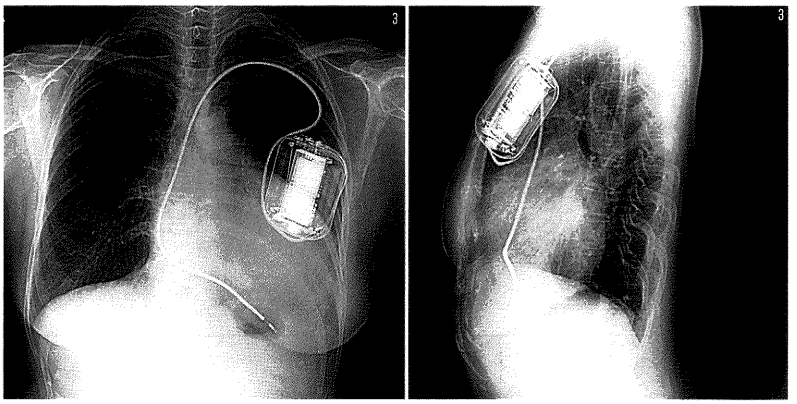

Fig. 2. Jewel-plus implantation (Fourth generation model). A tripolar endocardial screw-in lead has been positioned at the apex of right ventricle, and a generator weigh 129 g is implanted in the left side of the precodium under the pectoral muscle. A biphasic defibrillation current is then delivered between the lead and can electrode of the generator.

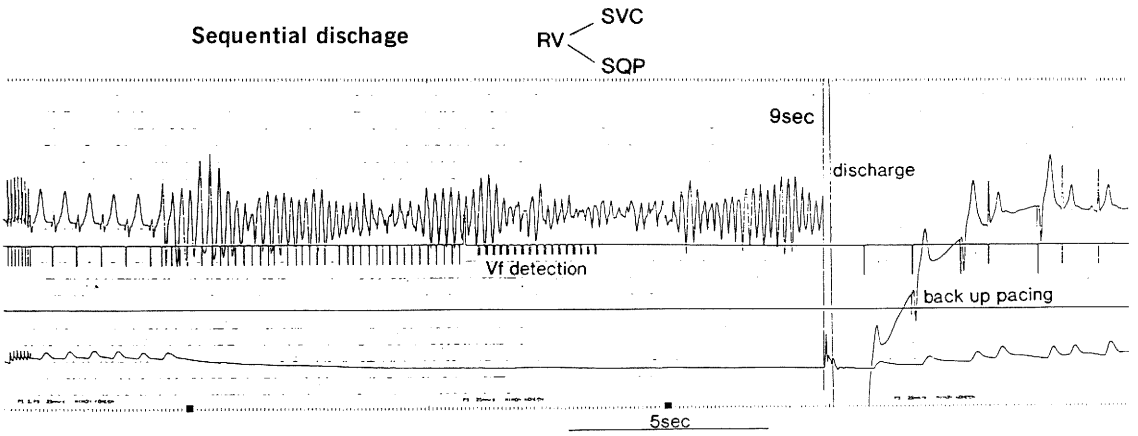

Fig. 3. Defibrillation test during the operation. After induction of VF by programmed electrical stimulation, a shock pulse at 18 J was delievered sequentially (Case 10). The VF is successfully terminated and back-up ventricular pacing initiated.

advanced via the subclavian vein through a puncture. A tripolar endocardial screw-in lead for bipolar pacing and sensing as well as for defibrillation was placed at the apex of the right ventricle. Another unipolar lead for defibrillation was placed in the superior vena cava. A sudcutaneous implantable patch electrode was added to provide a sequential defibrillation current pathway (Fig. 1).

In the case of the Jewel-Plus model, the tripolar endocardial screw-in lead was advanced via the cephalic vein through a cut-down and placed at the apex of the right ventricle, and a biphasic defibrillation current[8,9] was delivered between the lead and the ICD generator which acted as the electrode (Fig. 2).

The two ICD models had functions of back-up pacing, antitachycardia pacing, and memory, in addition to the function of defibrillation; they are called "third generation" ICD models.

Following the measurement of R-wave amplitude, the slew-rate, pacing threshold as well as pacing impedance were assessed using an external pacing system analyzer; defibrillation efficacy was also assessed during induced VF. As the absolute require-

ment for implantation, VF had to be terminated twice at an energy less than 18 J in the PCD model and less than 24 J in the Jewel-Plus model; this check was used in the defibrillation test (Fig. 3). If the intracardiac defibrillation system failed to terminate VF, an external thoracic defibrillator was used as a rescuer.

After the completion of testing, the leads were secured at the venous entry site and connected to the ICD generator. The PCD generator was placed in the left upper abdomen under the abdominal rectus muscle, and the Jewel-Plus generator was positioned on the left side of the precordium under the pectoral muscle.

After the operation, electrocardiogram monitoring was continued for at least 10 days. A final defibrillation efficacy test was performed to verify proper function of the device before discharge from our hospital.

Follow-up

All patients were followed up in our out-patient clinic

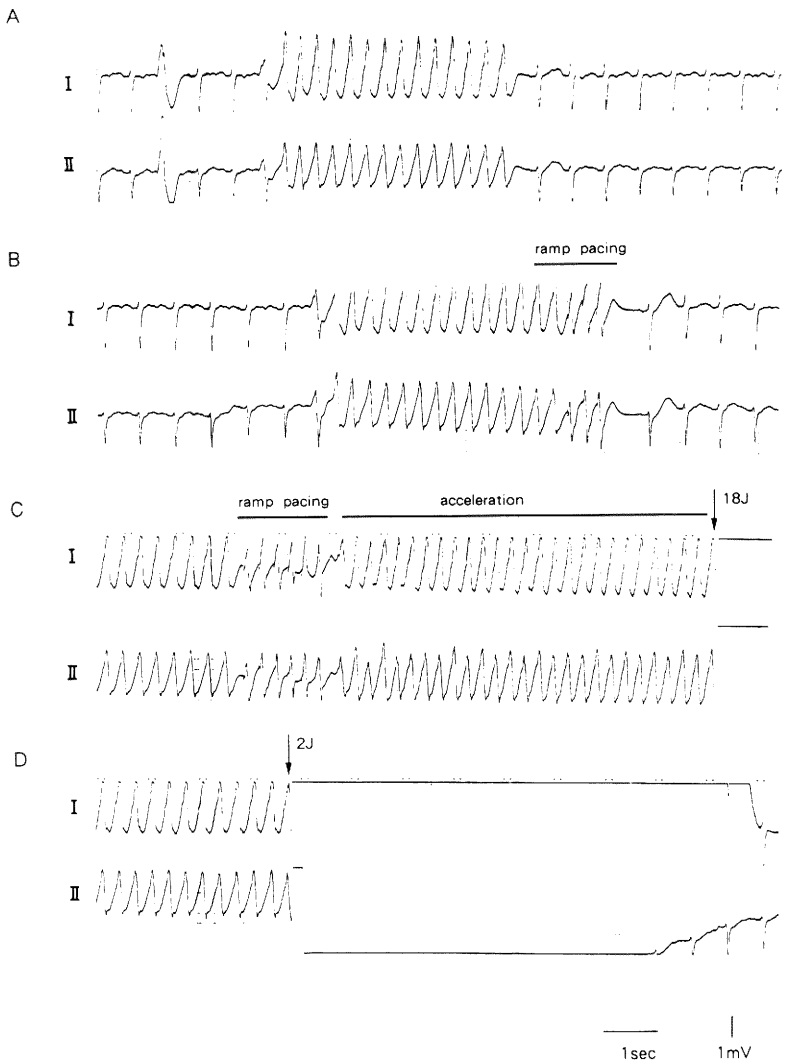

Fig. 4. Monitor electrocardiograms and ICD treatment. After the implantation of ICD, sustained and non-sustained VTs *(Panel A)* with a clinical QRS morphology occurred frequently (Case 10). Antitachycardia ramp pacing usually terminated but sometimes accelerated the VT *(Panel B and C)*, and cardioversion was required in the later situation. The VT was repetitively terminated by low energy cardioversion at 2 J *(Panel D)*.

Table 1. Characteristics of patients

Case	Age/Sex	UHD	Arrhythmia	# of TV morphology	LVEF (%)	CA or Ope	DFT (J)	ICD system	Lead position	# of VT/VF episodes	Follow-up (months)
1. MN	56M	Idiopathic	VF	-	56	-	<15	PCD	RVA, SVC, SQ	0	54
2. EH	67M	OMI	VF	-	19	-	<18	PCD	RVA, SVC, SQ	(0)	(7)
3. SY	69M	OMI	VF/VT	2	30	-	<18	PCD	RVA, SVC, SQ	0	46
4. MW	73M	OMI	VF	-	67	-	<18	PCD	RVA, SVC, SQ	0	47
5. TY	13M	Idiopathic	VF	-	72	CA	<18	PCD	Epicardial Patch	3	48
6. TS	64F	DCM	VF/VT	3	17	-	<18	PCD	RVA, SVC, SQ	4	44
7. IK	51M	DCM	VF/VT	5	33	CA	<18	Jewel-Plus	RVA	0	12
8. EI	57M	DCM	VT	8	26	CA	U. D.	Jewel-Plus	RVA	4	11
9. IO	66F	OMI	VT	8	21	CA	<24	Jewel-Plus	RVA	7	11
10. YA	43M	DCM	VF/VT	4	40	CA and Ope	<18	Jewel-Plus	RVA	47	8
11. KO	55F	DCM	VT	4	36	CA	<24	Jewel-Plus	RVA	8	6

M, male; F, female; UHD, underlying heart disease; OMI, old myocardial infraction; DCM, dilated cardiomyopathy; LVEF, left ventricular ejection fraction; CA, catheter ablation; Ope, surgical operation; U. D., undetermined; RVA, apex of the right ventricle; SVC, superior vena cava; SQ, subcutaneous; DFT, defibrillation threshold.

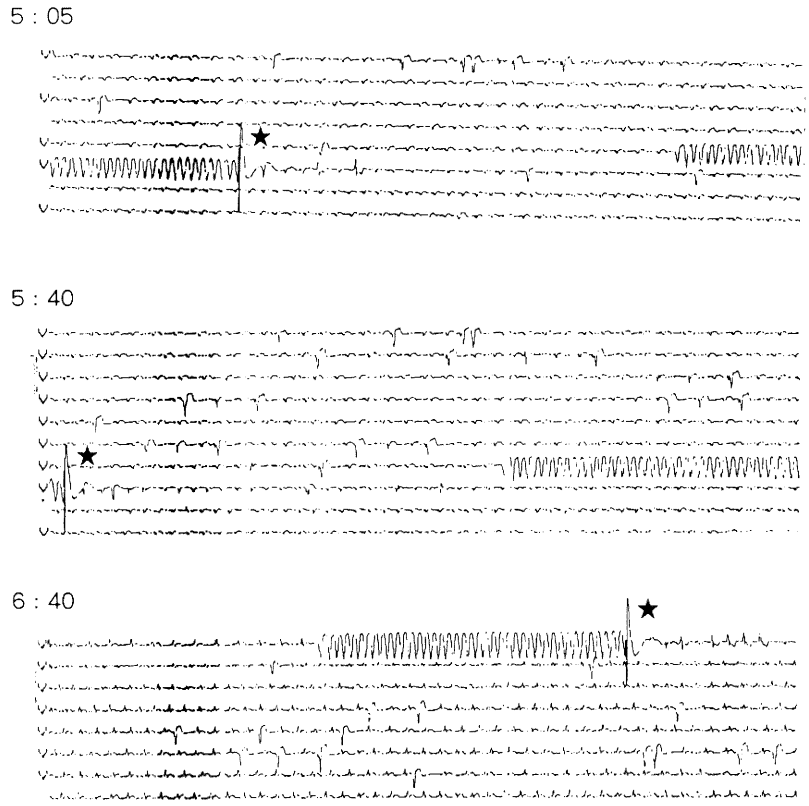

Fig. 5. Electrocardiogram Monitoring. Sixteen hours after implantation, VT with clinical morphology recurred frequently (Case 9). After delivery of cardioversion at 24 J (star), each VT successfully was terminated. See text.

or at least once a month by attending physicians. The ICD generator was checked regularly, and stored information was read out each time when VT or VF was suspected of recurring.

RESULTS

1) Electrophysiologic study and non-pharmacological treatment

Before ICD implantation, VF and/or VT were reproducibly induced by programmed electrical stimulation in all patients. During monomorphic VT, rapid ventricular pacings were attempted from the right ventricle, and criteria of transient entrainment of VT was confirmed in 10 VTs of 6 patients. However, the pacing was ineffective to terminate VT and usually accelerated this, requiring external cardioversion to resume sinus rhythm (Fig. 4).

Endocardial mapping revealed multiple and/or a wide arrhythmogenic origin extending more than 2×2 cm in 5 patients. The site of origin could not be determined due to circulatory collapse during VT in the other 2 patients. Catheter ablation (direct and/or radiofrequency current) was attempted for 14 monomorphic QRS morphologies of VT (Table 1), and 8 QRS morphologies became non-inducible after the ablation.[10] In one patient with idiopathic VF, the first beat of VF was mapped and delivery of direct current shocks to the site controlled frequent attacks of VF.[11] In one patient with idiopathic dilated cardiomyopathy, VTs with new QRS morphologies became inducible after the surgical operation which was to be proved refractory to antiarrhytmic drugs.

2) ICD implantation

The transvenous PCD system was successfully implanted in 5 of 6 patients (Table 1). In the other one patient, two epicardial patch electrodes were

required due to a high defibrillation threshold (more than 34 J). In Jewel-Plus implantation, VF was induced and successfully terminated by shock at <24 J in 4 of 5 patients but not confirmed in the other patient because of frequent episodes of VF.

Two or three defibrillation tests were performed to confirm that the induced VF was successfully terminated by the shock at 18 or 24 J. However, when deterioration of cardiac function was considered to occur, further tests were later performed at bed side.

In all patients, R-wave amplitude, slew rate, pacing thershold as well as pacing impedance fulfilled the criteria for ICD implantation. The implantation procedure of ICD required 2-3 h.

3) Occurrence of arrhythmias soon after the operation

Within 24 hours after the operation, VT showing the QRS morphology identical to the clinically documented VT recurred in 2 patients (7 times in Case 9 and 47 times in Case 10) (Fig. 5) and cardioversion at 24 J was appropriately delivered to terminate VT.

Antitachycardia ramp pacing was also attempted in one patient, but followed by acceleration of the VT rate (Fig. 4). Of these, pulmonary congestion (Case 9), and increased sinus (Case 10) were associated with the recurrence of VT, and precipitating factors were controlled by drugs.

In another patient (Case 11), VT recurred 4 days after the operation as detected by ICD. However, cardioversion at 24 J failed because VT with a different morphology was induced. In this case, cardioversion at 3 J could terminate the original VT without the induction of new VT.

In the other 8 patients, no arrhythmic event was observed during their hospital stay and no inappropriate shock was delivered. Antiarrhythmic drugs were prescribed to 7 of 11 patients to decrease spontaneous VT and/or VF attacks before they were discharged: dl-sotalol in 2, aprindine in 1, amiodarone in 1, bepridil in 1, mexiletine in 1, and amiodarone, metoprolol and procainamide in one patient.

4) Complications

No major procedure- or device-related complication was observed during the implantation of ICD. One patient developed vasospastic angina which resulted in hypotention as well as chest pain and ST elevation. The angina was controlled by nitroglycerin and the implantation was performed uneventfully.

5) Long-term follow-up

Seven months after ICD implantation, one patient died due to refractory congestive heart failure (Table 1). During the follow-up period of 28.7±20.6 months (range from 6 to 54), ventricular arrhythmia was documented in 6 of 11 patients, and successfully terminated by the ICD.

In one patient, generator exchange was required 3.5 years after the implantation. Three shocks at 34 J were delivered and ventricular pacing was continued for bradycardic atrial fibrillation, which must have been the cause of the early battery drain.

Lead fracture was observed in one patient in the endocardial lead placed in the superior vena cava, 26 months after PCD implantation. Using a basket catheter, the fractured lead was removed. Fortunately, VF was terminated by a shock at 34 J between a tripolar common electrode and a subcutaneous patch electrode.

DISCUSSION

Indication of ICD treatment: If ventricular arrhythmia can be cured by catheter ablation and/or a surgical operation, excellent long-term results are expected.[12,13] If the sites of VT origin are determined within a narrow area, these non-pharmacological treatments should be indicated before implantation of the ICD system. In our 11 patients, these interventions were not practical because 8 of 11 patients suffered from spontaneous VF attacks and the other 3 patients had multiple and/or a wide site of VT origin. Therefore, ICD was considered the most suitable treatment for these patients.

ICD implantation: After the development of the transvenous implantation technique, the ICD implantation procedure has become safer and easier, and indication of ICD implantation has been extended to patients with severe left ventricular dysfunction.[2,14] Defibrillation with a biphasic current pulse provides more efficient defibrillation[8,9] and is helpful in obtaining a high success rate using the transvenous implantation system. In the present study, transvenous implantation was highly successful in 10 of 11 patients (91%), and 8 of the 11 patients with a left ejection fraction of less than 40%. Epicardial patch electrodes were required in only one patient, but a biphasic defibrillation current was not attempted here.

Mode of ICD therapy: In the third generation model of ICD, antitachycardia pacing has become available for the treatment of VT, and the high terminability

of VT has been reported.[15] Antitachycardia pacing is feasible to prevent early battery drain, as well as to avoid stressful shock. However, as reported earlier, some electrophysiologic factors, i.e., pacing site, pacing cycle length, pacing mode, and electrophysiologic characteristics of the central common pathway, seem important for the termination of VT by antitachycardia pacing,[16,17] and more studies are warranted. However, in our patients, rapid ventricular pacing was not effective in terminating the VTs (Fig. 4), and antitachycardia pacing was not selected as the first therapy mode for any patient.

Complications: There were no major complications during the operation in any patient except for one with vasospastic angina having normal coronary arteries (Case 8). Mechanical stimulation caused by a tripolar electrode seemed to initiate the vasospastic angina. To prevent this rare complication, administration of Ca-antagonist might be helpful.

In 3 patients, VT recurred frequently within a few days after the implantation, but before the implantation of ICD, the frequency of an arrhythmic event was less than once a month in two of the three patients. Although the precise mechanisms of the frequent VT attacks were uncertain, the influence of general anesthesia, secretion of catecholamine after the operation, inappropriate water balance, and/or mental stress seemed related to the frequency of the VT attacks.

Finally, endocardial leads are to be implanted using the cut-down technique to avoid the subclavian crash syndrome[18,19] which was observed in one patient after PCD implantation.

Long-term follow-up: During the follow-up period of 28.7 ± 20.6 months, VT and/or VF recurred in 6 of 11 patients. In the remaining 4 patients, generator exchange will eventually be required even though they have not shown any episode of ventricular arrhythmia during the 4 years since ICD implantation.[20,21] Therefore, appropriate criteria for replacement of ICD generator are required when the battery has drained without shock.

CONCLUSIONS

1) ICD was implanted in 11 patients with ventricular tachyarrhythmia refractory to drugs and nonpharmacological therapies.

2) During the follow-up period of 28.7 ± 20.6 months, VT and/or VF recurred in 6 patients, and all were successfully terminated by ICD control.

3) Transvenous implantation should be the first choice procedure foe ICD implantation.

4) ICD was useful for treatment of refractory ventricular tachycardia but some specific management was required to control VT/VF or other complications.

REFERENCES

1) Bardy GH, Hofer B, Johnson G, Kudenchuk PJ, Poole JE, Dolack L, Gleva M, Mitchell R, Kelso D: Implantable transvenous cardioverter defibrillators. *Circulation* **87:** 1152-1168, 1993.
2) The PCD investigator groups: Clinical outcome of patients with malignant ventricular tachyarrhythmias and an implantable cardioverter-difibrillator implanted with or without thoracotomy: an international multicenter study. *J Am Coll Cardiol* **23:** 1521-1530, 1994.
3) Crandall BG, Morris CD, Cutler JE, Kudenchuk PJ, Peterson JL, Liem LB, Broudy DR, Greene HL, Halperin BG, McAnulty JH, Kron J: Implantable cardioverter-difibrillator therapy in survivors of out-of-hospital sudden cardiac death without inducible arrhythmias. *J Am Coll Cardiol* **21:** 1186-1192, 1993.
4) Aizawa Y, Chinushi M, Naitoh N, Kitazawa H, Washizuka T, Uchiyama H, Shibata A: Catheter ablation of ventricular tachycardia with radiofrequency current with special reference to the termination and minor morphological change of reinduced ventricular tachycardia. *Am J Cardiol* **76:** 574-579, 1995.
5) Chinushi M, Aizawa Y, Kusano Y, Washizuka T, Miyajima T, Naitoh N, Takahashi K, Shibata A: Radiofrequency current catheter ablation for ventricular tachycardia. *Jpn Circ J* **58:** 315-325, 1994.
6) Fontaine G, Frank R, Tonet J, Grosgogeat Y: Identification of a zone of slow conduction appropriate for VT ablation: theoretical and practical considerations. *PACE* **12:** 262-267, 1989.
7) Morady F, Scheinman MM, DiCarlo LA, Davie JC, Herre JM, Griffin JC, Winston SA, Buitler M, Hantler CB, Wahr JA, Kou WH, Nelson SD: Catheter ablation of ventricular tachycardia with intracardiac shocks: results in 33 patients. *Circulation* **75:** 1037-1049, 1987.
8) Greene HL, DiMarco JP, Kudenchuk PJ, Scheinman MM, Tang ASL, Reiter MJ, Echt DS, Chapman PD, Jazayeri MR, Chapman FW, Ahmed M, Johnson JL, Niskanen RA: The biphasic waveform defibrillation investigators. Comparison of monophasic and biphasic defibrillating pulse waveforms for transthoracic cardioversion. *Am J Cardiol* **75:** 1135-1139, 1995.
9) Natale A, Sra J, Krum D, Dhala A, Deshpand S, Jazayeri M, Axtell K, Degroot P, VanHout W, Akhtar M: Comparison of biphasic and monophasic

pulses: Does the advantage of biphasic shocks depend on the waveshape? *PACE* **18:** 1354-1361, 1995.

10) Chinushi M, Aizawa Y, Ohhira K, Abe A, Shibata A: Long-term results of radiofrequency catheter ablation in non-ischemic sustained ventricular tachycardia with underlying heart disease. *Jpn Heart J* **37:** 183-194, 1996.

11) Aizawa Y, Tamura M, Chinushi M, Niwano S, Kusano Y, Naitoh N, Shibata A: An attempt at electrical catheter ablation of the arrhythmogenic area in idiopathic ventricular fibrillation. *Am Heart J* **123:** 257-260, 1992.

12) Mickleborough LL, Mizuno S, Downar E, Gray GC: Late results of operation for ventricular tachycardia. *Annal Thorac Surg* **54:** 832-838, 1992.

13) Gonska BD, Cao K, Schaumann A, Dorszewski A, Muhlen F, Kreuzer H: Catheter ablation of ventricular tachycardia in 136 patients with coronary artery disease: results and long-term follow-up. *J Am Coll Cardiol* **24:** 1506-1514, 1994.

14) Kleman JM, Castle LW, Kidwell GA, Maloney JD, Morant VA, Trohman RG, Wilkoff BL, McCarthy PM, Pinski SL: Nonthoracotomy versus thoracotomy implantable defibrillators. Intention to treat comparison of clinical outcomes. *Circulation* **90:** 2833-2842, 1994.

15) Heisel A, Neuzner J, Himmrich E, Pitschner HF, Liebrich A, Jung J, Sen S: Safety of antitachycardia pacing in patients with implantable cardioverter defibrillators and severely depressed left ventricular function. *PACE* **18:** 137-141, 1995.

16) Aizawa M, Aizawa Y, Chinushi M, Shibata A: Conductive property of the zone of slow conduction and its relation to pacing-induced terminability. *PACE* **17:** 46-55, 1994.

17) Aizawa Y, Naitoh N, Washizuka T, Kitazawa H, Takahashi K, Kodama I, Shibata A: Procainamide-induced changes in reentrant ventricular tachycardia with special reference to the tachycardia-interrupting critical paced cycle length during transient entrainment with rapid pacing. *Jpn Heart J* **35:** 611-623, 1994.

18) Schwartzman D, Nallamouthu N, Callans DJ, Preminger MW, Gottlieb CD, Marchlinski FE: Postoperative lead-related complications in patients with nonthoracotomy defibrillation lead systems. *J Am Coll Cardiol* **26:** 776-786, 1995.

19) Fahy GJ, Kleman JM, Wilkoff BL, Norant VA, Pinski SL: Low incidence of lead related complications associated with nonthoracotomy implantable cardioverter defibrillator systems. *PACE* **18:** 172-178, 1995.

20) Choue CW, Kim SG, Fisher JD, Roth JA, Ferrick KJ, Brodman R, Frame R, Gross J, Furman S: Comparison of defibrillator therapy and other therapeutic modalities for sustained ventricular tachycardia or ventricular fibrillation associated with coronary artery disease. *Am J Cardiol* **73:** 1075-1079, 1994.

21) Sweeney MO, Ruskin JN, Garan H, McGovern BA, Guy ML, Torchiana DF, Vlahakes GJ, Newell JB, Semigran MJ, Dec W: Influence of the implantable cardioverter/defibrillator on sudden death and total mortality in patients evaluated for cardiac transplantation. *Circulation* **92:** 3273-3281, 1995.