

Desquamated Gallbladder Mucosa: Follow-up Findings by Ultrasonography

Hideaki TAKIZAWA¹, Yoshiko MATSUZUKI², Yasuyuki SEINO² and Hitoshi ASAKURA³

¹Departments of Internal Medicine and ²Radiology, Nagaoka Red Cross Hospital, Nagaoka, ³The Third Department of Internal Medicine, Niigata University School of Medicine, Niigata, Japan

Received March 5 1997; accepted October 1 1997

Summary. Ultrasonography of a 65-year-old male experiencing pain in the epigastric region and fever revealed a thickened gallbladder wall with an oval, linear intraluminal structure. The patient was diagnosed as having acute cholecystitis with desquamated mucosa and was conservatively treated with antibiotics. Follow-up ultrasonography performed one week later revealed many mobile fragments with no acoustic shadowing in the gallbladder. Two weeks later, ultrasonography showed sludge in the gallbladder, which disappeared spontaneously 4 weeks later. After endoscopic retrograde cholangiopancreatography (ERCP) confirmed gallstones in the common bile duct, cholecystectomy with choledocholithotomy was performed two months later. In this report, the follow-up ultrasonograms, taken over a 4-week period, are presented in order to show the healing process of desquamated mucosa associated with acute cholecystitis.

Key words—gallbladder, cholecystitis, acute cholecystitis, ultrasonography, desquamated mucosa.

INTRODUCTION

Ultrasonographic criteria of acute cholecystitis include stones, sludge, increased wall thickness, gallbladder distention and ultrasonographic Murphy's sign.¹⁾ An unusual ultrasonographic sign of cholecystitis was first described by Wales in 1982,²⁾ with ultrasonograms of this case showing linear intraluminal structures with nonshadowing in the gallbladder, and a histology revealing desquamation of the necrotic mucosa. We report a case of acute cholecys-

titis with an nonshadowing oval and hollow structure within the gallbladder, which is consistent with desquamated mucosa. Furthermore, follow-up ultrasonographic findings in this case are presented to elucidate the fate of desquamated mucosa associated with cholecystitis.

CASE REPORT

A 65-year-old man suffered pain in the epigastric region and a fever of up to 38°C. Although abdominal pain subsided spontaneously, he visited our hospital two days later. On physical examination, there was slight tenderness in the right upper abdominal quadrant and the bulbar conjunctiva showed jaundice. The body temperature was 37.2°C and the pulse rate was 72 per minute. Laboratory data included elevated levels of aspartate aminotransferase (165 IU/l), alanine aminotransferase (293 IU/l), alkaline phosphatase (382 IU/l), γ -glutamyl transpeptidase (488 IU/l) and total bilirubin (7.7 mg/dl) and normal WBC count (5,400/mm³). Ultrasonography revealed a thickened wall of the gallbladder and an oval structure composed of thin echogenic layers in the gallbladder (Fig. 1A). The intraluminal structure, about 4 cm in size, had mobility with change in position and cast no acoustic shadowing. Enhanced CT showed an enhancement of the thickened wall of the gallbladder, though the intraluminal structure was not enhanced. Thus, a diagnosis of acute cholecystitis with desquamated gallbladder mucosa was made. After treatment with sulbactam/cefoperazone 2 g/day for 7 days, fever and tenderness in the abdomen subsided rapidly. Ultrasonography, performed one week after the first, revealed many mobile fragments with no acoustic shadowing in the gallbladder (Fig. 1B). All

Correspondence: Hideaki Takizawa, M.D., Department of Internal Medicine, Kido Hospital, 5-2-1 Kamikido, Niigata 950, Japan.

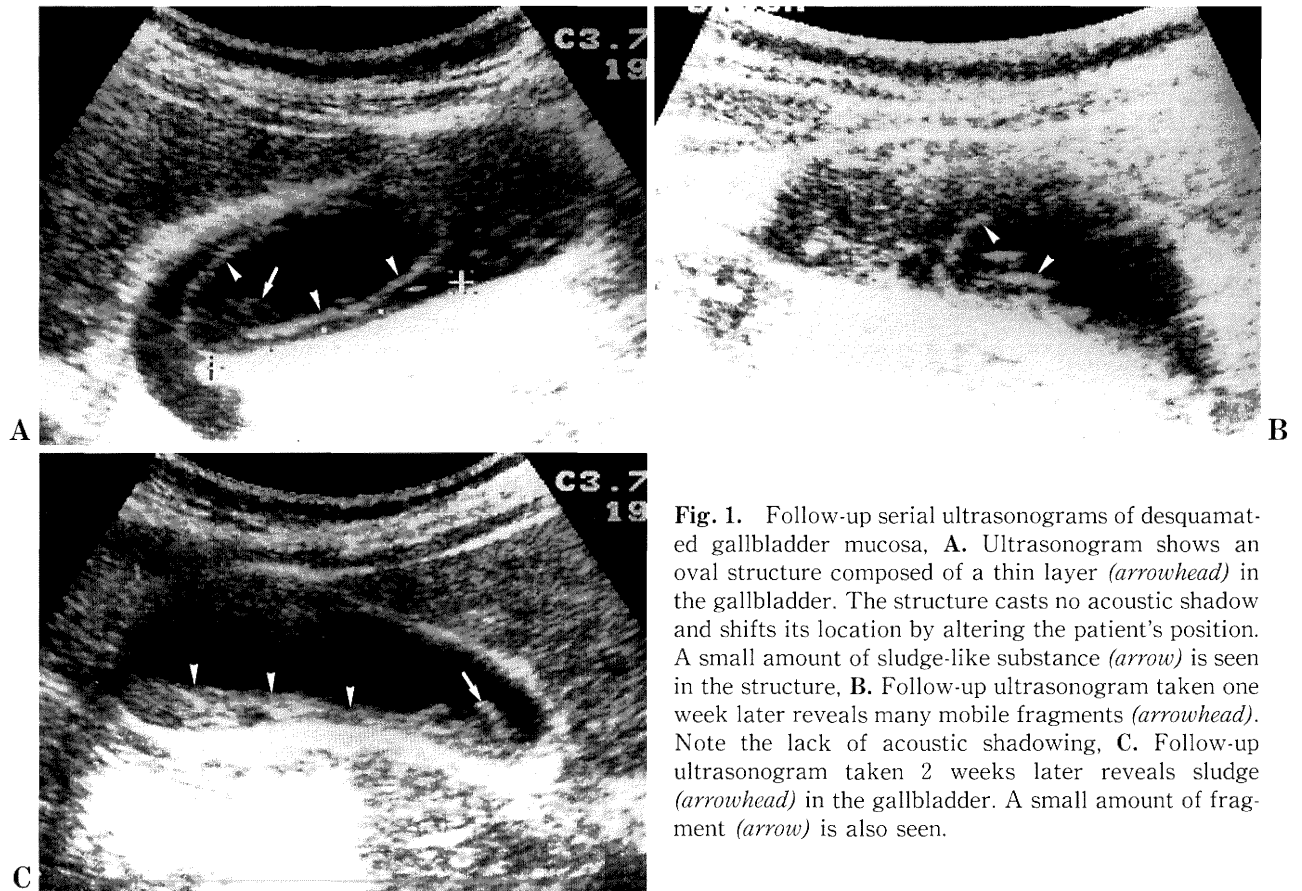


Fig. 1. Follow-up serial ultrasonograms of desquamated gallbladder mucosa, **A.** Ultrasonogram shows an oval structure composed of a thin layer (*arrowhead*) in the gallbladder. The structure casts no acoustic shadow and shifts its location by altering the patient's position. A small amount of sludge-like substance (*arrow*) is seen in the structure, **B.** Follow-up ultrasonogram taken one week later reveals many mobile fragments (*arrowhead*). Note the lack of acoustic shadowing, **C.** Follow-up ultrasonogram taken 2 weeks later reveals sludge (*arrowhead*) in the gallbladder. A small amount of fragment (*arrow*) is also seen.

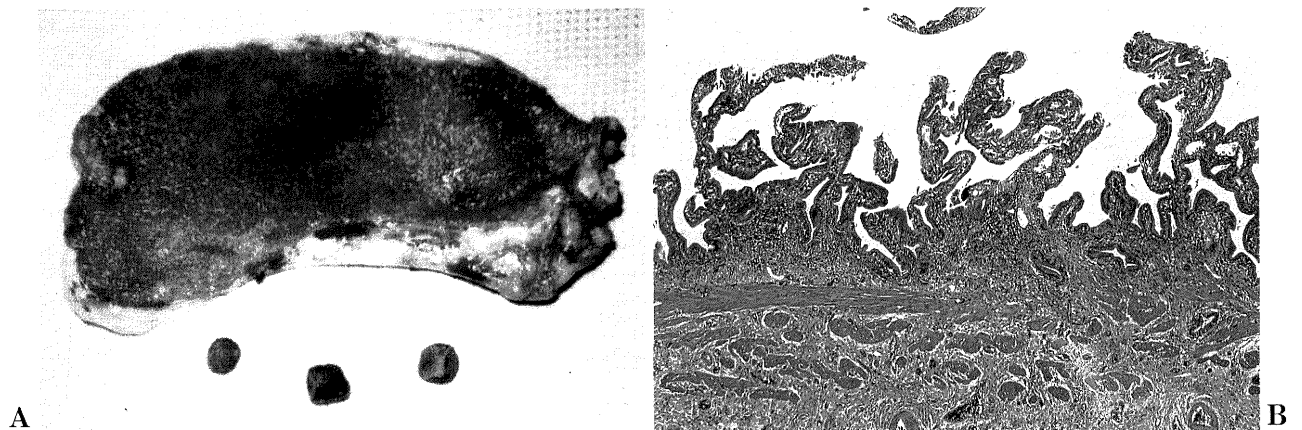


Fig. 2. Resected gallbladder and pathological findings, **A.** Resected specimen of the gallbladder and gallstones removed from the common bile duct, **B.** Pathological picture of the gallbladder mucosa. (HE stain, $\times 50$)

laboratory data fell within normal limits and the patient was free of complaints. Ultrasonography performed two weeks after the first one showed sludge in the lumen (Fig. 1C). Ultrasonography at four weeks after the first one revealed the disappearance of both the intraluminal structure and sludge.

Endoscopic retrograde cholangiopancreatography (ERCP), performed five weeks later, showed gallstones in the common bile duct, but no remarkable findings in the gallbladder. Two months after the first ultrasonography, cholecystectomy and choledocholithotomy were performed with the removal of three ductal stones. There were no stones and no sludge-like substance within the gallbladder. Grossly, the gallbladder showed a mild thickening of the wall and no remarkable changes in the mucosa (Fig. 2A). Microscopically, hyperplastic epithelial cells were in contact with a lamina propria that consisted of a mild proliferation of fibers. Furthermore, the lamina propria contained a infiltration of chronic inflammatory cells (Fig. 2B).

DISCUSSION

In acute gangrenous cholecystitis, necrosis and edema may involve all layers of the gallbladder. Pathologically, mucosal desquamation is occasionally seen in acute gangrenous cholecystitis. Ultrasonographic findings of the desquamated mucosa associated with cholecystitis were first reported by Wales.²⁾ This case showed multiple linear nonshadowing echoes in the gallbladder, and the histology confirmed partially detached necrotic mucosa. Our case also showed a nonshadowing oval structure composed of a thin linear echo, which is consistent with the desquamated mucosa. Early cholecystectomy is usually recommended in patients with desquamated necrotic mucosa.^{2,3)} However, our patient was successfully treated conservatively and thus, follow-up serial ultrasonograms were obtained. The first ultrasonography showed an oval, hollow struc-

ture consistent with desquamated mucosa. One week later, the desquamated mucosa was broken into fragments. Two weeks later, the broken necrotic mucosa was replaced by sludge. Although bile sludge is mainly composed of bilirubinate granules and cholesterol crystals,⁴⁾ it is likely that broken necrotic mucosa also shows a sludge echo. Four weeks later, the sludge disappeared both on sonography and on ERCP. In the resected specimen, the gallbladder mucosa appeared to be intact. This suggests that the time interval of 2 months between the first ultrasonography and the operation may have allowed the gallbladder epithelium to regenerate.⁵⁾ In conclusion, the experience of our case suggests that desquamated gallbladder mucosa may be broken into fragments and subsequently into bile sludge-like substance within a few weeks to finally disappear.

Acknowledgments. the authors thank Dr. Yoichi Ajioka of the First Department of Pathology, Niigata University School of Medicine, Niigata, for pathological comments.

REFERENCES

- 1) LoVerde LS, Mittelstaedt CA: Ultrasonography. In: Yamada T, Alpers DH, Owyang C, Powell DW, Silverstein FE (eds) *Textbook of Gastroenterology*, 2nd ed., JB Lippincott, Philadelphia 1995, p 2658-2687.
- 2) Wales LR: Desquamated gallbladder mucosa: unusual sign of cholecystitis. *AJR* **139**: 810-811, 1982.
- 3) Eggermont AM, Laméris JS, Jeekel J: Ultrasound-guided percutaneous transhepatic cholecystectomy for acute acalculous cholecystitis. *Arch Surg* **120**: 1354-1356, 1985.
- 4) Filly RA, Allen B, Minton MJ, Bernhoft R, Way LW: In vitro investigation of the origin of echoes within biliary sludge. *J Clin Ultrasound* **8**: 193-200, 1980.
- 5) Yoshioka H, Koyama K, Sato Y, Tanaka J, Matsushiro T, Yamazaki T: Cell kinetic studies on the gallbladder epithelium in patient with anomalous arrangement of pancreatobiliary duct. *Nippon Shokabikyō Gakkai Zasshi* **88**: 1089-1096, 1991.