

route in 196 patients, and the antethoracic route in 11 patients.

Clinical and pathologic records of these patients were reviewed to specify those cases in which a second primary cancer had developed in the gastric tube used as an esophageal substitute after esophagectomy. In such cases, clinicopathologic characteristics of the carcinoma of the reconstructed gastric tube (CRGT) were studied regarding the tumor stage of the preceding esophageal cancer, quality of esophagectomy, symptoms and diagnostic modalities of CRGT, interval between esophagectomy and detection of CRGT, treatment modalities for CRGT, and patient outcome.

The initial esophageal cancer and CRGT occurring after esophagectomy were staged according to the UICC-TNM classification⁹⁾. Depth of the tumor invasion of CRGT was determined pathologically in patients undergoing either endoscopic or surgical resection of CRGT and clinically in patients receiving nonsurgical treatment. For clinical determinations, tumors with a superficial appearance on endoscopy after barium ingestion were diagnosed as T1 CRGT (tumors invading the lamina propria or submucosa), and tumors with an exophytic or ulcerative appearance were diagnosed as T2- or more extensive-CRGT. Computed tomography was also used to stage CRGT. Based on these diagnostic criteria of local tumor extension, T1 CRGT was defined as early CRGT, and T2 or more extensive CRGT was defined as advanced CRGT. Histologic grading was determined based on findings from examination of an endoscopic biopsy or resected specimens. For localization of CRGT, the reconstructed gastric tube was divided into three portions: the upper, mid, and lower third. Tumor resection was defined as curative when the tumor was removed completely, and as palliative when the clearance of tumor was either grossly or microscopically incomplete.

Our technique for reconstruction in patients undergoing esophagectomy for esophageal cancer has been reported previously⁴⁾. In brief, the abdomen was entered through an upper midline incision. The stomach was mobilized and divided on the line from the entrance of the lowest branch of the left gastric artery into the lesser curvature to the highest point of the gastric fundus. The left gastric artery was ligated and divided at its base. The gastric tube, nourished by the right gastric and gastroepiploic vessels, was pulled up to the neck for the anastomosis with the remnant cervical esophagus. Before reconstruction, the stomach was examined by means of barium meal or endoscopy to detect the possible occurrence of a simultaneous carcinoma.

Follow-up data were available for all patients. Patients were evaluated by means of routine physical and laboratory examinations at 1- to 2-month intervals after initial esophageal tumor resection. Chest radiographs, ultrasound examination, and CT scans were performed annually to detect any possible occurrence of metachronous primary cancer or esophageal tumor recurrence. Endoscopic examination of the reconstructed gastric tube was performed every 2 or 3 years as a routine follow-up examination. For patients reporting any symptoms of the upper gastrointestinal tract, endoscopy was routinely performed in addition to the other follow-up examinations.

Survival time was calculated from the date of diagnosis of CRGT until date of death or most recent follow-up evaluation. Cumulative survival rates were examined using the Kaplan-Meier method. The equality of the survival curves was assessed using the log-rank test. A P value of less than 0.05 was regarded as significant.

RESULTS

Incidence of CRGT

Of the 705 patients who underwent esophagectomy for esophageal cancer followed by esophageal reconstruction using a gastric tube, a second primary cancer developed in a gastric tube in 14 (2.0%). The age of these patients ranged from 57 to 81 years, with a mean age of 68.8 years. There were 12 male and 2 female patients in this group. Nine of the patients had early CRGT, and the remaining five had advanced CRGT.

Tumor status of initial esophageal cancer

Initially, all of the 14 patients had a squamous cell carcinoma of the esophagus (well-to-moderately differentiated cancer in 13 and poorly differentiated cancer in 1). Of the 14 patients, 7, 4, and 3 had stage I, IIA, and III diseases, respectively. All patients underwent curative esophagectomy. None of the patients had any evidence of concomitant gastric cancer at the time of esophagectomy. The gastric tube had been pulled up to the neck via the retrosternal route in 12 patients and via the posterior mediastinal route in 2 patients.

Clinical features

The symptoms leading to the detection of CRGT are summarized in Table 1. None of the nine patients

Table 1. Clinicopathologic features of the patients with a carcinoma of the reconstructed gastric tube

Case No.	Age	Sex	Initial esophageal cancer			Carcinoma of the reconstructed gastric tube						
			TNM (Stage)	Route of reconstruction	Interval (Months)	Symptom	Stage	Depth of tumor	Site (Histology)	Treatment	Prognosis (Months)	Cause of death
1	79	M	T1N0M0 (I)	PM	198	None	T1N0M0	Early (Submucosal)	L (W)	EMR, Laser	A (79)	
2	61	M	T1N0M0 (I)	RS	22	None	T1N0M0	Early (Mucosal)	L (W)	Laser	D (7)	Perforation of gastric tube
3	65	M	T3N1M0 (III)	RS	91	None	T1N0M0	Early (Submucosal)	L (W)	Partial resection of gastric tube	A (63)	
4	69	M	T3N1M0 (III)	RS	28	None	T1N0M0	Early (Mucosal)	M (W)	Laser	D (34)	Esophageal cancer
5	68	M	T1N0M0 (I)	RS	47	None	T1N0M0	Early (Mucosal)	L (W)	EMR	A (24)	
6	65	M	T1N0M0 (I)	RS	43	None	T1N0M0	Early (Submucosal)	L (W)	EMR, Laser	A (55)	
7	57	M	T1N0M0 (I)	RS	81	None	T1N0M0	Early (Mucosal)	L (W) L (W)	EMR	A (44)	
8	81	F	T1N0M0 (I)	PM	106	None	T1N0M0	Early (Submucosal)	L (W) L (W)	None	A (24)	
9	64	M	T3N0M0 (IIA)	RS	84	None	T1N0M0	Early (Submucosal)	L (W)	Partial resection of gastric tube	A (20)	
10	57	M	T1N0M0 (I)	RS	60	Elevation of serum CEA	T3N0M0	Advance (T3)	M (P)	None	D (3)	Gastric cancer
11	75	F	T3N0M0 (IIA)	RS	24	Dysphagia	T2N0M0	Advance (T2)	L (W)	Total resection of gastric tube	D (0)	Sepsis, Multiple organ failure
12	63	M	T3N0M0 (IIA)	RS	120	Dysphagia	T3N0M0	Advance (T3)	M (P)	None	D (9)	Gastric cancer
13	79	M	T3N1M0 (III)	RS	34	None	T3N1M0	Advance (T3)	M (P)	Total resection of gastric tube	D (11)	Gastric cancer
14	80	M	T3N0M0 (IIA)	RS	108	Dysphagia	T3N0M0	Advance (T3)	L (W)	Chemo-radio therapy	A (1)	

Ps, Posterior mediastinal RS, Retrosternal; EMR, endoscopic mucosal resection; W, well differentiated adenocarcinoma; P, poorly differentiated adenocarcinoma; A, alive D, deceased.

with early CRGT had any symptoms attributed to CRGT, whereas four of the five patients with advanced CRGT developed symptoms and signs leading to the diagnosis of CRGT. Tumors were detected by means of follow-up endoscopic examination in all nine of the patients with early CRGT. Of the five patients with advanced CRGT, three had dysphagia, and one had an abnormal elevation of serum levels of a carcinoembryonic antigen, which led to the detection of CRGT.

The interval between initial esophagectomy and detection of CRGT ranged from 22 to 198 months (average, 75 months). Carcinomas developed in a reconstructed gastric tube more than 5 years after esophagectomy in 8 (57%) of the 14 patients.

Tumor status of CRGT

Double cancer development was found in two

patients with early CRGT. As a result, there were 16 tumors in total: 11 early and 5 advanced. Of the 11 early tumors, 6 were diagnosed as mucosal cancer, and 5 were diagnosed as submucosal cancer. Of the 16 tumors, 12 (75%) were located in the lower third and 4 were in the middle third of a reconstructed gastric tube. Metastasis to the perigastric lymph nodes was detected in only one patient with advanced CRGT. None of the patients with early CRGT had any evidence of lymph node metastasis. All of the 11 early tumors were histologically well-differentiated adenocarcinomas. Of the five advanced tumors, two were well-differentiated and three were poorly differentiated adenocarcinomas.

Treatment outcome

Of the nine patients with early CRGT, two were treated by laser ablation, four received endoscopic

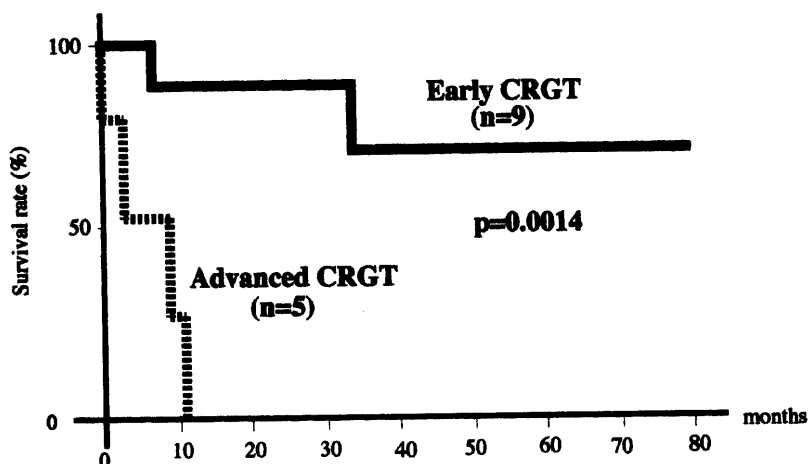


Fig. 1. Survival curves of the patients with early carcinomas of the reconstructed gastric tube (CRGT) and the patients with advanced CRGT as analyzed by the Kaplan-Meier method. There is a significant difference between the two survival curves ($P=0.0014$).

mucosal resection either alone or in combination with laser ablation, and two underwent partial resection of a reconstructed gastric tube. One of the patients with early CRGT refused any cancer treatment and has survived 20 months with CRGT after the diagnosis. Two patients in this group died after being treated for CRGT: one patient died from perforation of a gastric tube after laser treatment, and another patient died of recurrent esophageal cancer.

Of the five patients with advanced CRGT, two underwent total resection of the gastric tube followed by colonic esophageal replacement through the antethoracic route, and one received chemoradiotherapy because of the simultaneous occurrence of advanced oral cancer. Two patients did not receive any active treatment because of their poor performance status. Three patients in this group died as a result of CRGT, and one patient died from multiple organ failure resulting from sepsis 8 days after total removal of the reconstructed gastric tube.

The 5-year survival rate of the nine patients with early CRGT was 71% after the detection of CRGT, while none of the five patients with advanced CRGT survived more than one year after the diagnosis of CRGT. There was a significant difference between the survival curves of the two patient groups ($P=0.0014$; Fig. 1).

DISCUSSION

It is well known that patients with esophageal cancer often have synchronous and metachronous primary cancers developing in the extraesophageal organs⁵. The stomach is one of the most frequent organs in which primary cancer synchronously or metachronously develops in patients undergoing esophageal resection for esophageal cancer, particularly in Japan^{5,6}. Moreover, the stomach has been used most frequently as an esophageal substitute after esophagectomy. These facts imply that there is a potential risk that a second primary cancer will develop in the stomach when it is used as an esophageal substitute in patients who have undergone esophagectomy for esophageal cancer. Further, the long-term survival of patients with esophageal cancer has been significantly improved after extended radical esophagectomy^{4,7}, suggesting that there is an increased population surviving a long time after esophageal replacement with the stomach.

Formerly, the development of carcinomas in the reconstructed esophagus was believed to be rare in patients who had had esophageal resection. Akiyama et al. investigated the incidence of such carcinomas in a nationwide study using questionnaires and reported that 0.59% of all such carcinomas developed in the stomach¹. The incidence of a second primary cancer developing in the reconstructed gastric tube (CRGT) was 2.0% in our series, and Koyanagi et al. reported a similar incidence of CRGT². Further, both of the

cases of CRGT reported by Koyanagi et al. and 9 (64%) of the 14 cases reported here were early cancers invading the submucosa or more superficial layers of the reconstructed gastric tube.

In four patients in the current study, a carcinoma was detected in the gastric tube between 22 and 34 months after esophagectomy. Tsukuma et al. reported that 56 cases of gastric cancer remained in the early stage for 40 months in average⁸⁾, suggesting the possibility that these four carcinomas might have already existed as an occult cancer in the stomach and been undetectable in the preoperative endoscopic examination. In fact, two of the four tumors (case 2 and 4) were an endoscopically superficial flat type, and the detection of such tumors might be difficult. Careful preoperative endoscopic examination of the stomach is important to avoid leaving an occult carcinoma in the reconstructed gastric tube. In contrast, a carcinoma developed in the stomach more than 5 years after esophagectomy in 57% of the patients with CRGT. These results may suggest the necessity of endoscopic examination of the reconstructed gastric tube as a part of follow-up examination even in patients surviving more than 5 years after esophagectomy.

Postoperative endoscopic follow-up evaluation may be important in patients undergoing esophageal replacement with a gastric tube, because all of the nine cases of early CRGT were detected by regular endoscopic follow-up of every 2 or 3 years, even though all patients were asymptomatic. Similarly, tumors were incidentally detected on follow-up endoscopic examination in the two cases of early CRGT reported by Koyanagi et al.²⁾. In contrast, regular endoscopic follow-up was not carried out in any of the five patients with advanced CRGT. Early detection of CRGT is of particular importance for a favorable outcome, because the 5-year survival rate of the patients in our study with early CRGT was 71% after detection of the tumor, whereas none of the patients with advanced CRGT survived more than one year regardless of treatment.

The optimal treatment modality for this condition is debatable, particularly for patients with CRGT in whom the tumor is detected within 2 or 3 years after esophagectomy for esophageal cancer, as most cases of recurrent esophageal cancer occur within a few years after esophagectomy⁹⁾. Extensive surgery may be contraindicated in patients with CRGT in whom considerable risk of recurrence is expected after esophagectomy^{4,10)}. One of the patients in our study with early CRGT diagnosed 28 months after esophagectomy died of recurrent esophageal cancer. In patients surviving more than 5 years after eso-

phagectomy, a radical treatment modality may be indicated because the risk of recurrence of initial esophageal cancer is greatly decreased. Local tumor resection either endoscopically or surgically is recommended for patients with early CRGT because this modality involves minimal invasiveness, the reconstructed gastric tube is able to be preserved, and favorable outcome may be expected.

CONCLUSIONS

For the early detection of a second primary cancer in the reconstructed gastric tube, postoperative endoscopic examination may be an important component of a follow-up examination in patients who have undergone esophageal replacement with the stomach following esophagectomy for esophageal cancer. Local tumor resection either endoscopically or surgically is adequate, particularly in patients with early CRGT.

REFERENCES

- 1) Akiyama H, Nakayama K: Carcinomas developing in the reconstructed esophagus. *Int Adv Surg Oncol* 5: 145-161, 1982.
- 2) Koyanagi K, Ozawa S, Ando N, Shin C, Nakayama E, Takeuchi H, Hayashi K, Kitajima M: Case report: Metachronous early gastric carcinoma in a reconstructed gastric tube after radical operation for oesophageal carcinoma. *J Gastroenterol Hepatol* 13: 311-315, 1998.
- 3) Wittekind Ch, Sobin LH: "TNM classification of malignant tumors, 5th edn. Geneva: International Union Against Cancer (UICC)." Berlin Springer, 1997.
- 4) Nishimaki T, Suzuki T, Suzuki S, Kuwabara S, Hatakeyama K: Outcomes of extended radical esophagectomy for thoracic esophageal cancer. *J Am Coll Surg* 186: 306-312, 1998.
- 5) Katayanagi N, Muto T, Tanaka O, Suzuki T, Aizawa K, Nishimaki T, Tanaka Y, Muto I, Takeda N, Tanaka S, Suzuki S, Tanaka N, Yabusaki H, Ohmori K, Tada T, Suzuki S, Obinata I, Soga J: Study on esophageal cancer associated with other primary cancers. *Nippon Shokaki Geka Gakkai Zasshi* 24: 968-976, 1991.
- 6) Nagasawa S, Onda M, Sasajima K, Sasajima K, Takubo K, Miyashita M: Multiple primary malignant neoplasms in patients with esophageal cancer. *Dis Esophagus* 13: 226-230, 2000.
- 7) Nishimaki T, Tanaka O, Suzuki T, Aizawa K, Hatakeyama K, Muto T: Patterns of lymphatic spread in thoracic esophageal cancer. *Cancer* 74: 4-

- 11, 1994.
- 8) Tsukuma H, Oshima A, Narahara H, Morii T: Natural history of early gastric cancer. a non-concurrent, long term, follow up study. *Gut* **47**: 618-621, 2000.
- 9) Law SY, Fok M, Wong J: Pattern of recurrence after oesophageal resection for cancer: clinical implications. *Br J Surg* **83**: 107-111, 1996.
- 10) Nishimaki T, Suzuki T, Tanaka Y, Aizawa K, Hatakeyama K, Muto T: Intramural metastases from thoracic esophageal cancer: local indicators of advanced disease. *World J Surg* **20**: 32-37, 1996.