

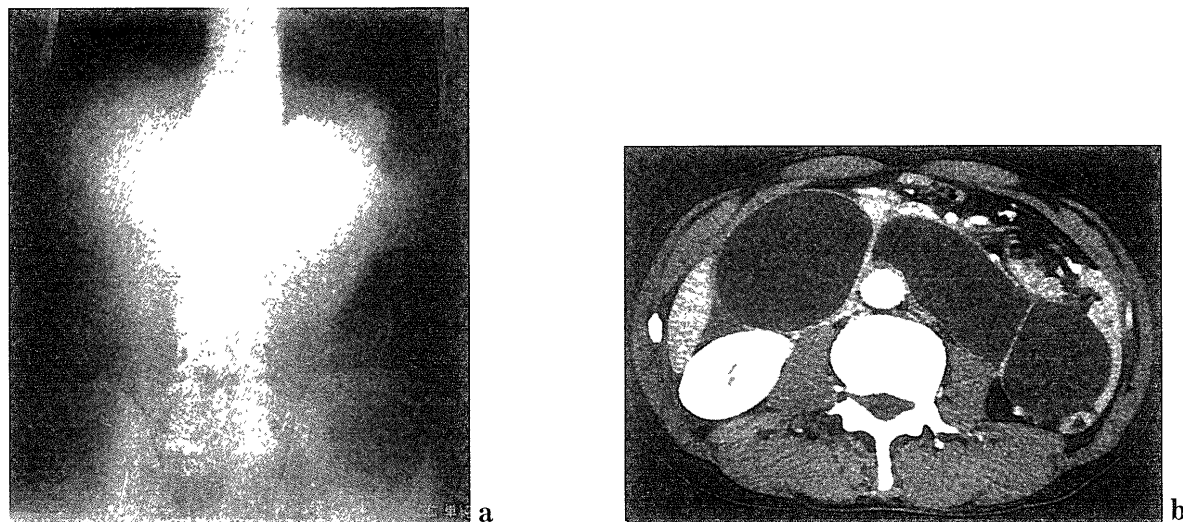Fig. 1. Plain abdominal X ray (a) and CT (b).

ly increased up to 1990 IU/ml. After reviewing the CT films again, which showed fluid density cystic tumors around the pancreas that were compatible with dilated duodenum, the patient was transferred to the Department of Surgery with a suspected diagnosis of afferent loop obstruction based on his past history. An upper gastrointestinal endoscopy was performed to determine the presence of malignant disease. It showed normal gastric mucosa in the remnant stomach, open efferent limb but an obstructed afferent limb, as shown in Fig. 2. The endoscope easily passed through the obstruction into the afferent limb and 1,100 ml of bilious intestinal juice was aspirated as shown schematically in Fig. 3. Thereafter, the patient was surgically explored. The extensively dilated afferent limb, which equaled multiple fluid density cystic tumors around the pancreas in CT, was located in the left abdomen. The cause of afferent loop obstruction was retro-anastomotic herniation of the afferent limb. The afferent limb was ischemic but not necrotic. Following the relief of the herniation, the color of the afferent limb became normal in vascularization and a resection was not required. Hence, only a side-to-side jejunostomy was performed. The postoperative course was uneventful and the patient was discharged on the 15th post-operative day. The patient has remained asymptomatic at 18 months follow-up.

Table 1. Laboratory findings on admission

White Blood Cell (/μl)	9350*
Red Blood Cell (/μl)	544 × 10 ⁴ *
Hemoglobin (g/dl)	12.0
Platlet (/μl)	42.5 × 10 ⁴ *
Total Protein (g/dl)	8.5*
GOT (IU/l)	19
GPT (IU/l)	12
ALP (IU/l)	256
LDH (IU/l)	171
γ-GTP (IU/l)	47
Total Bilirubin (mg/dl)	0.9
Amylase (IU/l)	360*
Elastase 1 (ng/dl)	1913*
BUN (mg/dl)	37.8*
Creatinine (mg/dl)	1.0
Na (mEq/l)	135
K (mEq/l)	4.0
Cl (mEq/l)	95

Asterisks indicate abnormal data.

DISCUSSION

Afferent loop obstruction is an uncommon complication whose rate of occurrence is reported as less than 1%^{1,2)}, after Billroth-II gastroenterostomy. In addition, this symptom-complex may occur anytime after surgery. Although half of the complications occur within a month after surgery, the remaining 50%

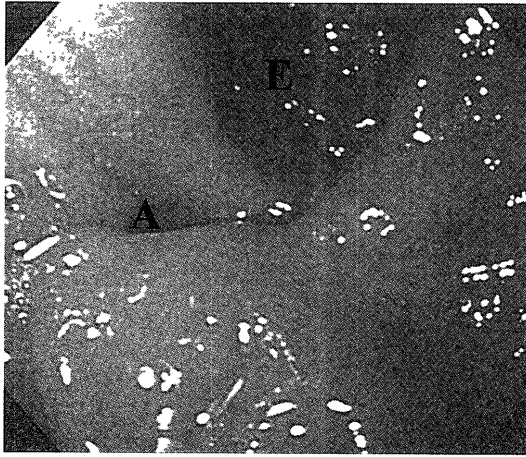


Fig. 2. Endoscopic examination at the gastrojejunostomy. The efferent limb is open but the afferent limb is obstructed. E, efferent limb; A, afferent limb.

occur after several years³⁾, long enough to overlook any relation to the previous surgery. For these reasons, afferent loop obstruction is sometimes diagnosed late. Acute afferent loop obstruction causes circulatory disturbance of the afferent limb, leads to its necrosis and thus can lead to perforation, resulting in severe peritonitis^{2-4,9)}, worsening the patient's prognosis. Hence, early diagnosis and prompt management of this surgical problem is critical, and thus awareness of this disease, inquiry of the patient's past history, and careful evaluation of the patient's condition are highly important.

For the diagnosis of afferent loop obstruction, plain X-ray film is usually of minimal value^{6,8)}. The distended afferent limb can be detected as tumor, unless the afferent limb does not contain gas. If the afferent loop contains gas, niveau will be observed and bowel obstruction will be diagnosed. Normally, a CT^{2,4,10-12)} and ultrasound examination^{8,12,13)} are effective diagnostically. They show uniformly sized, tubular water-density masses, which are identified crossing the midline between the aorta and the mesenteric vessels in normal course of the duodenum, with a thin smooth rim of soft-tissue density corresponding to the bowel wall. Differential diagnosis includes pancreatic pseudocysts, in which an increased plasma amylase level usually occurs. However, based on the anatomical location of the afferent limb and the past history of a Billroth-II gastroenterostomy, afferent loop obstruction should be readily suspected. Recently, magnetic resonance cholangiopancreatography¹⁴⁾ and hepatobiliary scintigraphy^{10,15)} have also been reported as useful modalities for the diagnosis of the

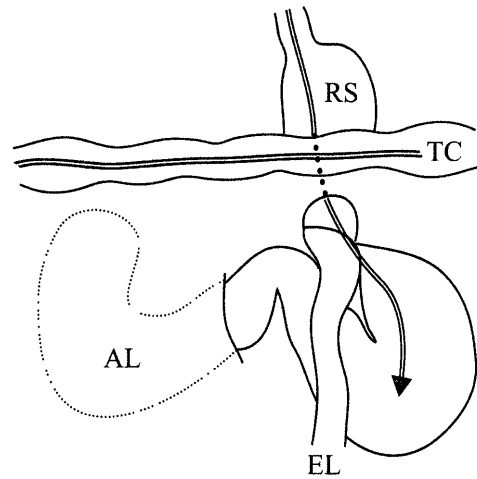


Fig. 3. Schematic representation of the retro-anastomotic hernia in our case. Arrow indicates an upper gastrointestinal endoscope inserted into the afferent limb. RS, remnant stomach; TC, transverse colon; D, duodenum; AL, afferent loop; EL, efferent loop.

afferent loop obstruction.

The causes of afferent loop obstruction are most commonly internal hernia, kinking, adhesion⁹⁾, cancer recurrence, and rarely a marginal ulcer or cancer from a remnant stomach^{6-8,16)}. Normally, the treatment of afferent loop obstruction, requires surgical management³⁾, and the presence of malignant disease requires a completely different surgical approach. For these reasons, in the case that afferent loop obstruction is suspected long after previous surgery, an upper gastrointestinal endoscopy should be performed to verify the presence of gastric cancer^{4,12)}. In our case, an upper gastrointestinal endoscopy did not show any malignancy in the remnant stomach but did show obstruction of the afferent limb. Furthermore, the endoscope was inserted into the obstructed afferent limb and the intestinal juice inside was drained, leading to a decrease in the pressure of the afferent limb, and preventing the progression of the intestinal ischemia to make the subsequent operation easier. Additionally, endoscopic catheter insertion into the afferent limb could temporarily relieve the symptoms¹⁷⁾. Thus an upper gastrointestinal endoscopy is a necessary examination not only for confirming the cause of the symptoms, but also as a therapeutic modality, and should be routinely performed for afferent loop obstruction.

In our case, we performed a side-to-side jejunojunctionostomy, which is an established procedure for treatment of this condition¹⁾. However, the retro-anastomotic space, which is formed anteriorly by the

afferent jejunal loop and gastric remnant, superiorly by the transverse mesocolon, posteriorly by the parietal peritoneum, and inferiorly by the ligament of Treitz in retro-colic route of Billroth-II reconstruction³⁾, was left open. Because retro-anastomotic hernia of efferent limb can also happen³⁾, closure of the retro-anastomotic space should additionally be considered. Thus, careful follow-up observation is needed in these patients.

In summary, we describe a case of afferent loop obstruction due to an internal hernia following Billroth-II gastroenterostomy. This condition may sometimes result in a poor outcome. However, prompt diagnosis with careful evaluation of the patient's past history, CT, ultrasound examination, and upper gastrointestinal endoscopy will lead to appropriate management.

Acknowledgments. We thank Dr. Ute Oestreicher and Dr. Michael M Meguid for their help in preparing this manuscript.

REFERENCES

- 1) Jordan GL: Surgical management of postgastrectomy problems. *Arch Surg* **102**: 251-259, 1971.
- 2) Furuta K, Mieno H, Isogaki M, Shimao H, Oomiya H, Kakita A, Hiki Y: Diagnosis and treatment of afferent loop obstruction. *J Jpn Surg Assoc* **55**: 2491-2498, 1994. (in Japanese with English abstract)
- 3) Rutledge RH: Retroanastomotic hernias after gastrojejunal anastomoses. *Ann Surg* **177**: 547-553, 1973.
- 4) Taylor AR, Russ PD, Lee RE, Weingardt JP: Acute afferent loop obstruction diagnosed with computed tomography: case report. *Can Assoc Radiol J* **50**: 251-254, 1999.
- 5) Mitty WF, Grossi C, Nealon TF: Chronic afferent loop syndrome. *Ann Surg* **172**: 996-1001, 1970.
- 6) Feiss JS, Plevy DJ, Luckman GS: A case of postgastrectomy afferent loop obstruction secondary to cancer of the stomach simulating pseudocyst of the pancreas. *Dig Dis* **20**: 995-998, 1975.
- 7) Gale ME, Gerzof SG, Kiser LC, Snider JM, Stavits DM, Larsen CR, Robbins AH: CT appearance of afferent loop obstruction. *Am J Roentgenol* **138**: 1085-1088, 1982.
- 8) Lee DH, Lim JH, Ko YT: Afferent loop syndrome: sonographic findings in seven cases. *Am J Roentgenol* **157**: 41-43, 1991.
- 9) Port M, Gelb A: Acute afferent loop syndrome simulating acute pancreatitis. *Am J Gastroenterol* **53**: 36-40, 1970.
- 10) Yao NS, Wu CW, Tiu CM, Liu JM, Whang-Peng J, Chen LT: Percutaneous transhepatic duodenal drainage as an alternative approach in afferent loop obstruction with secondary obstructive jaundice in recurrent gastric cancer. *Cardiovasc Intervent Radiol* **21**: 350-353, 1998.
- 11) Beveridge CJ, Zammit-Maempel I: Afferent loop obstruction: CT appearance of an unusual cause of acute pancreatitis. *Clin Radiol* **54**: 188-189, 1999.
- 12) Brown CD, Kraus JW: Afferent loop syndrome revisited: new emphasis on ultrasound and computerized tomography. *South Med J* **74**: 599-601, 1981.
- 13) Matsusue S, Kashihara S, Takeda H, Koizumi S: Three cases of afferent loop obstruction. The role of ultrasonography in the diagnosis. *Jpn J Surg* **18**: 709-713, 1988.
- 14) McKee JD, Raju GP, Edelman RR, Levine H, Steer M, Chuttani R: MR cholangiopancreatography (MRCP) in diagnosis of afferent loop syndrome presenting as cholangitis. *Dig Dis Sci* **42**: 2082-2086, 1997.
- 15) Muthukrishnan A, Shanthly N, Kumar S: Afferent loop syndrome. The role of Tc-99m mebrofenin hepatobiliary scintigraphy. *Clin Nucl Med* **25**: 492-494, 2000.
- 16) Diba AA, Grossman ET, Dolan EP: Afferent loop syndrome: a different picture. *Am J Gastroenterol* **66**: 72-75, 1976.
- 17) Paulsen O, Skjennald A, Osnes M: An endoscopic drainage procedure for afferent loop occlusion. *Gastrointest Endosc* **33**: 125-126, 1987.