

Three-dimensional Assessment of Femoral Head Coverage in Normal and Dysplastic Hips: A Novel Method

Dai Miyasaka^{a*}; Tomoyuki Ito^a; Norio Imai^a; Ken Suda^a; Izumi Minato^b; Yoichiro Dohmae^c; Naoto Endo^a

宮坂 大、伊藤知之、今井教雄、須田 健、湊 泉、堂前洋一郎、遠藤直人

^aDivision of Orthopaedic Surgery, Department of Regenerative and Transplant Medicine, Niigata University Graduate School of Medicine and Dental Science, Niigata 951-8510, Japan, ^bDepartment of Orthopaedic Surgery, Niigata Rinko Hosipital, Niigata 950-0051, Japan, and ^cDepartment of Orthopaedic Surgery, Shibata hospital, Niigata 957-8588, Japan.

Corresponding Author: Dai Miyasaka, MD.

**Division of Orthopaedic Surgery, Department of Regenerative and Transplant Medicine, Niigata University Graduate School of Medicine and Dental Science, Niigata, Japan;*

1-757 Asahimachi dori, Niigata City, Niigata 951-8510, Japan

Phone: +81-25-227-2272

Fax: +81-25-227-0782

E-mail: miyasakad@yahoo.co.jp

running title : Assessment of the Femoral Head Coverage

Abstract

The acetabular coverage of the femoral head has been assessed in two-dimensions as the projected covered area or the covered angle on plain radiographs. We present a novel method of the three-dimensional assessment of femoral head coverage obtained by evaluating the covered volume of the femoral head in both normal and dysplastic hips. We also assessed the covered angles on the vertical slices passing through the center of the femoral head. The mean covered volume of the femoral head was 57.4% in normal hips and 26.6% in dysplastic hips. In dysplastic hips, the L-CE, A-CE, and P-CE angles were 7.7°, 21.8°, and 95.8°, respectively, while the acetabular angle was 27.5°. In normal hips, the CE angles were 34.0°, 56.8°, and 109.4°, respectively, while the acetabular angle was 7.2°. Our study suggests the usefulness of a novel 3D assessment for acetabular coverage of the femoral head. This assessment provided the precise 3D information necessary to diagnose hip dysplasia and assess the deficiency of acetabular coverage in these patients. Moreover, we may detect a cut-off between normal and dysplastic hips in the 3D assessment by assessing a large number of dysplastic hips both morphologically and using the new assessment.

Keywords: hip dysplasia, three-dimensional imaging, femoral head coverage, acetabulum, patient positioning

Introduction

Joint-preserving surgeries have been performed on dysplastic hips to correct the acetabular coverage of the femoral head to be equivalent to that of normal hips [1, 2]. Estimations of the acetabular coverage of the femoral head prior to surgery have used various methods. One method measures the angle of coverage based on the center of the femoral head on a plain radiograph. This is represented by the center-edge (CE) angle of Wiberg [3] on an anteroposterior (AP) film or the vertical-center-anterior margin angle (VCA) from the false-profile views of Lequesne and de Seze [4]. Another method determines the covered angle on computed tomography (CT) slices passing through the center of the femoral head. The anterior and posterior acetabular sector angles were assessed in the axial plane by Anda *et al.* [5]. Janzen *et al.* [6] analyzed the CE angles in the vertical plane obtained by reconstructing three-dimensional (3D) CT scans at various rotations from 0° (anterior acetabular margin) through 90° (lateral acetabular margin) to 180° (posterior acetabular margin). All of these methods form a part of the evaluation of the acetabular coverage of the femoral head, but none of them can evaluate how the acetabular coverage in a dysplastic hip is lacking as a whole. Some researchers [7-9] have used the projected area to evaluate femoral head coverage by the acetabulum, but these estimations of the angle of coverage have only been two-dimensional (2D) approximations.

The acetabular coverage of the femoral head is usually evaluated in the supine or standing position. This has a significant effect on pelvic tilt [7, 8, 10] and makes it difficult to compare the acetabular coverage of the femoral head between normal and dysplastic hips. Morphological evaluation in a standardized position based on the anterior pelvic plane (APP) is critical to obtaining comparable data [7, 10].

We present a novel three-dimensional (3D) method of evaluating the acetabular coverage of the femoral head in a standardized position. This procedure provides the volume of the femoral head that is covered, not simply the projected or contact areas, using a 3D lower extremity alignment assessment system [11, 12, 13]. We also present the covered angles in vertically reconstructed CT slices through the center of the femoral head in a standardized position that has not previously been reported. Using this evaluation, the correlation between the covered angles and the covered volume of the femoral head was examined.

Materials and Methods

Subjects

This retrospective study was approved by our institutional review board. Informed consent for this study was obtained from all patients.

We identified 16 patients with hip dysplasia who had been treated with curved

periacetabular osteotomy between September 2007 and August 2010. Of all, 26 hips formed the dysplastic hip group with a CE angle $\leq 20^\circ$ of Wiberg on AP radiographs. The remaining six hips were eliminated from the study because they were unaffected and presented with a CE angle $> 20^\circ$ on AP radiographs. Three of the subjects were male and 13 were female. The presence of hip arthritis was evaluated by the Tönnis grade (8 patients were grade 0, fifteen were grade 1, and three were grade 2). The average age was 33.6 years (range 18–42 years) and the average body mass index (BMI) was 23.3 kg/m^2 (range $17.8\text{--}31.8 \text{ kg/m}^2$).

There were 29 healthy subjects in the normal hip group. We had examined them to determine normal lower extremity alignment in subjects ≥ 60 years of age using the 3D lower extremity alignment system in our institutional study [13]. Twelve of these subjects were male and 17 were female. Ten of the hips in the group were excluded due to a history of trauma. The remaining 48 hips were included in the normal hip group. No pain was present in the hips, knees, or lower back, and no history of trauma, radiographic abnormality, idiopathic necrosis of the femoral head, or rheumatoid arthritis was noted. The average age was 60 years (range 50–69 years) and the average BMI was 22.9 kg/m^2 (range $19.6\text{--}26.6 \text{ kg/m}^2$).

Measurement of the covered volume of the femoral head

The 3D lower extremity alignment assessment system is a method described by several researchers [11–13]. With the knees fully extended and the toes in the natural position,

subjects stood in a specially designed cassette holder with a mobile cover that holds two X-ray films at an angle of 120° to each other for simultaneous X-ray projections. Bi-planar AP and 60° oblique computed radiography (CR) projections in the standing position were obtained simultaneously (Fig. 1A). Then, multislice CT was performed at 1.0 mm thickness from the most proximal part of the pelvis to the most distal part of the femur for each subject using a helical scanner (Aquilion, Toshiba, Tokyo, Japan). Helical scanning was conducted at 120kVp and 150 mAs. Patients with dysplastic hips and healthy subjects were placed in a supine position for CT, with their hips and knees fully extended, patellae pointing straight up and the feet stabilized in a neutral position. After downloading data from the computed tomographs, in Digital Imaging and Communications in Medicine (DICOM, Rosslyn, VA, USA) format, to a personal computer, a 3D digital model of each pelvis and femur was reconstructed from CT data using 3D visualization and modeling software (Zedview, LEXI), and displayed as a point group. The reconstruction interval on coronal and sagittal images was 0.5 mm.

After the 3D pelvic and femoral models were obtained, several bony landmarks were digitized to establish reference points and anatomic coordinate systems using the Model Viewer (LEXI, Tokyo, Japan). For the pelvis, the anterior pelvic plane (APP) was obtained by digitizing both the anterior superior iliac spines (ASISs) and the pubic symphysis (PS). The

distal points of the ischium were also digitized. The origin of the pelvic anatomic coordinate system was defined as the PS. The Xp-axis was the transverse axis, defined as a parallel line from left ASIS to right ASIS. The Zp-axis was perpendicular to the X-axis in the plane of the APP. The Yp-axis was perpendicular to the APP (Fig. 2).

A similar procedure was used to digitize reference points for the femoral coordinate system, as defined by Sato *et al.* [11]. The center of the femoral head was obtained by approximating the spherical center in the coronal, axial, and sagittal planes. The center of the medial and lateral posterior femoral condyles was obtained by digitizing the three points on the contour of the medial and lateral femoral condyles and calculating the spherical approximation. The femoral X-axis was defined by the line connecting the centers of the spheres representing the medial and lateral posterior femoral condyles (positive laterally). The origin of the femoral coordinate system was defined as the midpoint between the centers of these posterior condylar spheres. The femoral Z-axis was defined as being perpendicular to the X-axis and in the plane formed by the X-axis and a line connecting the femoral origin and the center of the femoral head. The femoral Y-axis was defined as the cross product of the Z-axis and the X-axis (positive anterior) (Fig. 3).

We projected the 3D digital bone models of the pelvis and the femur onto biplanar CR images processed by 2D–3D matching software (HipCAS, Lexi). This software matched

silhouettes of the digital models to the contours of the respective CR bone images via 3D rotation and translation. This 2D–3D matching procedure allowed us to create a 3D view of the digital bone model that accurately reproduced the spatial relationship between the pelvis and the femur at the time of CR projection (Fig. 1B), and automatically calculated the various alignment parameters. In this study, we measured the pelvic flexion angle defined by the angle between the Yp-axis of the pelvic coordinate system and the CR table with the patient standing. The anterior orientation of the Yp-axis was defined as flexion (positive angle), the posterior orientation was defined as extension (negative angle), and the neutral position (0°) was defined as perpendicular to the CR table.

All assessments of the femoral head coverage in this study were performed in the standardized position. The standardized position was with the APP was perpendicular to the CR table and the Xp axis of the pelvis parallel to the CR table. The covered area was defined as the area of the femoral head medial to the line connecting the anterior and posterior edges of the acetabulum (Fig. 4). This definition was applied to the axial slice (0.5 mm, vertical to the APP) of the reproduced 3D model of the pelvis and the femur and to each cranial slice of the femoral head center. The percentage covered volume of the femoral head was automatically calculated from the ratio of the covered area (Cn) to the area of the femoral head (Fn) in each axial slice in which the APP was parallel to the Xp–Zp plane in the pelvic

coordinate system (Fig. 5):

The percentage covered volume of the femoral head (%)

= covered volume / femoral head volume

$$= (\sum C_n \times 0.5\text{mm}) / (\sum F_n \times 0.5\text{mm}) \times 100$$

We measured also the lateral-center edge angle (L-CE angle) which indicated the lateral coverage of the acetabulum [6], and the acetabular angle, which indicated the lateral tilt of the loading area of the acetabulum [14] in the coronal plane passing through the femoral head center (Fig 6A, 6B). This coronal plane was parallel to the APP. We also measured the anterior-center edge angle (A-CE angle) which indicated the anterior coverage of the acetabulum [6] and the posterior-center edge angle (P-CE angle), which indicated the posterior coverage of the acetabulum [6] in the sagittal plane (Fig. 6C). This sagittal plane was vertical to the APP.

Statistical analysis

Statistical analysis was performed using SPSS version 18.0 software (SPSS, Chicago, IL). All tests were considered statistically significant for values of $p < 0.05$.

All measurements were repeated by an independent observer in order to test the reproducibility of this method. The spherical approximation of the femoral head center and the covered volume of the femoral head were measured twice in all normal and dysplastic

hips. Intra-observer analysis of these methods was performed using the paired *t*-test.

The covered volume of the femoral head was compared between normal and dysplastic hips using the independent *t*-test, assuming an unequal variance.

Correlation analysis was performed between the L-CE, A-CE, P-CE, and acetabular angles. The multiple regression analysis in normal hips was performed by deciding the covered volume of the femoral head with the bound variable and the CE angles with free variables.

Results

Reproducibility

Intra-observer repeatability of measurements was acceptable for the covered volume of the femoral head ($R=0.952$) and for the coordinate of the femoral head center ($R_x=1.000$, $R_y=1.000$, $R_z=0.999$) (Table 1).

The covered volume of the femoral head in the standardized position

In normal hips, the mean covered volume of the femoral head was 57.4% (95% confidence interval (CI) 53.0-60.7). In dysplastic hips, the mean covered volume of the femoral head was 26.6% (independent *t*-test, $p<0.001$; 95% CI 23.8-29.3).

Assessment of the femoral head coverage in slices passing through the femoral head in the

standardized position

In normal hips, the mean L-CE angle was 34.0° (95% CI 31.8-36.1), the mean A-CE angle was 56.8° (95% CI 54.3-59.3), the mean P-CE angle was 109.4° (95% CI 104.7-114.1), and the mean acetabular angle was 7.2° (95% CI 5.6-8.7). The correlation coefficients between these angles and the covered volume of the femoral head were 0.776, 0.596, 0.526, and -0.571 , respectively. In dysplastic hips, the mean L-CE angle was 7.7° (95% CI 4.0-11.4), the mean A-CE angle was 21.8° (95% CI 13.4-30.3), the mean P-CE angle was 95.8° (95% CI 86.6-105.0), and the mean acetabular angle was 27.5° (95% CI 24.9-30.2). A comparison of these angles between normal and dysplastic hips is presented in Table 2. The correlation coefficients between these angles and the covered volume of the femoral head were 0.600, 0.570, 0.451, and -0.479 , respectively. The multiple regression analysis between the covered volume of the femoral head and these CE angles in normal hips is presented in Table 3.

Pelvic flexion angle in the standing position

In dysplastic hips, the mean pelvic flexion angle was 2.9° (95% CI -0.8 - 6.6 , range -9.94 - 13.88). In normal hips, the mean pelvic flexion angle was 2.3° (independent t -test, $p=0.903$; 95% CI 0.6 - 3.9 , range -3.71 - 7.65).

Discussion

When an acetabular osteotomy for patients with dysplastic hips is planned but the extent of the dysplasia is indistinct, we need to accurately assess the acetabular coverage of the femoral head. We present a novel 3D estimation method for evaluating the volume of acetabular coverage of the femoral head in a standardized position. This is distinctly different from the projected area or contact area reported by past researchers. We investigated the covered angle [6] or the acetabular angle [14] on vertical slices passing through the femoral head center in a standardized position, and the relationship between the covered volume of the femoral head and these angles. Assessing the covered volume of the femoral head allowed us to determine the global insufficiency of acetabular coverage in dysplastic hips and to identify the affected regions using vertical slices of the reconstructed model.

Some researchers [8, 9, 15] have evaluated the projected 2D area as the acetabular coverage of the femoral head. Konishi and Mieno [8] described the normal (mean) projected area as 79% in men and 77% in women using plain AP radiographs. De Kleuver *et al.* [16] described that it was 53% preoperatively in dysplastic hips, but improved to 70% after triple osteotomy. Dandachli *et al.* [7] described the mean coverage of the femoral head as 73% in normal hips and 51% in dysplastic hips. However, we need to consider whether the projected area reflects the volume of the femoral head for the weight-bearing zone of the acetabulum, or the contact area between the acetabulum and the femoral head. Even if the projected area

does correlate to the volume or contact area, it may be overestimated because the anterior and posterior deficiencies of femoral head coverage are underestimated. These 2D images lack 3D information, making it difficult to accurately quantify the relationship [17, 18]. Our study provides a 3D assessment parameter using the covered volume of the femoral head, which has not been reported previously. Our results showed that the mean covered volume was 57.4% in normal hips and 26.6% in dysplastic hips. The covered volume in dysplastic hips was approximately half of that in normal hips, and the difference between the coverage of both hips differed dramatically from past studies [7, 8]. This technique may provide a more detailed estimation than previous methods.

Some observers have suggested that the pelvic flexion angle may affect the measurements of acetabular coverage. Siebenrock *et al.* [19] recommended neutral pelvic positioning for standardization in anatomical and morphological studies. Dandachli *et al.* [7] and Fujii *et al.* [10] evaluated the acetabular coverage of the femoral head based on the APP using 3D-CT. Our study showed that the maximum pelvic flexion angle relative to the APP in a standing position was 13.88° and the minimum was -9.94°. We also think it is necessary to morphologically evaluate the acetabular coverage, because variation of the pelvic flexion angle results in inaccurate data when comparing normal and dysplastic hips.

Though it is possible to objectively assess the acetabular coverage in a standardized

position, the relative relationship between the femur and the pelvis is based on plain radiograph assessment in both supine and standing positions. In contrast, CTs are taken only in the supine position. Troelsen *et al.* [20] reported slight medialization and caudalization of the femoral head when repositioning a patient from supine to standing during an AP pelvic radiograph. The assessment of the acetabular coverage may be affected by the pelvic tilt and the difference in the femoral head center between supine and standing positions. Moreover, subjects with dysplastic hips experience pain while standing but not while supine. We evaluated the acetabular coverage in standardized position using the relative relationship between the pelvis and femur in the standing position.

This study has one limitation. The area of the femoral head includes the greater trochanter, meaning that measurements of the covered volume may be inaccurate in patients with coxa vara. However, there was no subject who participated in our study because the femur was adducted in the standing position.

In conclusion, our study described a novel 3D assessment for acetabular coverage of the femoral head. The covered volume of the femoral head and the covered angles passing through the femoral head center, which were evaluated in a standardized position, gave us the necessary information for precise evaluation of the acetabular coverage deficiencies of

dysplastic hips. We found that the mean covered volume of the femoral head was 57.4% in normal hips and 26.6% in dysplastic hips.

References

1. Ganz R, Klaue K, Vinh TS and Mast J: A new periacetabular osteotomy for the treatment of hip dysplasia: technique and preliminary results. Clin Orthop Relat Res (1988) 232: 26-36.
2. Naito M, Shiramizu K, Akiyoshi Y, Ezoe M and Nakamura Y: Curved periacetabular osteotomy for treatment of dysplastic hip. Clin Orthop Relat Res (2005) 433: 129-135.
3. Wiberg G: Shelf operation in congenital dysplasia of the acetabulum and in subluxation and dislocation of the hip. J Bone Joint Surg Am (1953) 35: 65-80.
4. Lequene M and de Seze S: Le faux profil du bassin: Nouvelle incidence radiographique pour l'etude de la hanche. Son utilite dans les dysplasies et les differentes coxopathies. Rev Rhum (1961) 28: 643-652 in French.
5. Anda S, Terjesen T, Kvistad KA and Svenningsen S: Acetabular angles and femoral anteversion in dysplastic hips in adults: CT investigation. J Comput Asisst Tomogr (1991) 15: 115-120.
6. Janzen DL, Aippersbach SE, Munk PL, Connell DG, Garbuz D, Werier J and Duncan CP: Three-dimensional CT measurement of adult acetabular dysplasia: technique, preliminary results in normal subjects, and potential applications. Skeletal Radiol (1998) 27: 352-358.
7. Dandachli W, Kannan V, Richards R, Shah Z, Hall-Craggs and Witt J: Analysis of cover

- of the femoral head in normal and dysplastic hips. J Bone Joint Surg Br (2008) 90: 1428-34.
8. Konishi N and Mieno T: Determination of acetabular coverage of the femoral head with use of a single anteroposterior radiograph: A new computerized technique. J Bone Joint Surg Am (1993) 75: 1318-1333.
 9. Klaue K, Wallin A and Ganz R: CT evaluation of coverage and congruency of the hip prior to osteotomy. Clin Orthop Relat Res (1988) 232: 15-25.
 10. Fujii M, Nakashima Y, Yamamoto T, Mawatari T, Motomura G, Matsushita A, Matsuda S, Jingushi S and Iwamoto: Acetabular retroversion in developmental dysplasia of the hip. J Bone Joint Surg Am (2010) 92: 895-903.
 11. Sato T, Koga Y, Omori G. Three-dimensional lower extremity alignment assessment system: application to evaluation of component position after total knee arthroplasty. J Arthroplasty (2004) 19: 620-628.
 12. Kobayashi K, Sakamoto M, Tanabe Y, Ariumi A, Sato T, Omori G and Koga Y: Automated image registration for assessing three-dimensional alignment of entire lower extremity and implant position using bi-plane radiography. J Biomech (2009) 42: 2818-2822.
 13. Ariumi A, Sato T, Kobayashi K, Koga Y, Omori G, Minato I and Endo N:

- Three-dimensional lower extremity alignment in the weight-bearing standing position in healthy elderly subjects. *J Orthop Sci* (2010) 15: 64-70.
14. Tönnis D: Congenital dysplasia and dislocation of the hip in children and adults. Berlin Heidelberg New York: Springer-Verlag (1987).
 15. Ogata S, Moriya H, Tsuchiya K, Akita T, Kamegaya M and Someya M: Acetabular cover in congenital dislocation of the hip. *J Bone Joint Surg Br* (1990) 72: 190-196.
 16. de Kleuver M, Kapitein PJ, Kooijman MA, van Limbeek J, Pavlov PW and Veth RPH: Acetabular coverage of the femoral head after triple pelvic osteotomy: no relation to outcome in 51 hips followed for 8–15 years. *Acta Orthop Scand* (1999) 70: 583-588.
 17. Sakai T, Nishii, T, Sugamoto K, Yoshikawa H and Sugano N: Is vertical-center-anterior angle equivalent to anterior coverage of the hip. *Clin Orthop Relat Res* (2009) 467: 2865-2871.
 18. Ito H, Matsuno T, Hirayama T, Tanino H, Yamanaka Y and Minami A: Three-dimensional computed tomography analysis of non-osteoarthritic adult acetabular dysplasia. *Skeletal Radiol* (2009) 38: 131-139.
 19. Siebenrock K, Kalbermatten D and Ganz R: Effect of pelvic tilt on acetabular retroversion: a study of pelvis from cadavers. *Clin Orthop Relat Res* (2003) 407: 241-248.
 20. Troelsen A, Jacobsen S, Romer L and Soballe K: Weightbearing anteroposterior pelvic

radiographs are recommended in DDH assessment. Clin Orthop Relat Res (2008) 466:813-819.

Figure Legends

Fig. 1. Bi-planar AP and 60° oblique computed tomography in the standing position (A). The 3D bone models projected onto biplanar CR images by matching silhouettes of the digital models to the contours of the respective CR bone images via 3D rotation and translation (B).

Fig. 2. The pelvic 3D bone model with the 3D reference coordinate system. The origin of the pelvic anatomic coordinate system was defined as the pubic symphysis. The APP was obtained by digitizing both the ASISs and pubic symphysis.

Fig. 3. The femoral 3D bone model with the 3D reference coordinate system. The origin of the femoral anatomic coordinate system was defined as the midpoint between the centers of the femoral posterior condylar spheres.

Fig. 4. The covered area (arrows) in the medial part of the line connecting the anterior edge of the acetabulum with the posterior edge on a slice vertical to the APP in (A) a dysplastic hip and (B) a normal hip.

Fig. 5. Reconstructed 3D model of the covered volume of the femoral head in the acetabulum and the covered volume into the superior half of the femoral head in a dysplastic hip (A) and a normal hip (B). The covered volume of the femoral head (%) = the covered volume / the entire volume of the superior half of the femoral head.

Fig. 6. Measurement of the covered angles on slices passing through the center of the femoral

head, determined by the reconstructed 3D model of the pelvis and femur in the standardized position. (a) L-CE angle on the coronal plane parallel to the APP. (b) The acetabular angle on the coronal plane. (c) A-CE angle and P-CE angle on the sagittal plane vertical to the APP.

Table 1 Intra-observer variability in measurements of the femoral head center.

Statistic in two measurements	Femoral head center coordinates		
	X-coordinate (mm)	Y-coordinate (mm)	Z-coordinate (mm)
Mean differences	0.08	-0.03	0.08
SD	0.34	0.23	0.39
Minimum to maximum	-0.94 to 0.42	-0.45 to 0.45	-0.79 to 0.47
P-value	<0.001	<0.001	<0.001

Table 2 Comparison of the covered volume of the femoral head, L-CE angle, A-CE angle, P-CE angle and Acetabular angle (AA) for dysplastic hips (D) and normal hips (N).

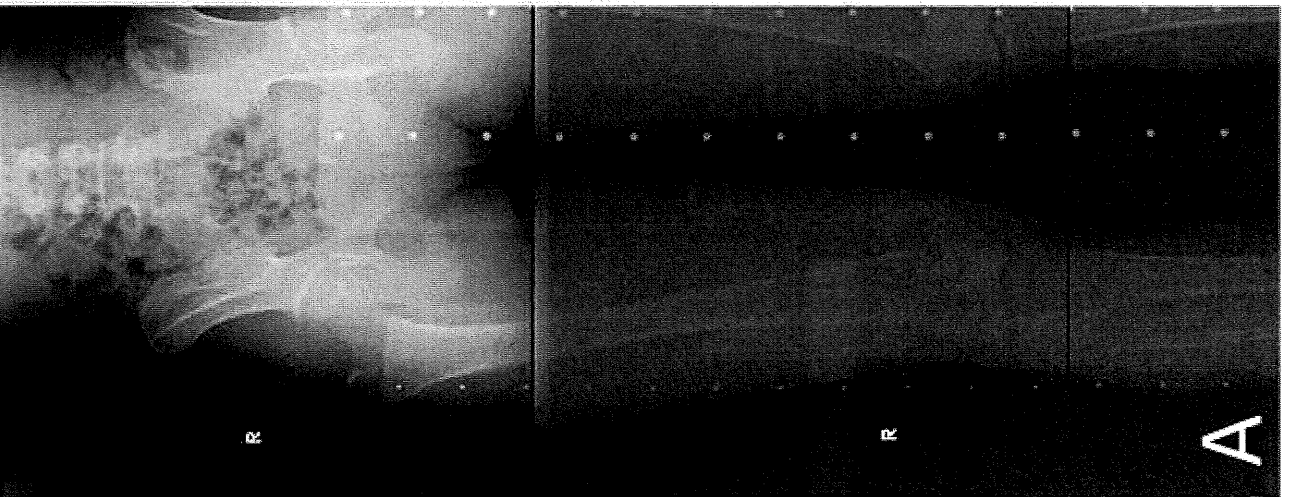
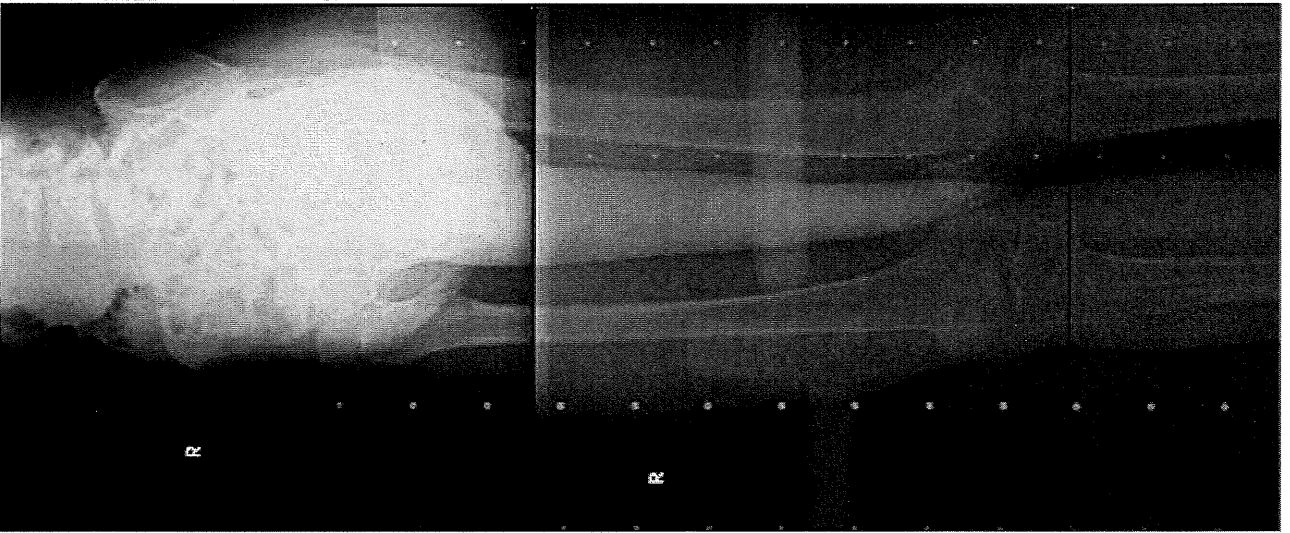
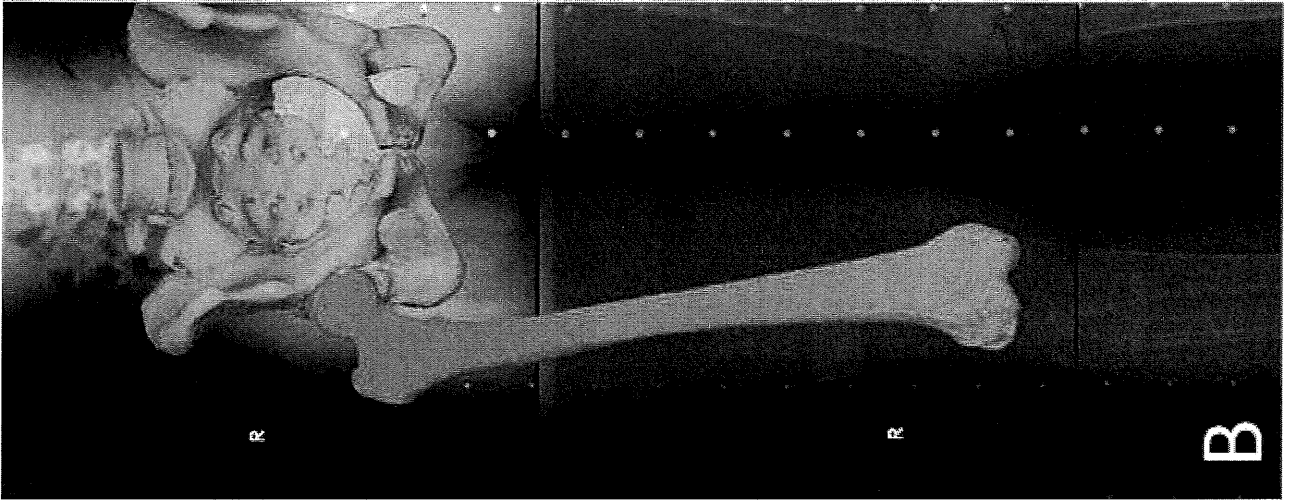
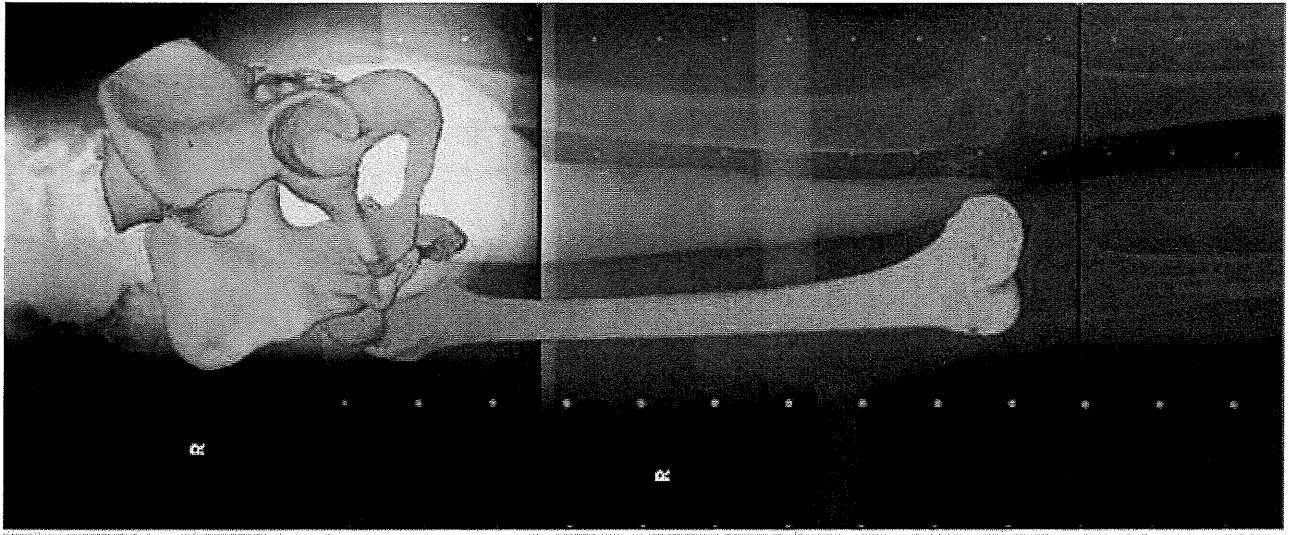
	Covered volume of the femoral head (%)				L-CE (°)		A-CE (°)		P-CE (°)		AA (°)	
	D	N	D	N	D	N	D	N	D	N	D	N
Mean	26.6	57.4	7.7	34.0	21.8	56.8	95.8	109.4	27.5	7.2		
SD	6.9	8.9	9.2	7.3	21.0	8.6	22.7	16.2	6.6	5.3		
Maximum	39.4	75.4	19.9	51.1	45.6	75.4	136.8	151.5	41.7	20.0		
Minimum	12.2	41.8	-10.0	22.0	-34.7	39.3	50.5	75.4	14.4	-6.0		
P-value	<0.001		<0.001		<0.001		0.004		<0.001			

Table. 3 Multiple regression analysis in the normal hip group: P<0.001, R²=0.728

	Fixed number	L-CE angle	A-CE angle	P-CE angle
Non-standardized partial regression coefficient	-4.446	0.532	0.409	0.187
Standardized partial regression coefficient		0.428	0.377	0.336

Covered volume of the femoral head (dependent variable)

$$= -4.446 + 0.532 \times (\text{L-CE angle}) + 0.409 \times (\text{A-CE angle}) + 0.187 \times (\text{P-CE angle})$$



lt.ASIS

rt.ASIS

APP

Pubic symphysis



Z

X

Y

