

Case Report

The early treatment of unusual severe ectopic eruption of the bilateral maxillary canines in a young Japanese girl: A case report

Sachiko Hayashi-Sakai*¹ and Yo Taguchi*²

*¹ Pediatric Dental Clinic of Niigata University Medical and Dental Hospital,

*² Division of Pediatric Dentistry, Department of Oral Health Science, Course for Oral Life Science, Niigata University Graduate School of Medical and Dental Sciences
2-5274 Gakkocho-dori, Chuo-ku, Niigata 951-8514, JAPAN

Abstract The purpose of this report was to describe an unusual severe ectopic eruption of the bilateral maxillary canines in a young patient aged 7 years and 8 months and to discuss the effects of early intervention such as extraction of the predecessors and fenestration of the affected canines. The patient was referred to the author's clinic for a consultation regarding bilateral ectopically erupting maxillary canines with an ectopic maxillary right first molar. After improvement of the first molar, the affected canines were fully erupted and aligned in occlusion 3 years and 7 months after the extraction of primary canines. Before treatment, the findings on the orthopantomogram were as follows, there was no direct cause, both canine tooth germs were situated in very high positions, and the cusp tips of both canines were not overlapped with the roots of the adjacent lateral incisors (Sector 1). The maxillary left canine impacted horizontally in a mesio-distal direction (axial angulation: 90 degrees) could be successfully guided to eruption by early intervention such as the extraction of predecessors and three fenestrations. Even in severe ectopic cases, therefore, it is considered that traction may be postponed until no effect of fenestration can be detected in cases of early discovery and intervention when the crown top is situated in Sector 1.

Keywords

Early treatment,
Ectopic eruption,
Eruption disturbance,
Maxillary canines

Introduction

Pediatric dentists often encounter eruption disturbances of permanent teeth. These conditions include various types of eruption disturbances such as ectopic eruption, delayed eruption or impaction, often accompanied by abnormal direction and/or position, caused by several systemic diseases or local factors. The maxillary central incisor has been reported as the most frequently affected permanent tooth in Japanese children, followed by eruption disturbance of the maxillary canines, which constitutes approximately 15.4% of all kinds of permanent teeth except the third molars¹⁾.

In general, ectopic eruption of the maxillary permanent canines is found in 1.5% to 2.0% of children during the mixed dentition period²⁻⁴⁾ and, 75% of these cases are derived from an idiopathic abnormal direction and/or position⁵⁾. The prevalence of the ectopically erupting maxillary canines has been reported to be significantly higher in females than in males⁶⁾. Unilateral occurrence is the most common (85%), and bilateral ectopic eruption is rare⁵⁾.

An early diagnosis is essential to improving ectopically erupting maxillary canines. It is well known that it is the first choice for treatment of them to extract the predecessor after eruption of anterior teeth. However, Kurol *et al.*⁶⁾ have suggested that extraction of the primary canines might show less favorable results with ectopic permanent canines located in a horizontal position high up in the alveolar

Received on September 1, 2008

Accepted on December 3, 2008

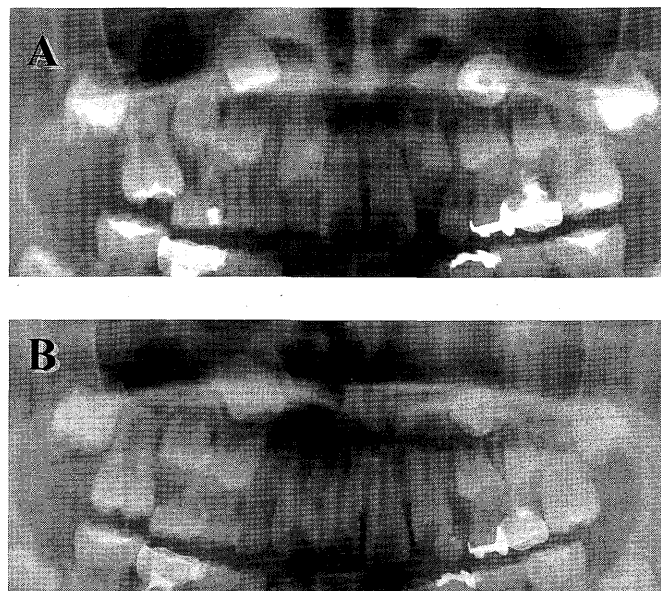


Fig. 1 Orthopantomograms at the first visit, aged 7 years and 8 months, (A) and at the revaluation, aged 8 years 5 months (B)

process and in older individuals. They indicated that a more favorable outcome would be obtained when primary canines could be extracted following early diagnosis in young individuals aged 10–13 years⁶. An early diagnosis is not always feasible because the axial direction and/or position of a canine may already be abnormal, even in young children. There have been few studies on the methods of treating ectopic maxillary canines exhibiting a critical condition in young patients.

The purpose of the present report is to describe an unusual severe ectopic eruption of the bilateral maxillary canines in a young patient aged 7 years and 8 months, and to discuss the effects of early intervention such as extraction of the predecessors and fenestration of the affected canines.

Case Report

The findings at the first visit and the treatment plan

A 7-year, 8-month-old Japanese girl was referred to the Pediatric Dental Clinic of Niigata University Medical and Dental Hospital from a private dental clinic for a consultation regarding ectopic eruption of bilateral maxillary canines. On an orthopantomogram, bilateral eruption disturbance of the maxillary canine was detected (Fig. 1A). Her mother had once had an impacted tooth, for which kind and condition

were unknown, although she had never suffered from systemic disease and dental trauma.

The patient's maxillary primary canines, which had not received root canal treatment, remained without root resorption and apical lesion. The maxillary right first molar also showed ectopic eruption. It was decided to postpone the treatment of the affected bilateral maxillary canines until improvement of the eruption disorder of the maxillary right first molar and to then reevaluate the condition of the affected canines.

The findings at the revaluation

It took 9 months for maxillary right first molar to be aligned within the dental arch. At 8 years and 5 months of age, both canines were re-examined and evaluated according to the criteria of the previous reports^{5,7,8}. The findings on the orthopantomogram were as shown in Fig. 1B.

1. There was no direct cause that obstructed the eruption path of the affected canines such as an odontoma, a dentigerous cyst or a supernumerary tooth in the canine and the bilateral adjacent regions.
2. The axial angulation to the midline (a) and the vertical length to the occlusal line (d) of the affected canines were measured (Fig. 2A). The vertical lengths to the occlusal line of maxillary right and left canines were 27 mm and 33 mm

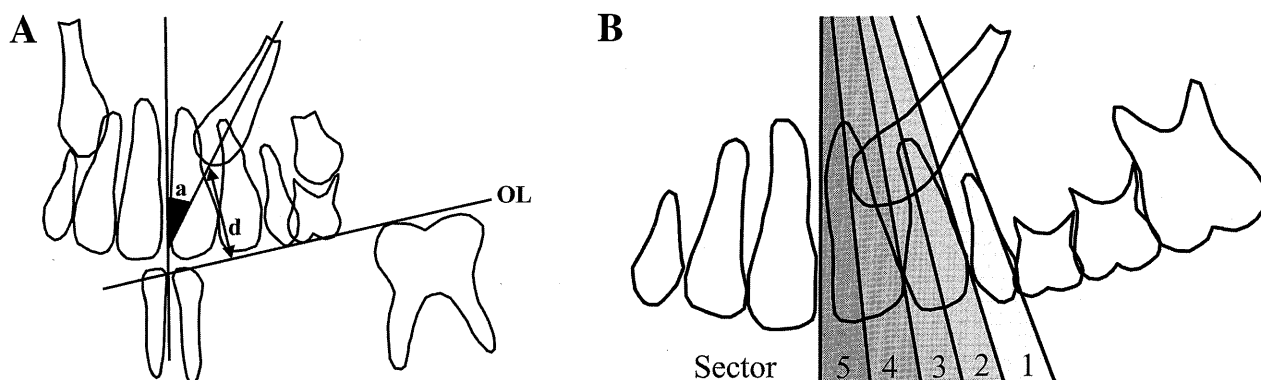


Fig. 2 Measurement of the crown top of ectopic canines on the orthopantomogram

A, The vertical length to occlusal line (OL) can be measured in (d) millimeters, and the axial angulation to midline in (a) degrees. B, Sector is defined as the position of the crown top overlapping the adjacent lateral or central incisor root. In Sector 1, on the orthopantomogram, the cusp tip of the affected canine was situated distally to the root of the lateral incisor. The affected canine in Sector 2 was overlapped on the distal half of the root of the lateral incisor and that in Sector 3 was on the mesial half of them. In the same way, Sectors 4 and 5 were defined by the position of the canine on the root of the central incisor. Ericson and Kurol's method⁹⁾ was modified.

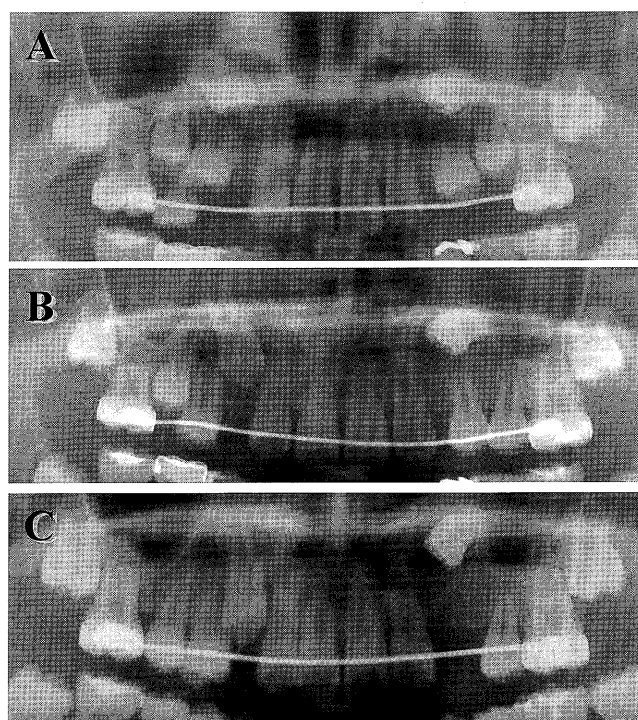


Fig. 3 Orthopantomograms at the first fenestration, aged 9 years and 0 months (A), at the second fenestration, aged 10 years and 3 months (B), and at the third fenestration and the start of the traction, aged 11 years and 2 months (C)

respectively. The axial angulations to the midline of the maxillary right and left canines were 38 degrees and 90 degrees respectively, with some rotation.

3. It was also estimated to what extent the cusp tip of the canines overlapped the adjacent lateral incisor

roots (Fig. 2B). According to the sector classification method⁹⁾, the cusp tips of the bilateral affected canines were not overlapped with the roots of the adjacent lateral incisor on the orthopantomogram and hence estimated as belonging to Sector 1.

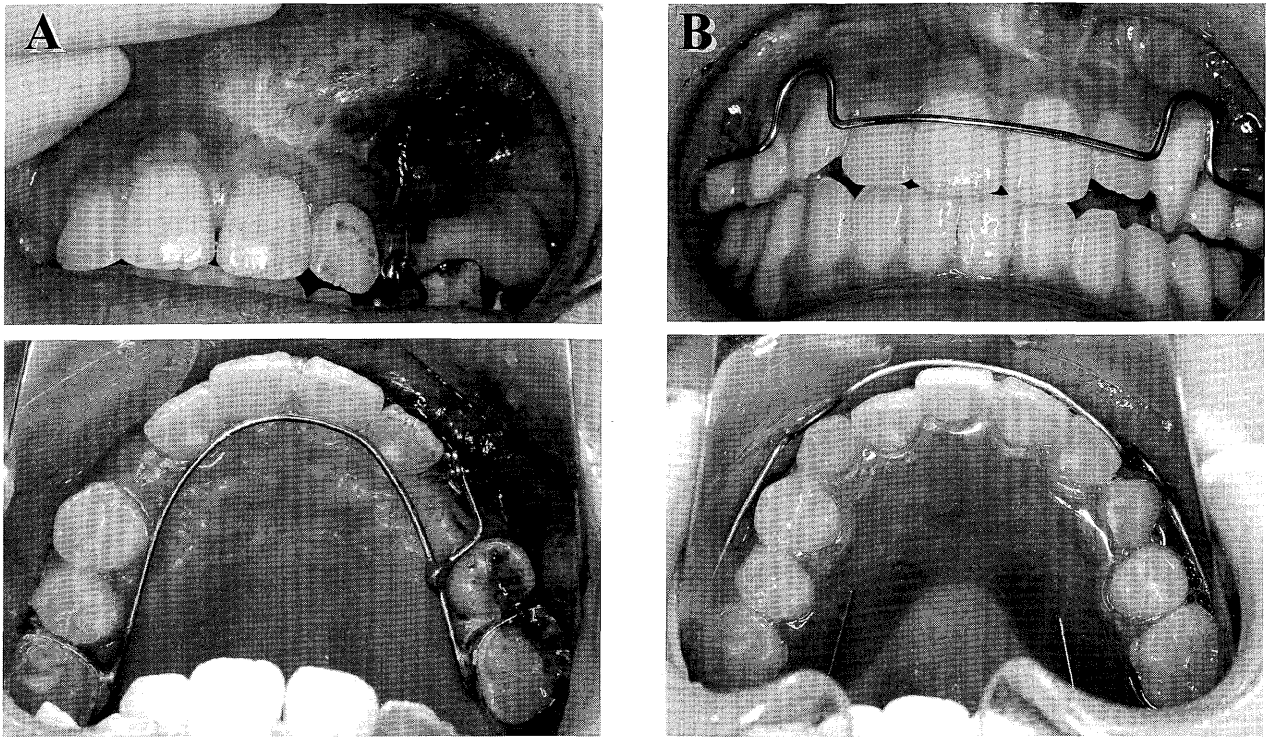


Fig. 4 Intra-oral views at the third fenestration with traction, aged 11 years 2 months (A) and at the start of retention, aged 12 years 0 months (B)

Since the space deficiency for eruption of the un-erupted canine was calculated by the space analysis, the maxillary left first premolar was decided to be extracted, instead of removal of the impacted canine which would guide the lateral jaw movement after eruption. If the patient hoped to receive an orthodontic treatment after eruption of the affected canine, it was also planned that she was referred to the orthodontic clinic. Furthermore, in case the left impacted canine exhibited no more movement toward eruption after extraction of the first premolar, it was decided that re-plantation of the canine should be performed. After the informed consent of the above treatment plan could be obtained by the patient, the treatment of bilateral ectopic canines was started.

The treatment sequence

In order to improve the aberrant eruption path of affected canines and to facilitate the eruption of the maxillary first premolars, bilateral primary canines and primary first molars were extracted. After 7 months, the fenestration of both affected canines was performed because their noticeable eruption tendency was not recognized on the orthopanto-

mogram (Fig. 3A). Fifteen months after the first fenestration, the maxillary right permanent canine showed movement toward eruption (Fig. 3B). The fenestration of the left ectopic canine was performed again at 10 years 3 months of age as there had been no change in its position and angulation.

At 10 years and 9 months of age, the maxillary left first premolar was extracted in order to dissolve the space deficiency for eruption of the un-erupted canine. On the orthopantomogram 11 months after the second fenestration, although the axial angulation to midline of maxillary left canine had improved to 45 degrees, its vertical position to the occlusal line remained high (Fig. 3C). The third fenestration of the maxillary left permanent canine was, therefore, performed and traction toward eruption was started with the appliance (Fig. 4A). Two months after initiation of the traction, the crown tip of the maxillary canines appeared in the oral cavity. Since the maxillary left canine showed some rotation, the orthodontic correction was also performed with traction and the removable retainer was used to date for 10 months to date (Fig. 4B). In contrast, the maxillary right permanent canine spontaneously erupted and aligned within the arch. The patient

had no request for any more long-term orthodontic treatment.

Discussion

The bilateral maxillary canines, in the present case, showed severe and critical ectopic conditions. Although the maxillary right canine germ was situated at a very high position (27 mm), its axial direction (38 degrees) was relatively slight compared to the opposite canine and its crown top was located in Sector 1. The treatment course was first extraction of the predecessor, and then fenestration after 6 months. Ericson *et al.*⁹⁾ have shown in a longitudinal study that early extraction of a primary canine can change the eruption path of the ectopic canine. They reported that 91% of affected canines located in Sector 1 could undergo spontaneous correction within 1 year of extraction of their predecessor. Their findings may explain why the right canine in the present case improved in relation to its initial severe malposition. It is additionally considered that the fenestration at 7 months after extraction of the primary canine would enhance the movement for improvement of the affected canine, and that the movement toward eruption of the adjacent first premolar could make a space below the root area to dissolve the malpositioning of the canine.

The maxillary left canine germ in the present case was also located at a very high position (33 mm) and was impacted horizontally in a mesio-distal direction (axial angulation: 90 degrees). It has been reported that excessive axial angulation of the ectopically erupting canines on the orthopantomogram is the most prominent feature in cases of removal where the mean angulation is beyond 50 degrees⁷⁾. However, in the present case, the affected canines were successfully guided to erupt. The principal reason may have been that the crown top of the ectopic canine belonged to Sector 1 before extraction of the predecessor. It is also speculated that early intervention, such as extraction of the predecessor and three fenestrations, begun at a fairly young age (8 years and 5 months old) would partially stimulate the spontaneous correction of the ectopic canines. Even in severe ectopic cases, therefore, it is considered that traction may be postponed until no effect of fenestration can be detected in the cases of early discovery and intervention when the crown top is situated in Sector 1.

The most frequent cause of ectopically erupting canines is malpositioning or an abnormal eruptive direction of the canine germ, with these factors accounting for 75% of all causes⁵⁾. Although the causes of the definitive factors of malpositioning or aberrant direction of the canine germ have not yet been confirmed, our findings may imply that hereditary factors may be involved in their occurrence. It has been reported that the appearance rate in females and the familial incidence of the ectopic eruption are high in the maxillary canine, and that other dental anomalies, such as dental malformation and eruption disturbance are associated with the ectopic eruption of the canine¹⁰⁾. In the present case, the female patient had an eruption disturbance of the maxillary right first molar, and the patient's mother had also an impacted tooth. These findings may support the above hypothesis of the genetic origins of occur the ectopic eruption of maxillary canines.

References

- 1) Noda, T., Takagi, M., Hayashi-Sakai, S. and Taguchi, Y.: Eruption disturbances in Japanese children and adolescents. *Ped Dent J* **16**: 50–56, 2006.
- 2) Dachi, S.F. and Howell, F.V.: A survey of 3,874 routine full-mouth radiographs: II. A study of impacted teeth. *Oral Surg Oral Pathol Oral Radiol Endod* **14**: 1165–1169, 1961.
- 3) Thilander, B. and Jakobsson, S.O.: Local factors in impaction of maxillary canines. *Acta Odontol Scand* **26**: 145–168, 1968.
- 4) Grover, P. and Lorton, L.: The incidence of unerupted permanent teeth and related clinical cases. *Oral Surg Oral Pathol Oral Radiol Endod* **59**: 420–425, 1985.
- 5) Taguchi, Y., Kurol, J., Kobayashi, H. and Noda, T.: Eruption disturbances of maxillary permanent canines in Japanese children. *Ped Dent J* **11**: 11–17, 2001.
- 6) Kurol, J., Ericson, S. and Andreasen, J.O.: Textbook and Color Atlas of Tooth Impactions. Munksgaard, Copenhagen, 1995, pp.125–165.
- 7) Taguchi, Y., Kobayashi, H. and Noda, T.: A diagnostic proposal to support early treatment of ectopically erupting maxillary canines. *Ped Dent J* **15**: 52–57, 2005.
- 8) Taguchi, Y., Hayashi-Sakai, S. and Tsuda, T.: Severe cases of ectopically erupting maxillary canine with excessive mesial angulation. *Ped Dent J* **18**: 34–42, 2008.
- 9) Ericson, S. and Kurol, J.: Early treatment of palatally erupting maxillary canines by extraction of the primary canines. *Europ J Orthod* **10**: 283–295, 1988.
- 10) Peck, S., Peck, L. and Kataja, M.: The palatally displaced canine as a dental anomaly of genetic origin. *Angle Orthod* **64**: 249–256, 1994.