

Case Report

Regional odontodysplasia: Long-term observation of a case on the mandibular left side

Futabako Iizawa, Natsuko Kinjoh and Yo Taguchi

Division of Pediatric Dentistry, Department of Oral Health Science, Course for Oral Life Science, Niigata University Graduate School of Medical and Dental Sciences
2-5274 Gakkocho-dori, Chuo-ku, Niigata 951-8514, JAPAN

Abstract Regional odontodysplasia is an unusual non-hereditary developmental anomaly of tooth structures in both primary and permanent dentitions. The appropriate treatment differs for each individual's clinical findings. The purpose of this study was to describe the clinical findings and the long-term progress as to the treatment and the management of a male patient who was diagnosed with regional odontodysplasia on the left side of the mandible. The mandibular left primary molars had shown a remarkable "ghost-like" appearance on x-ray, but they had already been extracted by an oral surgeon because of osteomyelitis due to pulpal infection, when the patient was referred to our pediatric dental clinic at 5 years of age. According to x-ray findings, the five permanent teeth (32, 33, 34, 35, 36) on the mandibular left side were delayed in formation. During the 15 years from age 5 to age 20, the patient was treated and managed in our clinic and the prosthodontic clinic of our hospital. Because the patient lost his mandibular left primary teeth early but presented delayed eruption of succedaneous permanent teeth, the patient used a temporary removable space maintainer for a long time. Although the affected first molar was extracted, the second premolar erupted and the other three unerupted teeth were not removed. The edentulous region was rehabilitated with a removable partial acrylic prosthesis when the patient was 19 years and 4 months. It was found that a multidisciplinary approach was essential for the long-term follow-up of typical regional odontodysplasia.

Key words

Ghost teeth,
Hypoplasia,
Permanent teeth,
Primary teeth,
Regional odontodysplasia

Introduction

Regional odontodysplasia is a rare and non-hereditary developmental anomaly of dental tissue derived from both the ectodermal and mesodermal layers in a group of contiguous teeth in primary and permanent dentitions¹.

McCall and Wald² first described this condition as "arrested tooth development" in 1947, and Zegarelli *et al.*³ suggested the term "odontodysplasia" in 1963. There have been many different terms used to describe this condition: regional odontodysplasia, ghost teeth, odontogenesis imperfecta, unilateral

dental malformation, amelogenesis imperfecta non-hereditary segmentalis and familial amelodentinal dysplasia⁴. Regional odontodysplasia usually affects groups of primary and permanent contiguous teeth of the same quadrant in one dental arch. The teeth in the maxilla are involved twice as often as those in the mandible⁵, and the lesions appear to be more common in the anterior segment⁶. This condition occurs in females more often than in males (1.4:1), but there are no racial or familial patterns⁵.

Clinically, regional odontodysplasia commonly accompanies delayed, failed or partial tooth eruption with or without gingival abscess. The enamel and dentin of affected teeth are hypoplastic and hypocalcified. The surface of the affected yellowish or brownish discolored teeth typically exhibit irregular

Received on September 30, 2009

Accepted on January 29, 2010

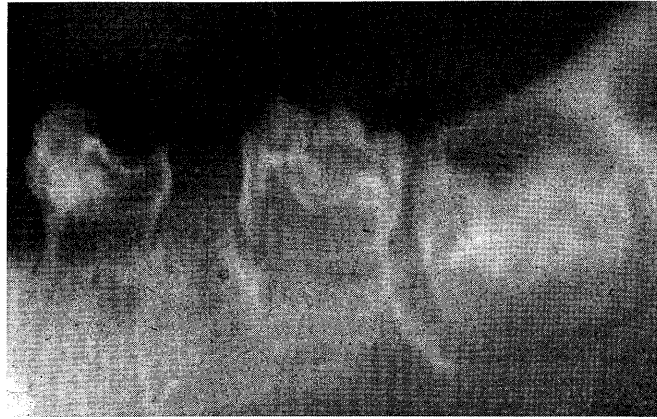


Fig. 1 Periapical x-ray at the age of 2 years and 8 months demonstrating the characteristic "ghost-like" appearance of the mandibular left primary molars and first molar.

pits and grooves. The affected teeth are usually small in size and can be easily fractured because their structure is defective⁷). Therefore, abscess formation in the gingiva often occurs without dental caries⁵⁻⁷).

On x-rays, the affected teeth show abnormal morphology and a hypoplastic crown. There is a lack of contrast between the enamel and the dentin, both of which reduce the radiodensity. Because the enamel and dentin of the affected teeth are excessively thin and defective, their x-ray appearance, with only a faint outline of hard tissue, has earned them the name of "ghost teeth". The pulp chambers and root canals appear to be correspondingly large, and usually present an area of relatively radiodense tissue as pulp stone or denticles⁹). The roots of the affected teeth are short and incompletely formed, and apical closure is delayed. Unerupted teeth may be surrounded by a pericoronal radiolucency representing an enlarged follicle. Histological findings^{5,6,8,10-12}) on extracted teeth have been reported in detail. However, there have been very few reports^{13,14}) on the long-term changes and final treatment of regional odontodysplasia.

The aim of this study was to describe the clinical findings and the long-term progress of a patient who was diagnosed with and treated for regional odontodysplasia on the left side of the mandible, beginning at a young age. Informed consent to publish this article was obtained from the child and his parents.

Case Report

A 2-year-9-month-old Japanese boy was brought

to a private dental clinic seeking treatment for pain of the mandibular left primary molar region. The periapical x-ray image revealed the appearance of "ghost" molars in the region (Fig. 1). The mandibular left first primary molar was extracted because it seemed to be the tooth most likely to be causing the pain. At the age of 3 years and 2 months, the patient's pain recurred. The mandibular left primary lateral incisor was extracted, but the pain did not disappear (Fig. 2). The patient was referred to the Oral and Maxillofacial Surgery Clinic at Niigata University Medical and Dental Hospital in Japan, where he was diagnosed with osteomyelitis of the mandibular left side. Because the pulpal infection of the mandibular left primary canine and second primary molar was diagnosed as the cause of osteomyelitis, these teeth were extracted during hospitalization. At the age of 5 years, the patient was referred to our Pediatric Dental Clinic for diagnosis and treatment of this unusual condition affecting the teeth on the left side of the mandible.

Patient and familial history

The patient's medical history revealed that he had suffered from Kawasaki's disease at the age of 4 years. No noteworthy abnormality was recognized during pregnancy and delivery, and there was no history of local trauma or radiation therapy. The family history was not contributory.

Clinical course and treatment

The intraoral examination showed that the patient had a full complement of maxillary primary teeth and mandibular right primary teeth without dental

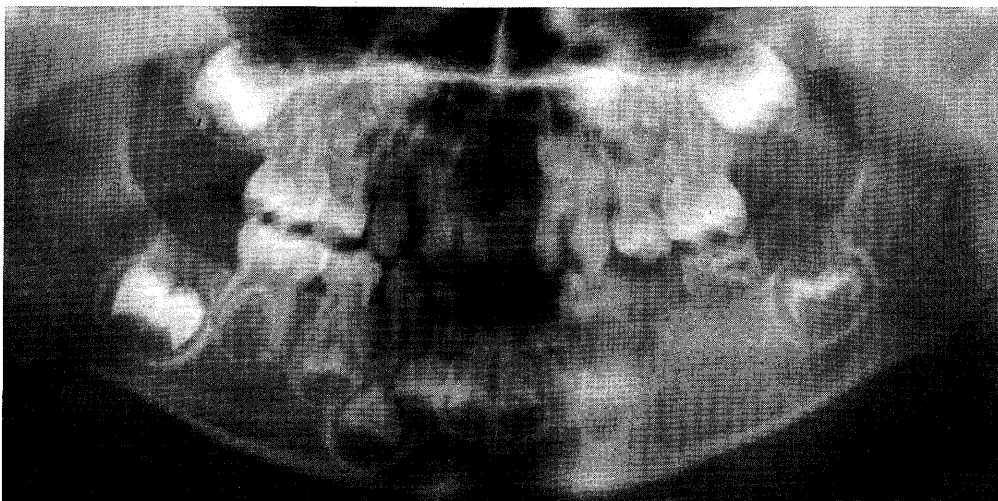


Fig. 2 Panoramic x-ray at the age of 3 years and 2 months showing the ghost-like appearance of the teeth in the mandibular left quadrant. The mandibular left second primary molar and first molar had the typical appearance of odontodysplasia, whereas all teeth in other quadrants were normal. The formation of the mandibular left permanent canine, premolars and first molar were delayed in comparison with teeth on the mandibular right side.

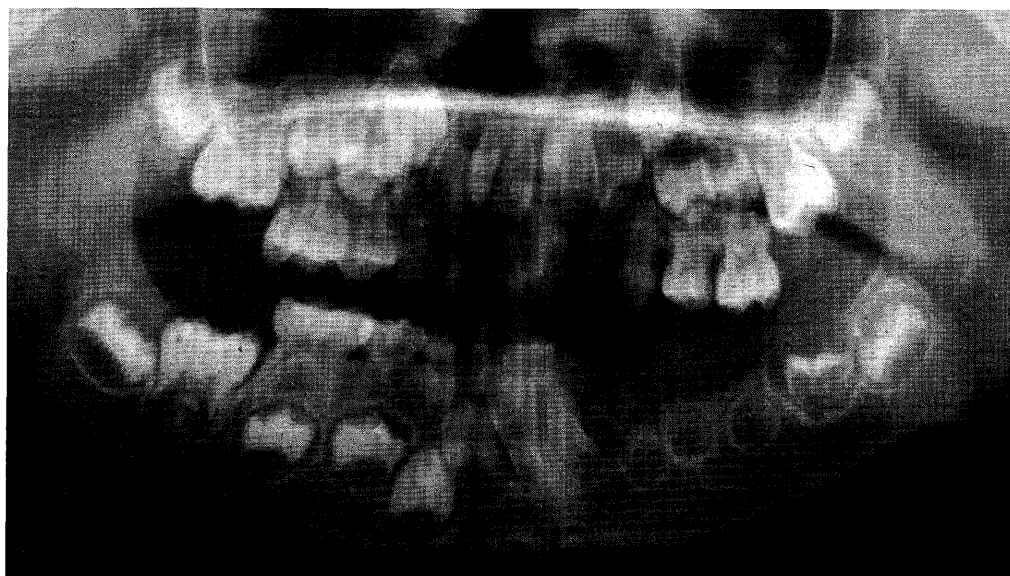


Fig. 3 Panoramic x-ray at the age of 5 years and 10 months showing calcification of the affected mandibular left permanent teeth. The tooth germs of mandibular left premolars were small and hypoplastic, with an indistinct crown. Although the crown formation of the mandibular left first molar was almost finished, the tooth was surrounded by a pericoronal radiolucency representing an enlarged follicle, and the demarcation between enamel and dentine was poorly defined.

caries. The successors of the extracted primary teeth in the mandibular left side had not erupted. X-rays revealed delayed formation and mineralization in the mandibular left permanent lateral incisor, canine, first premolar, second premolar and first molar (Fig. 3). The morphology of these teeth was bizarre,

small and hypoplastic.

According to the clinical and x-ray findings, a diagnosis of regional odontodysplasia was made. The affected edentulous region was temporarily rehabilitated with a removable space maintainer to provide chewing function. The patient was placed on

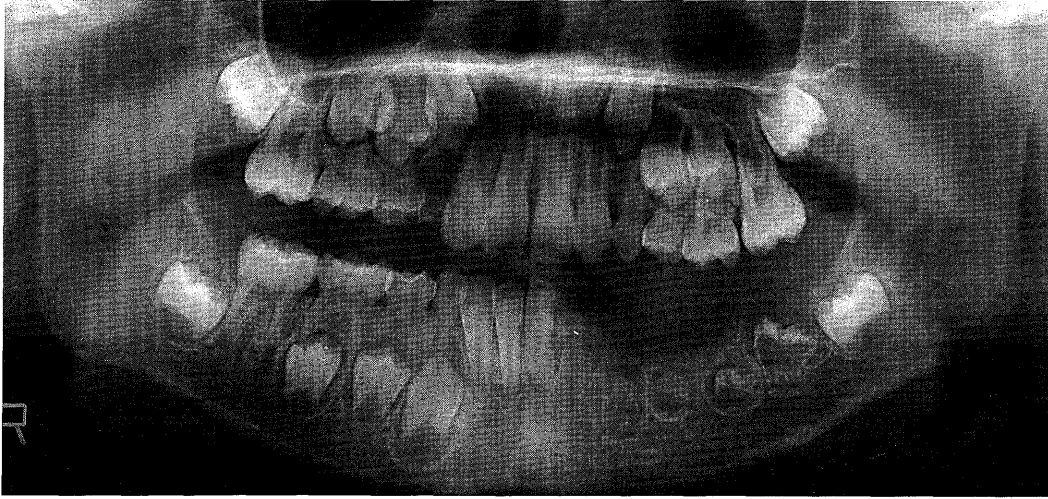


Fig. 4 Panoramic x-ray at the age of 8 years and 6 months. A ghost-like appearance is evident in the lower left permanent lateral incisor, canine, premolars and first molar. The root formation of the mandibular left first permanent molar has started.

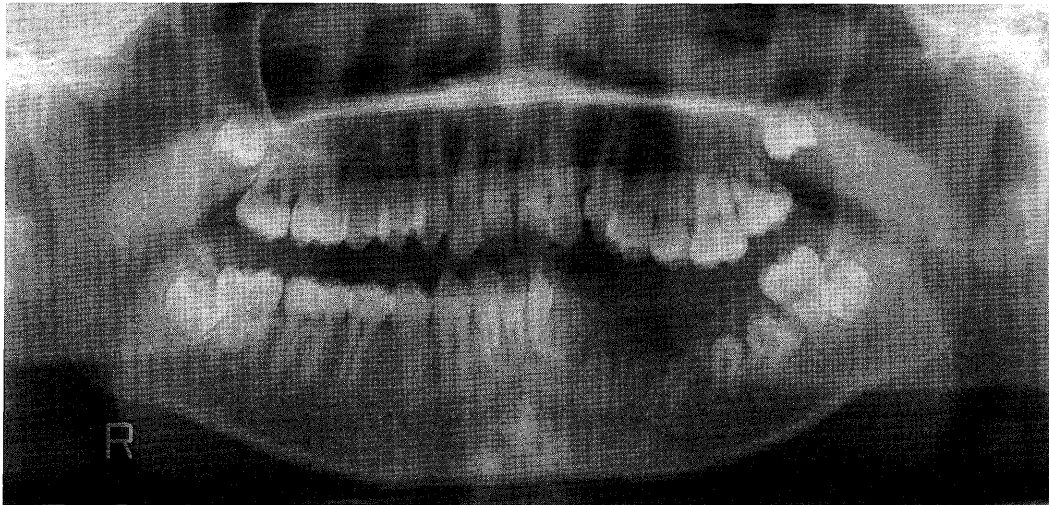

Fig. 5 Panoramic x-ray at the age of 13 years and 1 month showing unerupted hypoplastic mandibular left permanent lateral incisor, canine, premolars and first molar. The tooth axis of the impacted mandibular left first molar inclines distally, and the enlarged follicle is shown to contact the mesial root of the second molar. The tooth axis of the mandibular left first premolar also inclines distally.

periodic follow-up so that the progress of permanent tooth formation of the mandibular left quadrant could be observed and the removable space maintainer could be checked. The temporary space maintainer was reformed regularly until a permanent prosthesis was made.

At the age of 8 years and 6 months, a panoramic x-ray showed marked hypoplasia of the mandibular left permanent lateral incisor, canine, first premolar, second premolar, and first molar (Fig. 4). These teeth

showed the characteristic ghost-like appearance of regional odontodysplasia.

The patient complained of pain in the mandibular left molar region at the age of 13 years and 1 month. The cause of the pain was an infection of the unerupted mandibular left permanent first molar from mesial gingival pockets of the second molar. X-rays revealed a radiolucent area around the unerupted hypoplastic permanent first molar (Fig. 5). The affected molar had a malformed crown

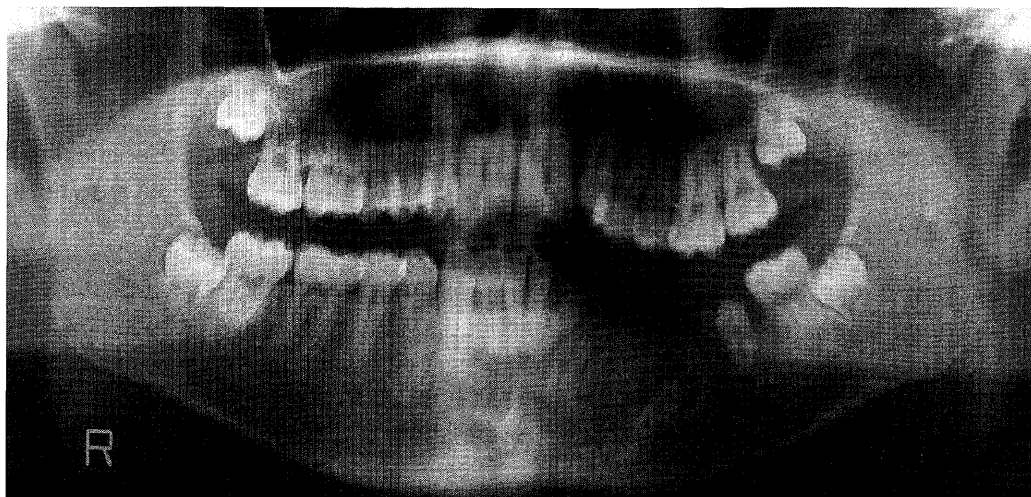


Fig. 6 Panoramic x-ray at the age of 15 years 6 months showing impaction of the lower left permanent lateral incisor, canine and first premolar. The dental follicles surrounding the unerupted lateral incisor, canine and first premolar were somewhat enlarged. The erupted mandibular left second premolar showed a malformed and hypocalcified crown and short root.

and root with hypoplastic enamel and dentin, and a distally inclined axis, while the root formation of the mandibular left lateral incisor, canine, first premolar, and second premolar were progressing. The state of formation in the mandibular left second molar was normal. We determined that it would be difficult to keep the unerupted first molar and surgically removed it. A new temporary removable space maintainer was constructed after the removal.

At the age of 15 years 6 months, the patient's mandibular left second premolar erupted, and its root formation was almost completed (Fig. 6), but the tooth showed a malformed, small and undercalcified crown with a short root. The mandibular left lateral incisor, canine, and first premolar did not erupt and their dental follicles appeared to be somewhat enlarged. The impacted mandibular left permanent lateral incisor, canine and first premolars were retained for preservation of the alveolar ridge. We continued with periodic examinations, but there was no sign of infection or abnormal clinical findings of the impacted teeth and the erupted second premolar. We reformed the removable space maintainer when necessary and the patient continued to use it.

The edentulous region was rehabilitated with a removable partial acrylic prosthesis in the Prosthodontic Clinic of our hospital when the patient was 19 years and 4 months. After the patient reached 20 years of age and became too busy to visit our hospital periodically, he was referred to a specialist in

pediatric dentistry closer to his home. We considered that it was essential for the patient to continue the clinical and x-ray follow-up with a specialist because the retained teeth might cause some complications. It was agreed that the specialist would contact us in the case of difficult problems occurring with the impacted teeth, and that we would consult the dentists in our hospital including the dentist of the Oral and Maxillofacial Surgery Clinic.

Discussion

The etiology of regional odontodysplasia remains uncertain. It has been suggested that this condition may derive from a disorderly proliferation of the dental epithelium at an early stage of development, during the formation of dental structures. Many etiologic factors have been suggested, such as local circulatory disorders¹⁵⁻¹⁸, viral infection of the tooth germ during development^{16,17,19,20}, pharmacotherapy during pregnancy⁶, local trauma^{3,15,21}, metabolic disturbances, local somatic mutation affecting the dental lamina in the area¹¹, and failure of the migration of the neural crest cells²². Although many theories have been advanced by various authors, it was not possible to determine the precise etiological factors in our case. Regional odontodysplasia commonly presents as either failed, delayed or partial eruption with or without abscess formation not caused by dental caries²³⁻²⁵. Since the present case showed

the characteristic clinical and x-ray photographic features of regional odontodysplasia and had no dental caries, we could diagnose it at early age.

The care and treatment of children with regional odontodysplasia require a multidisciplinary approach. The treatment of regional odontodysplasia remains somewhat controversial²⁶⁻³⁰, and no consensus has yet been reached on what the standard treatment should be. Some clinicians advocate the removal of the affected teeth as soon as possible, while others recommend preserving the affected teeth for as long as possible^{6,25}. Treatment should be based on a consideration of the age of the patient, his or her medical history, previous dental experience, the number of affected teeth, and the attitude and wishes of the child and parents alike. In our opinion, for young children, the infected primary teeth should be extracted, but as many of the affected teeth as possible should be preserved to maintain normal jaw development^{6,27}. In the present case, the patient was managed conservatively except in the case of the infected first molar and primary teeth.

The teeth attacked by regional odontodysplasia are often impacted, but there have been few reports^{13,14} of the long-term changes and final treatment of impacted teeth. Impacted teeth may lead to infection of the tooth germ, some sequelae of retained epithelial tissue such as formation of follicular cysts or odontogenic tumors, and/or pain induced by nervous pressure on the mandibular canal³⁰⁻³³. The patients, therefore, need dental management for a long period from childhood to adulthood. Early detection and treatment are quite necessary to avoid future therapeutic complexity. At the age of 13 years, in the present case, the mandibular left first molar germ was extracted because of infection and an abnormal tooth axis. It was suggested that early detection of local discomfort by periodic check-ups could prevent systemic disorders such as osteomyelitis.

The temporary removable prostheses should be reconstructed repeatedly over the unerupted teeth during the period of skeletal growth to preserve the alveolar ridge form⁵, and to avoid drifting and extrusive movement of the opposing teeth into the edentulous areas. It has been proposed that orthodontic traction is effective even for regional odontodysplasia when the root development of the impacted teeth progresses up to a reasonable degree^{5,30,33}. For the present patient, we did not perform orthodontic traction because the roots of the

unerupted mandibular left lateral incisor and canine were short and the first premolar was impacted in the deep part of the mandible. The final rehabilitating treatment was accomplished without removing any of the impacted teeth when the patient was 19 years old. To date, the impacted teeth have not caused any symptoms. We may choose, in the future, other types of prosthetic treatment such as bridgeworks and implants, depending on the patient's demand^{5,27,29}.

The goals of treatment for regional odontodysplasia include aiding mastication and the eruption of teeth, increasing function, improving aesthetics, minimizing psychological effects, protecting erupted affected teeth and allowing for future prosthetic treatment. For teeth affected by regional odontodysplasia, the chosen treatment method for each case should be performed on the proper time according to needs during long-term observation. In addition, it is important to provide continuous dental supervision and case management.

References

- 1) Thoma, K.H., Gorlin, R.J. and Goldman, H.M.: Thoma's Oral Pathology. 6th ed. Mosby, St. Louis, 1970, pp. 146-147.
- 2) McCall, J.O. and Wald, S.S.: Clinical Dental Roentgenology. 3rd ed. W.B. Saunders, Philadelphia, 1947, p. 169.
- 3) Zegarelli, E., Kutscher, A. and Applebaum, E.: Odontodysplasia. *Oral Surg Oral Med Oral Pathol* **16**: 187-193, 1963.
- 4) Pandis, N., Polido, C. and Bell, W.H.: Regional odontodysplasia. A case associated with asymmetric maxillary and mandibular development. *Oral Surg Oral Med Oral Pathol* **72**: 492-496, 1991.
- 5) Crawford, P.J. and Aldred, M.J.: Regional odontodysplasia: a bibliography. *J Oral Pathol Med* **18**: 251-263, 1989.
- 6) Lustmann, J., Klein, H. and Ulumanskey, M.: Odontodysplasia: Report of two cases and review of the literature. *J Oral Surg* **39**: 781-793, 1975.
- 7) Ferguson, F.S., Creath, C.J. and Buono, B.: Infraorbital infection related to odontodysplasia: case report. *Pediatr Dent* **12**: 397-400, 1990.
- 8) Vaikuntam, J., Tatum, N.B. and McGuff, H.S.: Regional odontodysplasia: review of the literature and report of a case. *J Clin Pediatr Dent* **21**: 35-40, 1996.
- 9) Kinirons, M.J., O'Brien, F.V. and Gregg, T.A.: Regional odontodysplasia: An evaluation of three cases based on clinical, microradiographic, and histopathological findings. *Br Dent J* **165**: 136-139, 1988.
- 10) Crouson, F., Bdeoui, F., Danan, M., Degrange, M. and Gogly, B.: Regional odontodysplasia: Expression of matrix metalloproteinases and their natural inhibitors. *Oral Surg Oral Med Oral Pathol Radiol Endod* **95**:

- 60–66, 2003.
- 11) Rushton, M.A.: Odontodysplasia: Ghost teeth. *Br Dent J* **119**: 109–113, 1965.
 - 12) Abrams, A.M. and Geoper, J.: Odontodysplasia: report of three cases. *ASDC J Dent Child* **33**: 353–362, 1966.
 - 13) Hosoya, Y.: A case report of regional odontodysplasia — Eleven year clinical observation —. *Jpn J Ped Dent* **33**: 624–632, 1995. (in Japanese)
 - 14) Masuda, N., Kitamura, K., Ootuki, K., Sobue, S., Furukawa, S. and Fuchihata, H.: Regional odontodysplasia: report of a case. *J Osaka Univ Dent Soc* **28**: 287–294, 1983. (in Japanese)
 - 15) Alexander, W.N., Lilly, G.E. and Irby, W.B.: Odontodysplasia. *Oral Surg* **22**: 814–820, 1966.
 - 16) Gibbard, P.D., Lee, K.W. and Winter, G.B.: Odontodysplasia. *Br Dent J* **135**: 525–532, 1973.
 - 17) Herold, R.C.B., Lally, E.T. and Gold, L.: Abnormal tooth tissue in human odontodysplasia. *Oral Surg* **42**: 357–365, 1976.
 - 18) Walton, J.L., Witkop, C.J. and Walker, P.O.: Odontodysplasia: report of three cases with vascular nevi overlying the adjacent skin of the face. *Oral Surg* **46**: 676–684, 1978.
 - 19) Rushton, M.A.: A new form of dentinal dysplasia: shell teeth. *Oral Surg* **7**: 543–549, 1954.
 - 20) Reade, P.C., Radden, B.G. and Barke, J.J.: Regional odontodysplasia. A review and a report of two cases. *Aust Dent J* **19**: 152–161, 1974.
 - 21) Bergman, G., Lysell, L. and Pindborg, J.J.: Unilateral dental malformation: report of two cases. *Oral Surg Oral Med Oral Pathol* **16**: 48–60, 1963.
 - 22) Slootweg, P.J. and Meuwissen, P.R.M.: Regional odontodysplasia in epidermal nevus syndrome. *J Oral Pathol* **14**: 256–262, 1985.
 - 23) Steiman, H.R., Cullen, C.L. and Geist, J.R.: Bilateral mandibular regional odontodysplasia with vascular nevus. *Pediatr Dent* **13**: 303–306, 1991.
 - 24) Hamdan, M.A., Sawair, F.A., Rajab, L.D., Hamdan, A.M. and Al-Omari, I.K.: Regional odontodysplasia: A review of the literature and report of a case. *Int J Paediatr Dent* **14**: 363–370, 2004.
 - 25) Lin, H.M., Irie, K., Ozawa, H. and Noda, T.: Histological study of a case of odontodysplasia. *Ped Dent J* **5**: 91–97, 1995.
 - 26) Gündüz, K., Zengin, Z., Celenk, P., Ozden, B., Kurt, M. and Gunhan, O.: Regional odontodysplasia of the deciduous and permanent teeth associated with eruption disorders: A case report. *Oral Med Oral Patol Oral Cir Bucal* **13**: 563–566, 2008.
 - 27) Kahn, M.A. and Hinson, R.L.: Regional Odontodysplasia: Case report with etiologic and treatment considerations. *Oral Surg Oral Med Oral Pathol* **72**: 462–467, 1991.
 - 28) Sadeghi, E.M. and Ashrafi, M.: Regional odontodysplasia: Clinical, pathologic, and therapeutic considerations. *J Am Dent Assoc* **102**: 336–339, 1981.
 - 29) Cahuana, A., González, Y. and Palma, C.: Clinical management of regional odontodysplasia. *Pediatr Dent* **27**: 34–39, 2005.
 - 30) Hanks, P.A. and Williams, B.: Odontodysplasia: report of two cases. *Pediatr Dent* **20**: 199–203, 1998.
 - 31) O'Neil, D.W., Koch, M.G. and Lowe, J.W.: Regional odontodysplasia: report of case. *J Dent Child* **57**: 459–461, 1990.
 - 32) Andreasen, J.O., Petersen, J.K. and Laskin, D.M.: Textbook and Color Atlas of Tooth Impactions: Diagnosis, Treatment and Prevention. 1st ed. Munksgaard, Copenhagen, 1997, p. 145.
 - 33) Melamed, Y., Harnik, J., Becker, A. and Shapira, J.: Conservative multidisciplinary treatment approach in an unusual odontodysplasia. *J Dent Child* **61**: 119–124, 1994.