Leukemia Research, Vol. 26(7), 693-695, 2002

Case report

Cutaneous lymphoblastic lymphoma of putative plasmacytoid dendritic cell-precursor origin; 2 cases.

Akihito Momoi[1], Ken Toba[1], Kazuhiro Kawai[2], Junjiro Tsuchiyama[1], Noriatsu Suzuki[1], Toshio Yano[1], Yumiko Uesugi[1], Masuhiro Takahashi[3], Yoshifusa Aizawa[1].

[1]First Department of Internal Medicine and [2]Department of Dermatology, School of medicine, and [3]School of Health Sciences, Faculty of Medicine, Niigata University, Japan

Corresponding author: Ken Toba, M.D. First Department of Internal Medicine, Niigata University Medical Hospital, Asahimachi-dori 1, Niigata City, 951-8520, Japan.
Tel.: +81-25-227-2185, Fax: +81-25-227-0774, e-mail: tobaken@med.niigata-u.ac.jp

Keywords: lymphoblastic lymphoma; plasmacytoid dendritic cell; cutaneous lymphoma; gene rearrangement; chromosome translocation; leukemic transformation.

Abstract Although the neoplasm of relatively mature type pDC was recently reported, that of pDC-precursor has not yet been defined. We experienced 2 elderly male Japanese patients with reddish skin tumors. The histology of the tumors in both patients showed TdT-positive LBL. The pathological cells did not express T-, B- or NK-markers, and no rearranged bands were shown for Ig-JH, TCR-Cβ, Jγ, Jδ1, and c-*myc*. In addition, no EBV-derived DNA was detected in either case. The cells were CD45, CD43, CD74, CD10 and HLA-DR positive in both cases, and one of the cases showed CD4, CD36, CD54, CD58 and CD86-positive plasmacytoid lymphoblasts, which appeared to be compatible with intermediate cells between human bone marrow lymphoid precursors and mature lymphoid dendritic cells. The cutaneous LBL in the 2 cases may, therefore, have been of pDC-precursor origin.

List of abbreviations: DC, dendritic cells; pDC, plasmacytoid dendritic cells; LBL, lymphoblastic lymphoma; TdT, terminal deoxinucleotidyl transferase; Ig, immunoglobulin; TCR, T cell receptor; EBV, Epstein-Barr virus; sIL-2R, soluble interleukin-2 receptor.

Introduction

The characteristics and functions of DC have been intensively studied in the last decade [1, 2]. The cells support the specific antigen-recognition by T cells or B cells, and are believed to play a key role in the initiation and maintenance of immunological reactions. In the last few years, searching for the precursors of DCs and investigating its ontogeny have been key topics in hematology. Although 7 cases with aggressive, extranodal leukemic lymphoma as a malignant counterpart of relatively mature type pDC-origin were recently reported [3], neoplasms of pDC precursor cells have not yet been defined. "Plasmacytoid cells" showing a unique morphology and phenotype were identified as the precursor of lymphoid DC [4, 5]. Therefore, it was suggested that DC precursor neoplasms must show the blast morphology and a partially identical phenotype to DC precursors when we consider LBL of T or B cell origin. Thus, it is suggested that the pathological entity of precursor DC-LBL will contain some "null cells" or "unclassified" lymphoma of REAL or WHO classification, and will supplement the "missing pieces" in the classification. Furthermore, characterization of transformed DC in patients will assist in understanding the sequential changes of the organ affinity and phenotype according to the differentiation pathway of the lymphoid DC hematopoiesis.

Case 1

A 69-year-old Japanese male was admitted to our hospital with a reddish skin tumor on his back in January, 2000 (Fig. 1 and Table 1). The tumor size was 8 x 5.5 cm, and no other abnormal lymph node swelling or tumors were noted on computed tomography. Informed consent was obtained from the patient for the following analyses to be performed. Bone marrow aspirate showed no abnormal cells. The

histology of the tumor showed TdT-positive LBL (Fig. 1), and the small to medium-sized lymphoblasts with scarce cytoplasm and clearly visible nucleoli were CD45, CD43, CD74 and bcl2-positive, and CD1a, CD30 (Ki-1), CD45RO (UCHL1), CD56 (Leu19), CD57 (Leu7), S100, perforin and fascin-negative (Table 2). A laboratory examination showed normal blood counts, no liver or renal dysfunction, no coagulation abnormality, and normal serum level of sIL-2R. The patient was treated for a diagnosis of LBL, clinical stage IAE, using 50Gy of local radiotherapy, and subsequently the skin tumor disappeared.

In March, 2000, a bone marrow aspirate was performed for evaluating the disease after radiotherapy, and it showed 35% of infiltrating abnormal lymphoblasts with immature plasmacytoid cell feature (Fig. 1). The sample was analyzed using flow cytometry, and the pathological cells were T cell markers (CD1a, CD2, CD3, CD5, CD7, CD8, TCRα/β, TCRγ/δ)-negative, B cell markers (CD19, CD20, CD21, CD22, CD23, CD24)-negative, NK cell markers (CD16, CD56, CD57, NKp46, NKp44)-negative, hematopoietic progenitor markers (CD34, CD117, AC133)-negative, and myeloid/other markers (CD11b, CD13, CD14, CD15, CD25, CD27, CD33, CD38, CD40, CD41, CD70, CD122, CD154, GPA, FMC7, 97A6)-negative (Table 2). Approximately 76 to 99% of the gated pathological cells were CD4, CD10, CD36, CD45, CD54 and HLA-DR-positive (Fig. 2). Cytoplasmic expression of myeloperoxidase, CD3ε and CD22 were negative for the cells. Chromosome analysis of the bone marrow specimen showed complex abnormal karyotype: 46, XY, add(5)(q11), add(5)(q31), t(6;8)(p21;q24), del(13)(q12q14), add(15)(q13) in 9 of 20 metaphases studied according to ISCN (Fig. 3). Southern blot analysis of the sample showed no rearranged bands for Ig-JH, TCR-Cβ, Jγ, Jδ1, and c-*myc* (Fig. 4). No EBV-derived DNA was detected. The patient was treated using intensive chemotherapy of THP-COP regimen (pirarubicin, cyclophosphamide, vincristine and prednisolone). The bone marrow aspirate after the first course of THP-COP showed no pathological cells, and he received 5 more courses of THP-COP at 3-week intervals.

In September, 2000, the patient was diagnosed with leukemic transformation from the disease; the leukocyte count was 49.0 x 10^9 cells/l (lymphoblasts 71%), and the serum level of lactate dehydrogenase was 23,040 IU/l. Since it was suggested that the phenotype of the lymphoblasts had been very similar to lymphoid dendritic cell (DC)-precursors, so called "plasmacytoid cells", we further examined the expression of DC markers by flow cytometry (Fig. 2 and Table 2). The lymphoblasts were CD1a, CD80, CD83-negative, CD54, CD58-dim positive, and CD86-bright-positive. A weekly DVP regimen (daunomycin, vincristine and prednisolone) was started but the disease was resistant to DVP, and the patient died of septic shock in November, 2000.

Case 2

A 86-year-old Japanese male was admitted to our hospital with a reddish skin tumor on his forehead in August, 2000. The tumor size was 4 x 3 cm (Fig. 1 and Table 1), and no other abnormal lymph node swelling or tumors were noted on computed tomography. Informed consent was obtained from the patient for the following analyses to be performed. Bone marrow aspirate showed no abnormal cells. The histology of the tumor showed TdT-positive LBL (Fig. 1), and the small to medium-sized lymphoblasts were CD45, CD43 and CD74-positive, and CD1a, CD30, CD45RO, CD56, CD57, Granzyme B, Perforin and fascin-negative. A single cell suspension was obtained from the tumor by mincing using Medimachine™ (DAKO), and the sample was analyzed using flow cytometry. The pathological cells were T cell markers (CD2, CD3, CD4, CD5, CD8, TCRα/β, TCRγ/δ)-negative, B cell markers (CD19, CD20, CD23)-negative, NK cell marker (CD56)-negative, hematopoietic progenitor marker (CD34)-negative, and myeloid/other markers (CD25, CD33, CD122)-negative (Table 2). Approximately 69 to 74% of the gated pathological cells were CD10 and HLA-DR-positive, and 12% and 34% of the cells were CD11b and CD38-positive, respectively. Laboratory examination showed normal blood counts, no liver or renal dysfunction, no coagulation abnormality, and normal serum levels of sIL-2R. Chromosome analysis failed in the sample. Southern blot analysis of the sample showed no rearranged bands for Ig-JH, TCR-Cβ, Jγ, Jδ1, and c-*myc* (Fig. 4). No EBV-derived DNA was detected. Multiple reddish skin tumors appeared in his chest and back skin, and a biopsy of one of the

tumors showed the same histology. Considering his age and general conditions, the patient was treated for a diagnosis of LBL, clinical stage IIAE, with 50 to 100 mg of daily oral cyclophosphamide. The disseminated skin tumors disappeared, but the original large tumor grew after the mild chemotherapy. He was then treated with radiotherapy, and died of cerebral infarction in December, 2000.

Discussion

There are two types of DC; myeloid DC and lymphoid DC [6 – 8]. Myeloid DC includes epidermal Langerhans cells and CD14-positive DC [9, 10]. T lymphocytes, B lymphocytes, NK cells and lymphoid DC arise from CD10-positive, lineage marker-negative common lymphoid precursors [11, 12]. The common lymphoid precursors differentiate to lymphoid DC in the presence of flt3-ligand, SCF, IL-7 and IL-3 [13]. Plasmacytoid cells in the T cell zone of human lymph nodes are CD4, CD31 CD36, CD68 and CLA (cutaneous lymphocyte antigen)-positive [14], and they maturate to interdigitating cells in the presence of IL-3 and CD40-ligand. This terminal differentiated DC expresses CD1a, CD40, CD48, CD54, CD58, CD80, CD83, CD86 and HLA-DR to adhere and function for antigen presentation to T lymphocytes [15].

The phenotype of lymphoma cells of cases 1 and 2 are compared in Table 3 with the previously reported phenotypes of the pDC development pathway from common lymphoid progenitors [3, 4, 12-14, 16, 17]. The phenotype of the lymphoblasts in case 1 was approximately compatible with intermediate cells between human bone marrow lymphoid precursors and mature lymphoid DC. Moreover, the lymphoma cells expressed TdT-positive lymphoblast morphology in the absence of characters of T-, B- and NK in phenotype as well as gene rearrangement. Therefore, the cells were compatible with lymphoblasts of putative pDC-precursor origin. However, the lymphoblasts in case 2 expressed CD10 and HLA-DR, but not CD4. The expression of CD36, CD54, CD58 or CD86 was, unfortunately, not determined in the patient, because of the rapid clinical course, nevertheless, the clinical features of the 2 patients were very similar.

Acknowledgments

The authors wish to thank Drs Alessandro Moretta and Hans-Joerg Buhring for kindly providing the monoclonal antibodies NKp [18, 19] and 97A6 [20], respectively. We also wish to thank Dr Shigeo Nakamura of Aichi Cancer Center Hospital for histologically diagnosing the specimens.

References

1. Hart DNJ. Dendritic cells: unique leukocyte populations which control the primary immune response. Blood 1997; 90: 3245-87.
2. Cella M, Sallusto F, Lanzavecchia A. Origin, maturation and antigen presenting function of dendritic cells. Curr Opin Immunol 1997; 9: 10-6.
3. Chaperot L, Bendriss N, Manches O, Gressin R, Maynadie M, Trimoreau F, Orfeuvre H, Corront B, Feuillard J, Sotto JJ, Bensa JC, Briere F, Plumas J, Jacob MC. Identification of a leukemic counterpart of the plasmacytoid dendritic cells. Blood 2001; 97: 3210-7.
4. Grouard G, Rissoan M, Filgueira L, Durand I, Banchereau J, Liu Y. The enigmatic plasmacytoid T cells develop into dendritic cells with interleukin (IL)-3 and CD40-ligand. J Exp Med 1997; 185: 1101-11.
5. Siegal FP, Kadowaki N, Shodell M, Fitzgerald-Bocarsly PA, Shah K, Ho S, Antonenko S, Liu YJ. The nature of the principal type 1 interferon-producing cells in human blood. Science 1999; 284: 1835-7.
6. Borkowski TA, Letterio JJ, Farr AG, Udey MC. A role for endogenous transforming growth factor β1 in Langerhans cell biology: The skin of transforming growth factor β1 null mice is devoid of epidermal Langerhans cells. J Exp Med 1996; 184: 2417-22.
7. Reid CDL. The dendritic cell lineage in haemopoiesis. Brit J Haematol 1997; 96: 217-23.
8. Marquez C, Trigueros C, Franco JM, Ramiro AR, Carrasco YR, Lopez-Botet M, Toribio ML. Identification of a common developmental pathway for thymic natural killer cells and dendritic cells. Blood 1998; 91: 2760-71.
9. Santiago-Schwarz F. Positive and negative regulation of the myeloid dendritic cell lineage. J Leukocyte Biol 1999; 66: 209-16.
10. Guerriero A, Langmuir PB, Spain LM, Scott ED. PI.1 is required for myeloid-derived

but not lymphoid-derived dendritic cells. Blood 2000; 95: 879-85.
11. Galy A, Travis M, Cen D, Chen B. Human T, B, natural killer and dendritic cells arise from a common bone marrow progenitor cell subset. Immunity 1995; 3: 459-73.
12. Galy A, Christopherson I, Ferlazzo G, Liu G, Spits H, Georgopoulos K. Distinct signals control the hematopoiesis of lymphoid-related dendritic cells. Blood 2000; 95: 128-37.
13. Miller JS, McCullar V, Punzel M, Lemischka IR, Moore KA. Single adult human CD34+/Lin-/CD38- progenitors give rise to natural killer cells, B-lineage cells, dendritic cells, and myeloid cells. Blood 1999; 93: 96-106.
14. Strobl H, Scheinecker C, Riedl E, Csmarits B, Bello-Fernandez C, Pickl WF, Majdic O, Knapp W. Identification of $CD68^{+}lin^{-}$ peripheral blood cells with dendritic precursor characteristics. J Immunol 1998; 161: 740-8.
15. Banchereau J, Steinman RM. Dendritic cells and the control of immunity. Nature 1998; 392: 245-52.
16. Albert ML, Pearce SFA, Francisco LM, Sauter B, Roy P, Silverstein RL, Bhardwaj N. Immature dendritic cells phagocytose apoptotic cells via $\alpha_v\beta_5$ and CD36, and cross-present antigens to cytotoxic T lymphocytes. J Exp Med 1998; 188: 1359-68.
17. Schmitt C, Fohrer H, Beaudet S, Palmer P, Alpha MJ, Canque B, Gluckman JC, Dalloul AH. Identification of mature and immature human thymic dendritic cells that differentially express HLA-DR and interleukin-3 receptor in vivo. J Leukocyte Biol 2000; 68: 836-44.
18. Sivori S, Vitale M, Morelli L, Sanseverino L, Augugliaro R, Bottino C, Moretta L, Moretta A. p46, a novel natural killer cell-specific surface molecule that mediated cell activation. J Exp Med 1997; 186: 1129-36.
19. Pessino A, Sivori S, Bottino C, Malaspina A, Morelli L, Moretta L, Biassoni R, Moretta A. Molecular cloning of NKp46: a novel member of the immunoglobulin superfamily involved in triggering of natural cytotoxicity. J Exp Med 1998; 188: 953-60.
20. Buhring HJ, Simmons PJ, Pudney M, Muller R, Jarrossay D, van Agthoven A, Willheim M, Brugger W, Valent P, Kanz L. The monoclonal antibody 97A6 defines a novel surface antigen expressed on human basophils and their multipotent and unipotent progenitors. Blood 1999; 94: 2343–56.

Table 1 **Clinical features of the patients.**

	Case 1	Case 2
Age (yr) / Sex	69/male	86/male
Primary tumor	skin/back	skin/forehead
Clinical stage (onset)	I AE	I AE
Disease progression (month)	bone marrow (2M) leukemic (8M)	multiple skin tumor (1M)
Morphology (section)	lymphoblastoid	lymphoblastoid
(smear)	plasmacytoid	
(TdT)	(+)	(+)
Karyotype	46,XY,add(5)(q11),add(5)(q31) ,t(6;8)(p21,q24),del(13)(q12q14) ,add(15)(q13)	failed
Southern: TCR/Cb	germ line	germ line
TCR/Jg	germ line	germ line
TCR/Jd1	germ line	germ line
Ig/JH	germ line	germ line
c-myc	germ line	germ line
EBV/DNA	negative	negative
Treatment (period/effect)	local irradiation (onset-1M/CR) THP-COP (2M - 7M/CR) DVP (8M-10M, RST)	oral CPA (onset-1M/PR) oral Etp (2M-3M/PR) multi local irradiation (4M/?)
Survival/cause of death	10M/septic shock	4M/cerebral infarction

CPA, cyclophosphamide; Etp, etoposide; THP-COP, pirarubicin + CPA + vincristine + prednisolone; DVP, daunomycin + vincristine + prednisolone. CR, PR, RST and ?, complete remission, partial remission, resistant, and died before valuation, respectively.

Table 2 Phenotype of the lymphoblasts.

			FCM						
	Case 1 *Tumor*	Case 2 *Tumor*		Case 1 *BM*	Case 2 *Tumor*		Case 1 *BM*		Case 1 *BM*
LCA (CD45)	**(+)**	**(+)**	CD2	(-)	(-)	CD1a	(-)	GPA	(-)
UCHL1 (CD45R0)	(-)	(-)	CD3	(-)	(-)	CD7	(-)	FMC7	(-)
anti-CD1a	(-)	(-)	CD4	**91.0**	(-)	CD13	(-)	AC133	(-)
Leu4 (CD3)	(-)	(-)	CD5	(-)	(-)	CD14	(-)	97A6	(-)
Leu19 (CD56)	(-)	(-)	CD8	(-)	(-)	CD15	(-)	NKp44	(-)
Leu7 (CD57)	(-)	(-)	CD10	**90.8**	**68.7**	CD16	(-)	NKp46	(-)
Ki-1 (CD30)	(-)	(-)	CD11b	(-)	12.2	CD21	(-)	**FCM-Cyto**	
KP-1 (CD68)	(-)	(-)	CD19	(-)	(-)	CD22	(-)	MPO	(-)
MT1 (CD43)	**(+)**	**(+)**	CD20	(-)	(-)	CD24	(-)	cCD3	(-)
MB1 (CD79a)	(-)	(-)	CD23	(-)	(-)	CD27	(-)	cCD22	(-)
LN1 (CD75)	(-)	(-)	CD25	(-)	(-)	CD36	89.9	Perforin	(-)
LN2 (CD74)	**(+)**	**(+)**	CD33	(-)	(-)	CD40	(-)	**FCM**	Case 1 *PB*
CS1-4 (LMP)	(-)	(-)	CD34	(-)	(-)	CD41	(-)		
TdT	**(+)**	**(+)**	CD38	(-)	34.4	CD45	95.7	CD1a	(-)
Granzyme B	n.d.	(-)	CD56	(-)	(-)	CD54	76.4	CD54	56.6
Perforin	(-)	(-)	CD122	(-)	(-)	CD57	(-)	CD58	48.9
bcl-2	**(+)**	n.d.	TCRa/b	(-)	(-)	CD70	(-)	CD80	(-)
S100	(-)	n.d.	TCRg/d	(-)	(-)	CD117	(-)	CD83	(-)
Fascin	(-)	(-)	HLA-DR	**99.0**	**74.4**	CD154	(-)	CD86	86.5

Phenotype analysis by Immunohistochemistry (Histochem) and flow cytometry (FCM). Tumor, primary skin tumor; BM, bone marrow infiltration; PB, leukemic transformation. FCM-Cyto, cytoplasmic expression; GPA, glycophorin A; MPO, myeloperoxidase.

Table 3. Comparison of the lymphoma cells with the plasmacytoid dendritic cell development from common lymphoid progenitors.

Phenotype	LCP	Case 2	Case 1	pre-pDC	pCC	pDC-CLL	pDC
CD34	+	-	-	-	-	-	
CD10	+	+	+			-	
CD36			+	+	+		+
CD4		-	+	+	+	+	
CD123				+		+	
HLA-DR		+	+	+	+	+	+
CD1a	-	-	-	-	-	-	+
CD40			-		+	-/+	+
CD54			+	+	+		+
CD58			+		-		+
CD80			-		-	-	+
CD83	-		-	-		-/+	+
CD86			+	-	-	-/+	+

LPC, lymphoid common progenitor; pre-pDC, plasmacytoid DC (pDC) precursor; pCC, plasmacytoid cell; pDC, pDC-chronic lymphocytic leukemia.

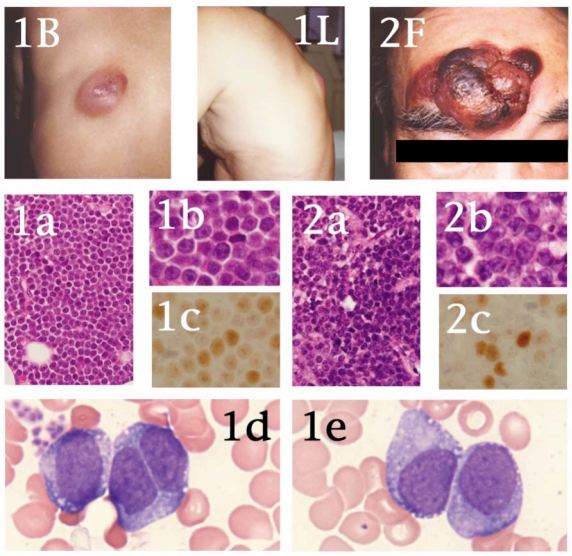

Figure 1. The skin tumors, histology and morphology.
Skin tumors: Elevated reddish skin tumors were observed on the left back (1B & 1L, case 1) and forehead (2F, case 2) of the patients. Back view (1B) and lateral view (1L) of case 1, and frontal view (2F) of case 2 are shown. *Histology:* 1a and 2a, HE stain (x400); 1b and 2b, HE stain (x1,000); 1c and 2c, TdT (horseradish peroxidase, x1,000) of the cases 1 (1a, 1b and 1c) and 2 (2a, 2b and 2c). There are small to medium sized lymphoid cells with scanty cytoplasm and clearly visible nucleoli. Some of the nuclei are convoluted. *Morphology:* Blast cells in the bone marrow are shown (1d & 1e, case 1, May-Giemsa stain, x1,000, March, 2000). The pathological cells had immature plasmacytoid feature.

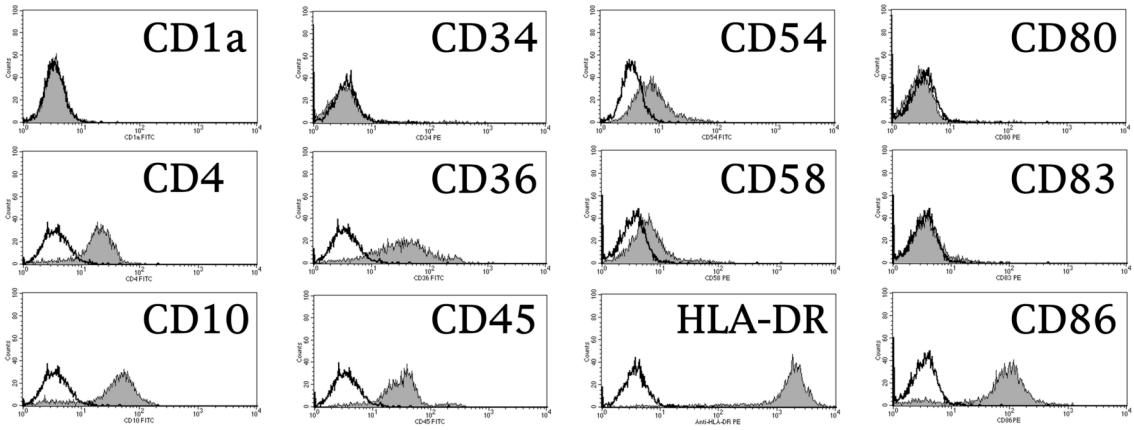

Figure 2. The phenotype of the pathological cells in case 1.
The bone marrow cells (CD4, CD10, CD34, CD36, CD45 and HLA-DR: March, 2000) and peripheral blood cells (CD1a, CD54, CD58, CD80, CD83, CD86: September, 2000) were stained by FITC- or PE-conjugated antibodies, and the lymphoblasts were analyzed using a gate on a FSC/SSC dot plotgram.

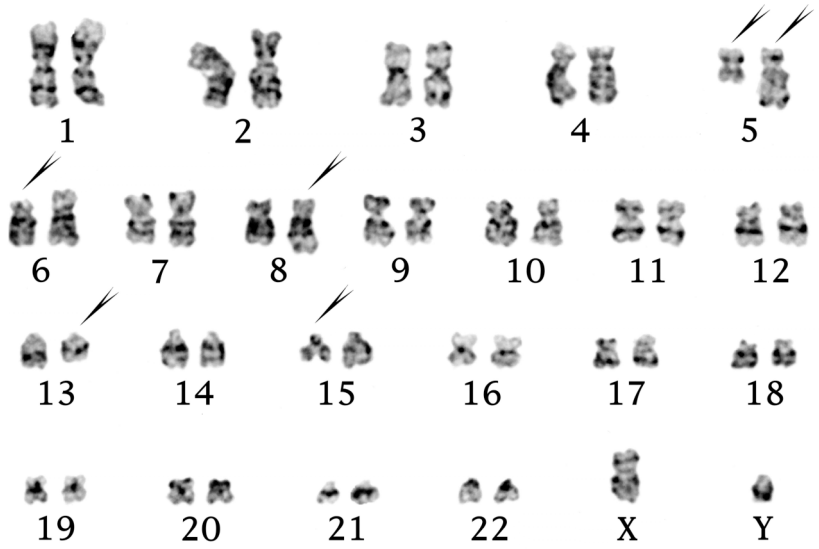

Figure 3. Karyotype of bone marrow cells in case 1.
Chromosome analysis of case 1 (bone marrow, March, 2000) showing 46, XY, add(5)(q11), add(5)(q31), t(6;8)(p21;q24), del(13)(q12;q14), add(15)(q13). The arrowheads indicate abnormal chromosomes.

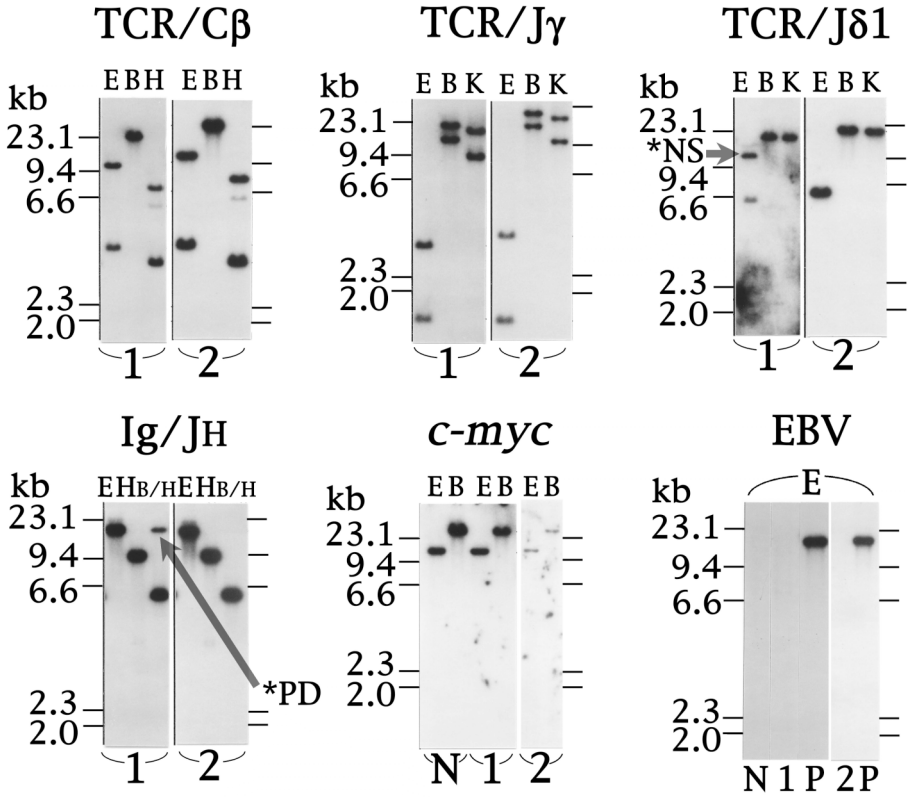

Figure 4. Southern blot analysis for JH, TCR/Cβ, TCR/Jγ, TCR/Jδ1, *c-myc* and TR-region of Epstein-Barr virus.

E, B, H and K, digestion using *Eco* RI, *Bam* HI, *Hind* III and *Kpn* I, respectively. B/H, digestion using *Bam* HI and *Hind* III. *NS, nonspecific band. *PD, partial digestion band. Lanes 1, 2, N and P, cases 1, 2, normal control and positive control (Raji cell), respectively. No rearranged bands were observed for JH, TCR/Cβ, TCR/Jγ, TCR/Jδ1 and *c-myc* in both cases. No EBV-DNA were detected in both cases.