

Spinal Cord Monitoring in Spinal Surgery: Two Demonstrative Cases

Olga A. BELOVA^{1,3}, Seiji UCHIYAMA¹, Yoichi YAJIRI¹, Hideaki E. TAKAHASHI¹ and Koki SHIMOJI²

¹Department of Orthopedic Surgery, ²Department of Anesthesiology, Niigata University School of Medicine, Niigata, Japan,
³Department of Traumatology and Orthopedic Surgery, Krasnoyarsk Medical Academy, Krasnoyarsk, Russia

Received December 5 1998; accepted March 8 1999

Summary: Two demonstrative cases are presented showing the usefulness of spinal cord monitoring during spinal surgery. Case One was a patient with severe spinal deformity due to neurofibromatosis. In corrective surgery, inadvertent spinal cord compression by sublaminar wiring was detected by the sudden disappearance of spinal cord evoked potentials (SCPs). Prompt removal of the wire prevented serious spinal cord injury. Case Two had a meningioma of the thoracic spinal cord. During surgery, low SCPs increased in amplitude immediately after removal of the tumor. The findings in these two cases suggest that monitoring of SCPs during spinal surgery not only prevents complications caused by mechanical manipulations but also promotes a favorable postoperative neurological recovery.

Key words—spinal cord monitoring, scoliosis, spinal cord tumor, evoked potentials.

INTRODUCTION

Spinal cord monitoring using spinal cord evoked potentials (SCPs) is now widely used in a variety of spinal surgery to minimize intraoperative neurologic morbidity^{1,2}. In Japan, conductive spinal cord evoked potentials, elicited by epidural stimulation and recorded in the epidural space, are most popular³. In the past, most of the monitoring was for patients with a normal spinal cord function such as scoliosis, but recently cases with severe neurological symptoms

have increased. In this report, we present two cases in which spinal cord monitoring provided useful information regarding spinal cord function during surgery.

METHODS OF SPINAL CORD MONITORING

The principle technique has been described and reviewed previously^{2,4}. Catheter type electrodes, UKG-100-3PMCN (Unique Medical, Tokyo), with a diameter of 1.0 mm, were placed in the epidural space of the spine above and below the area to be operated. Stimulation was made through the caudal electrode and recording was done through the cranial one, so that the ascending SCPs were monitored (Fig. 1). The equipment used in Case One was Neuropack Four (Nihonkoden, Tokyo), with Neuropack Σ (Nihonkoden, Tokyo) in Case Two.

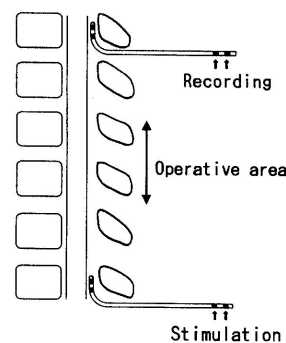


Fig. 1 Method of spinal cord monitoring.

Correspondence: Seiji Uchiyama, M.D., Department of Orthopedic Surgery, Niigata University School of Medicine, Asahimachidori 1, Niigata 951-8510, Japan

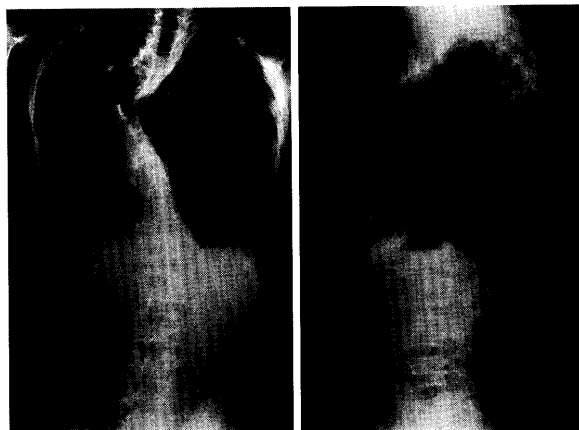


Fig. 2 Case One. Twelve-year-old boy with neurofibromatosis.

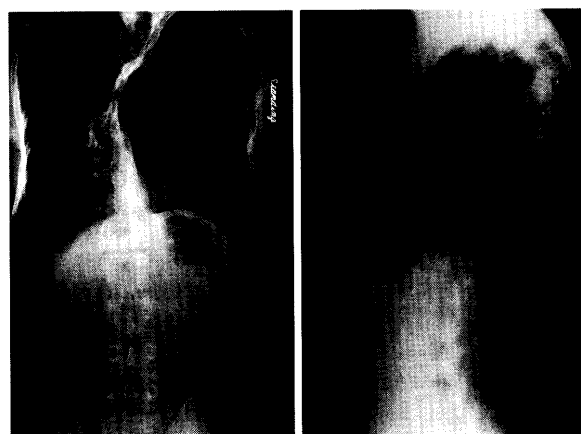


Fig. 4. Case One. Eight years after anterior vascularized fibular graft. Prompt removal of the wire prevented serious spinal cord injury.

CASES

Case one

A 12-year-old boy with neurofibromatosis presented 71 degrees of scoliosis and 75 degrees of kyphosis (Fig. 2). Posterior spinal fixation with Luque instrumentation was attempted. When a wire was passed under the lamina of T5, SCPs disappeared suddenly (Fig. 3). Immediately the sublaminar wire was removed, and we performed T5 laminectomy and finished the operation. However SCPs did not show any recovery in the operation. The patient was paraparetic just after the operation. He showed recovery thereafter, and was able to stand up six weeks after the operation. An anterior vascularized fibula graft

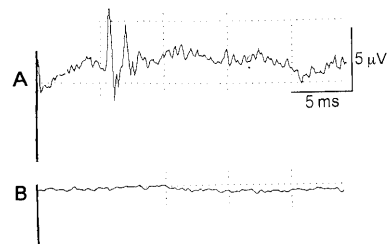


Fig. 3 SCPs in Case One. Stimulation at cauda equina and recording at T4. Both electrodes were placed in the epidural space. **A:** Control, **B:** After sublaminar wiring of T5. The wire was removed promptly after the disappearance of SCPs.

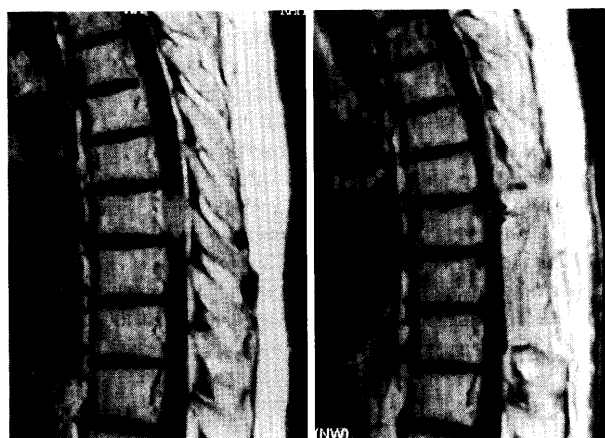


Fig. 5. Case Two. Sixty-year-old female. Meningioma at T9. Pre (*right*) and postoperative (*left*) MRI.

was done two months after the first operation. The patient is now 18 years old and has had good orthopedic results with no neurological deficits (Fig. 4). In this case, spinal cord monitoring revealed spinal cord injury caused by sublaminar wiring. This prompted the immediate removal of the wire, and as a result serious spinal cord damage was prevented.

Case two

A 60-year-old female presented a meningioma at the level of T 9th vertebra (Fig. 5). She had severe preoperative paralysis of her lower limbs with bladder incontinence. Surgery was performed to remove the tumor, and as with Case One, spinal cord monitoring was performed. At the beginning of operation the

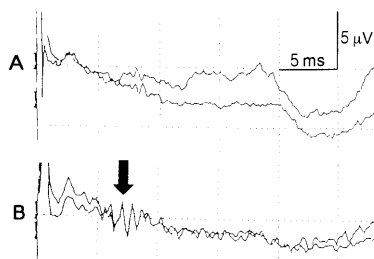


Fig. 6 SCPs in Case Two.
Stimulation at L1, recording at T1 in the epidural space.
A. Control, **B.** Increased amplitude after removal of the tumor.

amplitude of SCPs was very low. During the operation, the tumor was completely removed, and the SCPs then improved dramatically (Fig. 6). The next day, her motor functions showed signs of recovery, and she started walking with aids after four weeks. A postoperative MRI showed complete removal of the tumor (Fig. 5). In this case, spinal cord monitoring indicated the postoperative functional recovery of the spinal cord.

DISCUSSION

Conductive spinal cord evoked potentials (SCPs), one of the electrophysiological forms of spinal cord monitoring, was used in both cases. In this method, ascending or descending conduction of the spinal cord is monitored through electrodes above and below the area of operation. Electrodes for stimulation and for recording are placed in the epidural or subarachnoid space. High stable potentials are obtained unless preoperative spinal cord lesions exist. Shimoji and his associates established this method by using a technique of continuous epidural block⁴⁾, the method employed most often in Japan³⁾. In patients with normal spinal function, spike component amplitude changes of 50% or more are thought to signify severe neurological damage to the spinal cord. In Case One, spinal cord monitoring was quite useful to detect damage to the spinal cord. We were able to stop the procedure, and reoperate after functional recovery of the lower extremities. In Case Two, conductive SCPs indicated motor functional recovery.

Two other electrophysiological methods of spinal cord monitoring are currently available. The first of these is cortical somatosensory evoked potentials, where responses of peripheral nerve stimulations are

recorded on the scalp⁵⁾. Disc electrodes or subcutaneous needles are used for both stimulation and recording. This method is easier and less invasive, but the potentials are smaller and influenced by anesthetic agents more than the SCPs. The other method is motor evoked potentials in which the motor cortex of the brain is stimulated electrically or magnetically, and recording is done along the spinal cord or on the muscles^{6,7)}. These techniques were developed to monitor motor functions, but further studies on their safety and reliability are necessary⁸⁾.

A non-electrophysiological method, the wake-up test, is also used for monitoring. After a surgical procedure on the spinal cord, the anesthetist interrupts the anesthesia and awakens the patient to check the motion of the lower extremities⁹⁾. This method represents direct monitoring, but it is time consuming and unable to be performed frequently.

The above methods are employed solely or in combination, with some modifications, to detect more detailed information on events occurring in the spinal cord. The basic features, advantages and limitations of spinal cord monitoring, including false positive and negative changes, should be well established.

CONCLUSIONS

Spinal cord monitoring using spinal cord evoked potentials detects damage to the spinal cord during surgery. In some cases it may be a good predictor of the recovery of spinal cord function after surgical intervention. Monitoring of the spinal cord is very useful for surgeries of spinal disorders.

REFERENCES

- 1) Baba H, Kawahara N: Spinal cord evoked potential monitoring in orthopaedic spinal surgery. In: Dimitrijevic MR, Halter JA (eds) *Atlas of human spinal cord evoked potentials*. Butterworth-Heinemann, Boston 1995, p 123-131.
- 2) Fujioka H, Shimoji K, Tomita S, Denda S, Takada T, Homma T, Uchiyama S, Takahashi H, Tobita T, Baba H: Spinal cord potential recordings from the extradural space during scoliosis surgery. *Br J Anaesth* **73**: 350-356, 1994.
- 3) Tamaki T: Present status of intra-operative spinal cord monitoring in Japan. *J Jpn Scoliosis Soc* **6**: 5-9, 1991.
- 4) Shimoji K, Higashi H, Kano T: Epidural recording of

- spinal electrogram in man. *Electroencephal Clin Neurophysiol* **30**: 236-239, 1971.
- 5) Brown RH, Nash CL, Berilla JA, Amadio MD: Cortical evoked potential monitoring- a system for intraoperative monitoring of spinal cord function. *Spine* **9**: 256-261, 1984.
 - 6) Levy WJ, York DH, McCaffrey M, Tanzer F: Motor evoked potentials from transcranial stimulation of the motor cortex in humans. *Neurosurgery* **15**: 287-302, 1984.
 - 7) Dvorák J, Herdmann J, Theiler R, Grob D: Magnetic stimulation of motor cortex and motor roots for painless evaluation of central and proximal peripheral motor pathways-normal values and clinical application in disorders of the lumbar spine. *Spine* **16**: 955-961, 1991.
 - 8) Haller GS, Shulman BJ, Taylor PD: Spinal cord monitoring. In: Lonstein JE, Bradford DS, Winter RB, Oglivie JW (eds) *Moe's textbook of scoliosis and other spinal deformities*. (ed 3) WB Saunders, Philadelphia 1994, p 605-613.
 - 9) Vauzelle C, Stagnara P, Jouvinroux P: Functional monitoring of spinal cord activity during spinal surgery. *Clin Orthop* **93**: 173-178, 1973.