

A Case Report of Successful Conservative Management of Postoperative Massive Hemorrhage Based on AKBR after Living Related Liver Transplantation

Yoshinobu SATO, Satoshi YAMAMOTO, Jun NISHIMURA, Nobuyuki NABATAME, Kazuhiko TSUNODA, Toshifumi WAKAI, Takaoki WATANABE, Isao KUROSAKI, Yoshio SHIRAI, and Katsuyoshi HATAKEYAMA

The First Department of Surgery, Niigata University School of Medicine, Niigata, Japan

Received September 30 1999; accepted December 13 1999

Summary. We encountered an early postoperative intra-abdominal massive hemorrhage of above 500 ml/hour in a patient having undergone living related liver transplantation for subacute liver failure. Typically, re-exploration would be carried out; however, we successfully managed this patient using conservative procedures. The massive hemorrhage was initially accompanied by a decrease in arterial ketone bodies ratio (AKBR). However, the AKBR then increased rapidly due to blood transfusion. We therefore decided to wait before proceeding with more active measures, though renal function was aggravated by the bleeding, resulting in anuria. Then, although a second massive hemorrhage occurred, the AKBR did not decrease. Therefore we decided again to wait. Following this, diuretics were seen to gradually increase, and thereafter the intra-abdominal hemorrhage ceased rapidly with a surprising increase in urine volume. Renal function was rapidly restored. The decision to proceed with an urgent operation for postoperative massive hemorrhage in patients having undergone liver transplantation is problematic due to the complexity of the patient's situation and the trauma of the initial operation. In this case, the bleeding was considered to originate from the vena cava or cut margin of the graft. Therefore we thought that if the grafted liver's function was restored, clotting would be restored. The AKBR mirrored both the postoperative graft liver function during the hemorrhage and the graft function after therapy.

AKBR might play a useful role in the decision-making process regarding the re-exploration of postoperative hemorrhage and the procedures of the operation.

Key words—Liver transplantation, postoperative hemorrhage, AKBR, hepatorenal syndrome, reoperation.

INTRODUCTION

Immediate postoperative hemorrhage is a critical complication of liver surgery, seriously influencing liver function following surgery. In the event of such a hemorrhage, abdominal exploration must be seriously and carefully considered because the recipients of liver transplants are already compromised hosts and sometimes suffer from hepatorenal syndrome and hepatopulmonary syndrome as well as liver failure. We performed the successful conservative management of postoperative massive bleeding after living related liver transplantation (LRLT). There have been no reports about such a successful management of posttransplanted massive hemorrhage like ours without re-exploration. Arterial ketone body ratio (AKBR) is a very useful indicator for hepatic energy status and reflects the prognosis after liver surgery and liver transplantation^{1,2}. In this case, AKBR was very useful for determining the appropriateness of exploration due to postoperative massive hemorrhage after LRLT.

Correspondence: Yoshinobu Sato M. D., The First Department of Surgery, School of Medicine, Niigata University, 1-757 Asahimachidori, Niigata 951-8510, Japan.

CASE REPORT

A 42-year-old-man was admitted to the First Department of Surgery in our hospital for LRLT. He suffered from drug-induced subacute hepatic failure with remarkable hepatic atrophy, his abdominal CT volume demonstrating 389 ml and hepatic encephalopathy with flapping tremor. He had already been given 8 plasma exchanges and 3 bilirubin absorption and hemofiltration treatment; however, his clinical status remained serious. He was admitted to our hospital on March 18, 1999. His prothrombin time was 18% and AKBR was 0.26. Hepatic coma was grade II. Plasma exchange was done preoperatively. The LRLT was performed on March 20 using the right lobe of the liver of the patient's brother. His preoperative Graft volume/Standard volume (GV/SV) ratio was 68%. Actual GV/SV ratio was 63.5%. The operation took 12 h and 30 min. Operative blood loss was 10377 ml. AKBR increased to 0.78 immediately after LRLT. However a massive intra-abdominal hemorrhage of above 500 ml/h occurred 12 hours after LRLT. Hemoglobin of the fluid from

the abdominal drain was 5.7 g/dl to 7.5 g/dl. His AKBR decreased to 0.38, accompanied by massive bleeding. We considered whether laparotomy should be attempted; however, the patient's AKBR increased to 0.83 after a rapid transfusion.

We therefore decided to proceed conservatively by observing the patient's massive postoperative bleeding. However, the patient's urine output decreased while his serum creatinine and BUN increased gradually. After transplantation, oliguria was seen, which progressed to anuria accompanied by massive bleeding. After that, a second massive hemorrhage occurred, and we again considered reoperation. By this time the patient's serum creatinine had increased to 3.3 mg/dl and BUN increased to 83 mg/dl. At that time, his AKBR further rose to 1.26 and his urine output showed a slight increase. Therefore, we again decided to wait and observe. Following this his urine output increased remarkably. As the massive hemorrhage subsided and the AKBR returned to normal, diuresis increased surprisingly and serum creatinine and BUN levels decreased rapidly. Although GOT increased to 1000 IU/l, it recovered quickly. (Fig. 1) Though the patient experienced mild rejection in

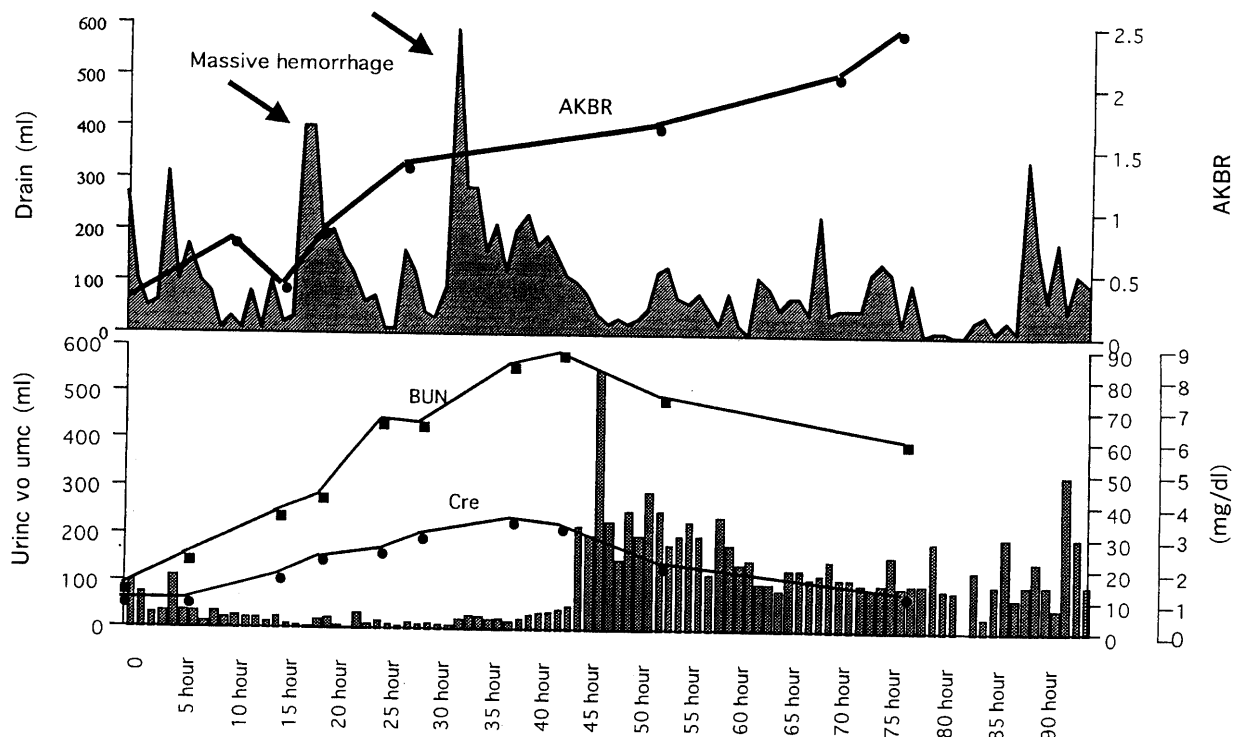


Fig. 1. Early postoperative course after living related liver transplantation. Upper graph indicates hemorrhagic volume per hour and AKBR. The black arrow demonstrates the two hemorrhagic episodes. Lower graph indicates urine output per hour and serum creatinine and BUN levels.

addition to the hemorrhagic episode, restitution was induced by steroid pulse therapy. He was discharged 54 days after the operation. (Fig. 2)

DISCUSSION

Postoperative abdominal hemorrhage is one of the most critical events that a liver surgeon can encounter. Reoperation for abdominal hemorrhage is usually undertaken within 24 to 48 h after the initial operation³. This is an integral part of the damage control sequence. In some patients, continued bleeding or elevated intra-abdominal pressure may require one or more urgent reoperations to arrest the hemorrhage or decompress the abdomen. Subsequent reoperations may be required to treat complications, notably intra-abdominal infection. Thus, a sharp distinction exists between a planned reoperation that is undertaken on a stable patient with a restored physiologic envelope (and a normal coagulation mechanism) and an unplanned (or urgent) reoperation on a grossly unstable patient who continues to bleed⁴. Postoperative hemorrhage must be regarded as a contingency option for the unplanned reoperation because liver transplant patients may already suffer from several unstable conditions such as coagulopathy, hepator-

enal syndrome, and hepato-pulmonary syndrome. Therefore the decision-making process and conduct of an unplanned reoperation differ strongly from the carefully thought-out sequence of a planned procedure.

The two indications for urgent reoperation are ongoing hemorrhage and increased intra-abdominal pressure. The one and only aim of an urgent operation is to save the patient's life by obtaining effective hemostasis or abdominal decompression. The mortality rate of urgent reoperation following a damage control operation is 70%, much higher than the mortality seen in patients who undergo reoperation after a definitive laparotomy⁵. Diagnosing an ongoing postoperative hemorrhage that requires urgent reoperation can be very difficult in the critically injured damage-control patient.

Elevated intra-abdominal pressure and the abdominal compartment syndrome have been discussed in detail^{6,7}. There are standard methods of intra-abdominal pressure monitoring, as well as a rapidly increasing awareness among surgeons that progressively increasing the intra-abdominal cavity is a relatively straightforward procedure once the problem is recognized because accepted criteria exist for this. With the occurrence of ongoing abdominal hemorrhage without significantly elevated pressure, the

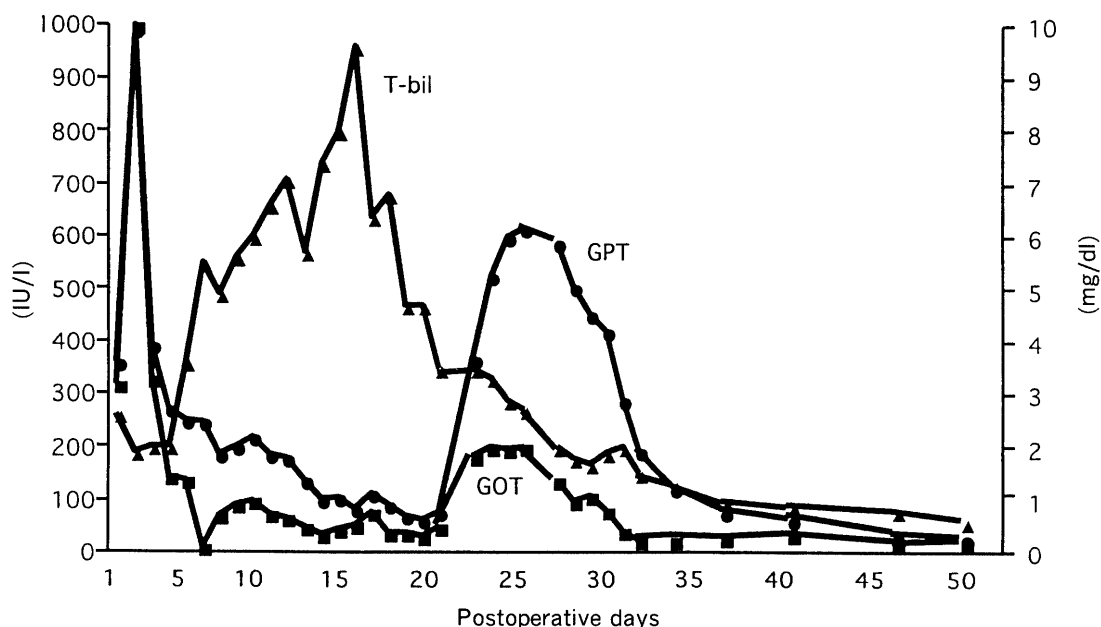


Fig. 2. Whole postoperative course after LRLT. The initial elevation of transaminases resulted from massive postoperative hemorrhage. The late elevation of transaminase and T. bilirubin resulted from mild rejection. T-bil, total bilirubin.

decision to reexplore the abdomen is much more difficult because there are not any firm quantitative guidelines. Our case might be included in this category. As a general rule, it is a safe course of action to consider urgent reoperation whenever the patient's estimated postoperative blood loss markedly exceeds the surgeon's expectations. Because this decision relies heavily on impressions gained during surgery, it should always be made by the surgeon who performed the primary procedure.

In the present case, when the massive hemorrhage started, we initially thought the bleeding originated in the short hepatic vein or cut margin of the liver graft. We twice encountered massive hemorrhage. Although the AKBR decreased with the onset of bleeding, after that it increased with the blood transfusion. The decrease of AKBR at the initial hemorrhage might have resulted from a diminution of the portal blood flow by the acute bleeding. Consequently the treatment providing copious supplies of blood can maintain the portal blood flow and might lead to recovery of hepatic energy status. Our case was one of subacute hepatic failure with severe coagulopathy. Therefore the recovery of the clotting could be attributed to the restoration of the grafted liver function. It was considered that, in this patient, the grafted liver function was restored gradually by the blood transfusion, then coagulation recovered, and subsequently the massive hemorrhage was rapidly arrested. After the blood transfusion, the AKBR continued to increase and then the activated coagulation time shortened from 180 sec to 120 sec. We therefore decided to continue waiting. It has been reported that the AKBR is an excellent prognostic indicator for patients undergoing liver transplantation or suffering acute hepatic failure^{1,2,8}. Ozawa reported that a decrease in the AKBR indicated graft dysfunction following liver transplantation^{1,2}. He also reported that the AKBR was a useful indicator of the severity of hemorrhagic shock and mentioned that re-exploration was not recommended when the AKBR was at low levels^{9,10}. When second massive hemorrhage occurred without a decrease in AKBR, re-exploration might be chosen. However, we decided to continued waiting because of the depression of the patient's renal function. If re-exploration had been made, a hemofiltration would have been required and postoperative management would have been more complicated. In fact, in our case, the AKBR was very useful for making the decision whether or not to operate. The surgeon must keep in mind that, after liver transplantation, the organ is swollen to twice or more its original size, has a tense capsule, and is very difficult to mobilize adequately. More importantly,

underneath the tense nonpliable capsule one encounters an extremely friable parenchyma. Any attempt to insert sutures or to arrest hemorrhage using tractotomy and direct ligation of the bleeders is doomed to fail because the hepatic parenchyma simply disintegrates and does not hold sutures, ties, or silver clips. The only effective solution is rapid re-packing¹¹. Failure to recognize the hostile engorged and friable liver is likely to result in continued bleeding and exsanguination. Other abdominal viscera are also distended, edematous, and inflamed, and even with a good control of gross spillage, some degree of contamination or early infection is always present. Patients who have undergone liver transplantation usually experience several complications as did ours¹². Postoperative management is complex. Therefore, the decision to proceed with re-exploration should be undertaken carefully. Consequently, the present patient did not suffer from an intra-abdominal infection and our decision proved to be correct. Nevertheless, the decision to reoperate should be made according to the conditions of each individual case.

REFERENCES

- 1) Yamaoka Y, Washida M, Manaka D, Gubernatis G, Ringe B, Ozaki N, Yamaguchi T, Takada Y, Ollerich M, Oh's K: Arterial ketone body ratio as a predictor of donor liver viability in human liver transplantation. *Transplantation* **55**: 92-95, 1993.
- 2) Asonuma K, Takaya S, Selby R, Okamoto R, Yamamoto Y, Yokoyama T, Todo S, Oh's K, Starzl TE: The clinical significance of the arterial ketone body ratio as an early indicator of graft viability in human liver transplantation. *Transplantation* **51**: 164-171, 1991.
- 3) Saibara T, Onishi S, Sone J, Yamamoto N, Shimahara Y, Mori K, Oh's K, Yamamoto Y: Arterial ketone body ratio as a possible indicator for liver transplantation in fulminant hepatic failure. *Transplantation* **51**: 782-786, 1991.
- 4) Oh's K, Ida T, Kamano T, Garbus J, Cowley RA: Different response of hepatic energy charge and adenine nucleotide concentrations to hemorrhagic shock. *Res Exp Med* **169**: 145-153, 1976.
- 5) Yamamoto M, Tanaka J, Oh's K, Tobe T: Significance of acetoacetate/-hydroxybutyrate ratio in arterial blood as an indicator of the severity of hemorrhagic shock. *J Surg Res* **28**: 124-131, 1980.
- 6) Kenneth WS, Richard JL: Abdominal packing for surgically uncontrollable hemorrhage. *Ann Surg* **215**: 467-475, 1992.

- 7) Hirshberg A, Wall MJ Jr, Ramchandani MK, Kenneth LM: Reoperation for bleeding in Trauma. *Arch Surg* **128**: 1163-1167, 1993.
- 8) Jon MB, Victor BO, Robert JR, Russell M, Kenneth LM, George LJ: Abbreviated laparotomy and planned reoperation for critically injured patients. *Ann Surg* **215**: 476-484, 1992.
- 9) Hirshberg A, Stein M, Adar R: Reoperation. Planned and unplanned. (Review) *Surg Clin Nor Amer* **77**: 897-907, 1997.
- 10) Rao RI, Lawrence D, John MP, Ronald S: Intra-abdominal hypertension and the abdominal compartment syndrome. (Review) *Surg Clin Nor Amer* **77**: 783-800, 1997.
- 11) Virginia E, Craig N, John AM Jr.: Abdominal compartment syndrome. *Surg Clin Nor Amer* **77**: 801-812, 1997.
- 12) Clavien PA, Camargo CA, Croxford R, Langer B, Levy GA, Greig PD: Definition and classification of negative outcomes in solid organ transplantation. Application in liver transplantation. *Ann Surg* **220**: 109-120, 1994.